

# Pancreatic Adenocarcinoma Presenting as Obstructive Jaundice in A Young Woman

*Evy Yuniastuti\**, *Julius R Samban\**, *H.M. Sjaifoellah Noer\*\*\**, *Daldiyono\*\**, *Unggul Budihusodo\*\*\**, *Rino A Gani\*\*\**, *Zubairi Djoerban\*\*\*\**

\*Department of Internal Medicine, Medical Faculty, University of Indonesia

\*\*Division of Gastroenterology, Department of Internal Medicine, Medical Faculty University of Indonesia

\*\*\* Division of Hepatology, Department of Internal Medicine, Medical Faculty, University of Indonesia

\*\*\*\*Division of Hematology and Medical Oncology, Department of Internal Medicine, Medical Faculty, University of Indonesia

## ABSTRACT

*Pancreatic carcinoma commonly occur in patients over 60 years. It is usually manifested as abdominal pain, jaundice, and pancreatic mass. In this report, a pancreatic carcinoma occurred in young woman is presented. A surgical drainage was done and followed by Whipple resection. However, the patient passed away three month after the diagnosis.*

**Key words:** *Pancreatic carcinoma, young woman, obstructive jaundice, whipple resection.*

## INTRODUCTION

Pancreatic cancer is the fourth leading cause of cancer death in the United States, killing about 21,000 people in that country each year. The importance of pancreatic cancer is further underlined by its extremely bleak prognosis. Regardless of therapy, median survival time is only about 3 months. The 1-year survival rate is only about 8% and the 5-year rate is about 0-2%.<sup>1-3</sup>

Incidence rates of pancreatic cancer increase with advancing age. Approximately 80% of deaths from pancreatic cancer occur between ages 60 and 80 years, and the disease is extremely rare below age 40. Incidence rates in US blacks are higher than in whites and over the last several decades have increased more in blacks than in whites.<sup>1-4</sup>

The cause of pancreatic cancer remains unknown. The most prominent of the risk factors and possibly the only one that has been firmly established, is cigarette smoking. The second most important risk factor appears to be diet. A high intake of fat and meat has been linked to the development of this neoplasm and protective effect is ascribed to a diet containing fresh fruits and vegetables. Occupational exposure to carcinogens (chemical, petroleum industries) may be associated with pancreatic cancer. Diabetes mellitus and chronic pancreatitis also predispose to pancreatic cancer.<sup>1,6</sup> Hereditary

causes of pancreatic cancer include hereditary pancreatitis, perhaps cystic fibrosis, and perhaps a form seen in southern Asia called tropical pancreatitis. In addition, there are familial forms of pancreatic cancer in which genetic defects are inherited, namely, in the p16 tumor suppressor gene (associated with familial melanoma), as well as in the BRCA2 gene. The latter gene has been associated with several forms of familial pancreatic cancer.<sup>6</sup>

Primary malignant epithelial neoplasm of the pancreas can occur in either the exocrine parenchyma or the endocrine cells of the islets of langerhans, but they are far more frequent in exocrine tissue. Ductal adenocarcinoma makes up between 75 and 92 percent of pancreatic neoplasms. In addition, it is twice as frequent in the head of the organ as in the body or tail. At the time of diagnosis, over 85 percent of tumors have extended beyond the organ.<sup>2-4</sup>

The signs and symptoms of pancreatic cancer are nonspecific. Pain, jaundice, or both are present in over 90 percent of patients and these features, in combination with weight loss, constitute the classic presentation of the disease.<sup>4</sup>

Pain is present either in the abdomen, the back, or both, in 35%, 8% and 36% of patients, respectively. The cause of pain, especially of the persistent type, is usually attributed to invasion of the perineural lym-

phatics of nerves in and around the pancreas.<sup>2,3</sup>

- Obstructive jaundice is nearly always associated with the carcinoma of the head of the pancreas. In 90% of those with jaundice, it is the invasion of the common bile duct that causes the obstruction.<sup>3</sup>
- Weight loss is almost universal in patients with pancreatic cancer. It is caused by malabsorption, decreased calorie consumption, or both.<sup>2</sup>
- Nonspecific signs and symptoms occur frequently, such as nausea, vomiting, weakness and anorexia. Rare findings include superficial thrombophlebitis, gastrointestinal bleeding, psychiatric disturbance and diabetes mellitus.<sup>2,3</sup>

Hepatomegaly and jaundice are present in more than 80% of patients with cancer of the head of the pancreas. Pruritus may be a prominent symptom and leads to persistent scratching, which produces excoriation and lichenification. Courvoisier sign (palpable gallbladder) and abdominal mass are present in 30% and 20%, respectively, of patients with carcinomas of the head of the pancreas.

In contrast, patients with cancer of the body and tail of the pancreas may have abdominal tenderness and pain, but hepatomegaly and jaundice are present in less than 30%. Abdominal mass and ascites occur in less than 20% of the patients.<sup>2,3</sup>

Diagnosis is most commonly based on imaging studies of the abdomen, either computed tomography (70-100%) or ultrasound (80-90%). There is little role for magnetic resonance imaging in pancreatic cancer (1-5%). ERCP may identify obstruction or encasement of pancreatic ducts, and cytology obtained may be diagnostic (20-40%).<sup>2,7,8</sup> Serologic marker CA 19-9 may be used to support the diagnosis.<sup>7,9</sup>

Treatment is based on disease stage. Usually patients are classified as resectable or unresectable. Only about 20% of diagnosed tumors are resectable.<sup>10</sup> Surgical procedure of choice for resection of tumors of the head of the pancreas is pancreatoduodenectomy—Whipple's procedure—or variations of this procedure.<sup>7,11-13</sup> Radiation therapy is often used with the goals of palliation, local control or perhaps prolongation of survival. In advanced cases, it may be used to relieve pain. Current treatment for resectable disease involves a multi-modality approach (i.e. surgery followed by adjuvant concurrent chemotherapy and radiation therapy). Treatment of locally advanced disease consists of external beam radiation and concurrent chemotherapy. For those patients with advanced disease, best supportive care is as important as

chemotherapy. 5-Fluorouracil (5-FU) and mitomycin C are usually the agents for palliative purpose.<sup>2,4-7</sup> Nowadays, gemcitabine is also used. Hopefully, angiogenesis-inhibitors and gene therapy, therapeutic frontiers of immunotherapy, will be able to extend the life span and improve quality of life of the pancreatic cancer patient.<sup>10</sup>

## CASE REPORT

A 26-years old woman was admitted to Cipto Mangunkusumo hospital because of jaundice.

The patient had been well until four months earlier, when abdominal pain and jaundice occurred. The pain was present in the epigastric region and radiated to the lumbar region. Her urine became dark and her stools became light. These complaints were accompanied by pruritus and weight loss. USG study in Serang hospital showed gallbladder stones. The patient was then suggested to undergo the operation, but she refused. The patient chose to try alternative medicine.

Fifteen days prior to admission, the patient had fever, severe abdominal pain, cough and shortness of breathing. She was hospitalized at Serang hospital and received blood transfusion because her hemoglobin level was 3.3 g/dL. There was history of melena.

A week prior to admission, the patient was re-hospitalized due to severe abdominal pain, jaundice, pruritus and fever. The patient was referred to Cipto Mangunkusumo hospital for ERCP.

The patient was a kindergarten teacher in the village. Her first son died of retinoblastoma ten month earlier. She did not smoke, but her husband was an active smoker.

Her temperature was 37 °C, her pulse rate was 96 times per minute and her respiration rate was 24 times per minute. Her blood pressure was 100/70 mmHg.

On physical examination, the patient was thin and jaundiced. Her conjunctivae were anemic, and her sclerae were icteric. Her lungs and heart were normal. Abdominal examination revealed audible bowel sounds; there were hepatomegaly, Courvoisier sign and slight epigastric pain; the spleen was not palpable and no abdominal masses were found. No lymphadenopathy was found. There was no edema of the leg.

Her hemoglobin level was 8.7 g/dL; leukocyte count was 15,500. Her urine was dark, with bilirubin +2 and urobilinogen +4.

Problems considered on admission were cholecystitis, obstructive jaundice and anemia. The patient was given Cefotaxime 3 X 1 g and a high calorie, low fat diet. Cholecystitis was based on epigastric pain that ra-

**Table 1. Hematologic laboratory values**

<b>Variable</b>	<b>On admission</b>	<b>Fourth hospital day</b>	<b>Tenth hospital day</b>
Hemoglobin (g/dL)	8.7	8.1	11.0
White-cell count (per mm <sup>3</sup> )	15,500	16,100	15,400
Differential count (%)		-/1/1/85/11/2	
Erythrocyte sedimentation rate (mm/hr)		115	
Hematocrit (%)	25	28	31.4
Platelet count (per mm <sup>3</sup> )	392,000	529,000	555,000
Erythrocyte count (per mm <sup>3</sup> )	3.3 million	3.51 million	
Reticulocyte (% $\circ$ )		8	
MCV		81	
MCH		23	
MCHC		29	
SI (ug/dL)		327	
TIBC (ug/dL)		368	
Ferritin (ng/mL)		41	
Bleeding time (sec)		4	
Clotting time (sec)		11	

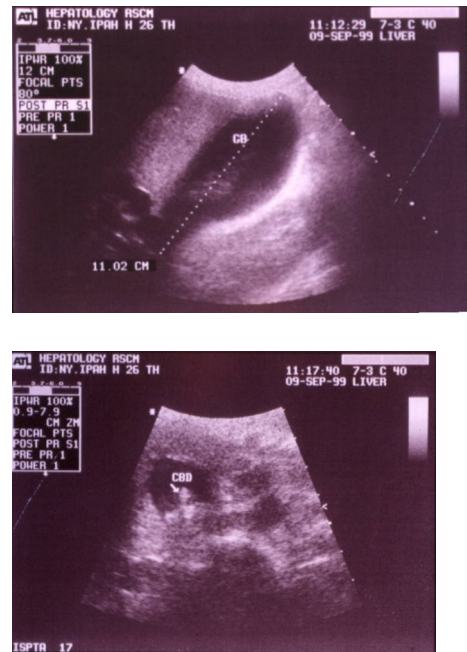
**Table 2. Blood chemical values**

<b>Variable</b>	<b>On admission</b>	<b>Fourth hospital day</b>	<b>Tenth hospital day</b>
Urea nitrogen (mg/dL)	27		
Creatinine (mg/dL)	0.6		
Protein, total (g/dL)		7.1	
Albumin (g/dL)		3.0	
Globulin (g/dL)		4.1	
Bilirubin, total (mg/dL)		27.4	
Bilirubin, direct (mg/dL)		14.5	
Bilirubin, indirect (mg/dL)		12.9	
Alanine aminotransferase (U/L)		124	
Aspartate aminotransferase (U/L)		51	
Phosphatase alkaline (U/L)		1717	
Gamma glutamil transferase (U/L)		364	
Sodium (mmol/L)			113
Potassium (mmol/L)			38
Glucose (mg/dL)	190	77	

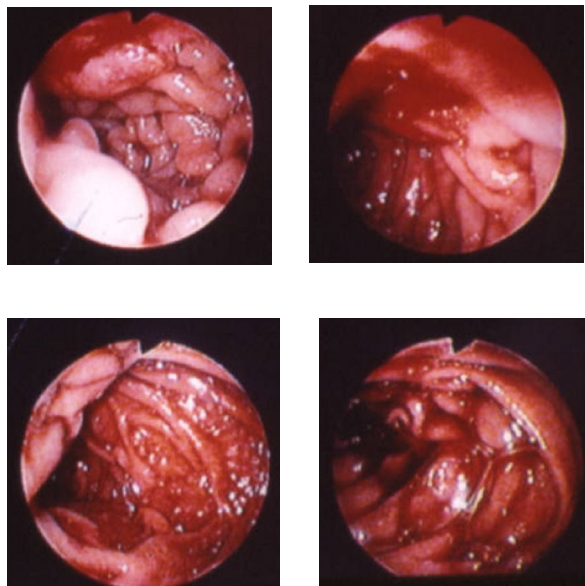
**Table 3. Urinary laboratory values**

	On admission	Fourth hospital day
	1.015	1.010
pH	7	7
Protein	Trace	-
Glucose	-	-
Acetone	-	-
Blood	-	-
Bilirubin	+2	+3
Urobilinogen	4	4
Bacteria	-	-
Epitel	+	+
Leukocyte/high power field	1-2	4-5
Erythrocyte/high power field	0-1	-
Cylinder	-	-
Crystal	-	-

diated to lumbar region, fever, jaundice and leukocytosis. Possible causes in mind were biliary stone or mass obstruction. Obstructive jaundice was considered based on the presence of jaundice, dark urine, light stools and



**Figure 1. An ultrasonographic study revealed enlargement of the gallbladder (vesica felea hydrops) and obstruction of the distal common bile duct**



**Figure 2. An esophagogastroduodenoscopy showed tumor of the papilla Vateri**

bilirubinuria. The patient was believed to have anemia due to chronic bleeding (melena), deficiency or anemia in chronic disease.

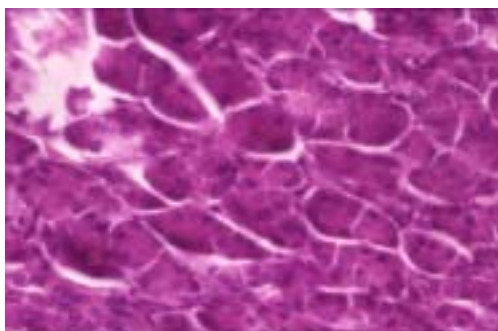
On the fourth day, the pain worsened, accompanied by fever and chills and increased leukocyte count. The patient was considered to have cholangitis and 2 x 60 mg of Gentamycin was added. Total bilirubin was 27.4 mg/dL, with direct and indirect bilirubin 14.5 and 12.9, respectively. Alanine aminotransferase was 124 U/L; aspartate aminotransferase was 51 U/L; phosphatase alkaline was 1717 U/L; gamma glutamil transferase was 364 U/L; and HBsAg was positive. Occult blood test turned out negative. An ultrasonographic study revealed enlargement of the left lobe of the liver, enlargement of the gallbladder (vesica felea hydrops) and obstruction of the distal common bile duct due to a certain mass (either stones or carcinoma of the pancreas).

An esophagogastroduodenoscopy showed tumor of the papilla Vateri. Pathologic exami-

nation showed well-differentiated adenocarcinoma of the pancreas.

On the tenth day, the patient underwent explorative laparotomy, cholecystectomy and T-tube insertion. There was tumor mass on the head of the pancreas. The patient was then admitted to the surgical ward.

Pathologic finding from the operation revealed adenocarcinoma with moderate to good differentiation. Some of tumor cells had differentiated into signet ring cell carcinoma. Immunoserologic measurement for CA 19-9 showed a more than two-fold increase (97.2 U/ZL; normal <37 U/L).



**Figure 3. Pathologic examination showed adenocarcinoma of the pancreas with moderate to good differentiation. Some of tumor cells had differentiated into signet ring cell.**

The patient underwent her second operation a month after the first operation. The Whipple procedure (pancreaticoduodenectomy) was performed. A mobile tumor was found at the head of the pancreas, 4x5 cm<sup>2</sup> in size. There was no lymphatic enlargement. The patient then went home in good condition.

Two month afterwards, the patient was readmitted to the hospital due to severe abdominal pain. CT scan and ultrasonographic study showed relapsing carcinoma of the head of the pancreas, ascites and paraaortic lymphatic enlargement. The tumor was unresectable, and the patient was treated in pain center with morphine.

The patient died a month afterwards at her home in Serang.

## DISCUSSION

Adenocarcinoma of the pancreas in a 26 year-old woman like this patient is a rare case, because the disease usually arises after the age of 45 with a sharp increase in occurrence thereafter.<sup>3,5</sup>

The possible risk factor for development of carcinoma of the pancreas in this patient cannot be determined. She lived in a village away from industries, had

neither a history of high intake of fat or excessive eating, pancreatitis, nor diabetes mellitus.<sup>1-6</sup> Even though she was a passive smoker, the risk for pancreatic cancer increases to excess risk levels of 10 to 15 years after smoking cessation.<sup>3</sup> But this patient had a history of carcinoma in her family. Genetic factors might also have played a role in this patient.

Clinical features of this patient were actually almost specific for carcinoma of the head of the pancreas. This patient showed weight loss, pain, jaundice, dark, urine, light stools, and pruritus. In a jaundiced patient without obvious acute cholecystitis, a palpable gallbladder also suggest a malignant tumor.<sup>14</sup> Liver function tests showed a total bilirubin value of 27.4 mg per 100 mL, and a pattern corresponding with obstructive jaundice.

The history of melena that caused anemia in this patient indicated gastrointestinal bleeding, which might be due to alternative medicine or a rare sign of pancreatic carcinoma.<sup>2</sup>

The diagnosis of carcinoma of the pancreas was made based on ultrasonographic, endoscopic, pathologic findings, and an increased level of CA 19-9.

The patient had undergone two surgeries. The first one was biliary stent placement to relieve jaundice and cholecystectomy. The first surgery could also be used to justify the stage of the tumor and for planning therapy. Demonstration of probable resectability would lead to consideration of chemotherapy and split-course radiation therapy to reduce intra-operative dissemination of the cancer and to increase chances for survival.<sup>7,15</sup> Resectability can be improved upon careful preoperative assessment using imaging techniques such as computed tomography, magnetic resonance imaging or endoscopic and laparoscopic ultrasonography. Thirty to forty percent of patients with potentially resectable cancer evaluated were found to have liver metastases and peritoneal spread unseen by conventional computed tomography or ultrasonography.<sup>13</sup>

The second surgery was elective Whipple pancreatoduodenectomy procedure for removing the carcinoma. This procedure is still considered as the gold standard for pancreatic carcinoma.<sup>2,12,13</sup>

Prognostic factors determining survival after surgery are the size of the tumor, grade, lymph node enlargement, and staging. It is unanimously accepted that in order to improve the chances of survival in patients with pancreatic carcinoma, radical surgical procedures should be extended to include lymphadenectomy. Postoperative adjuvant therapy could also be a determinant factor.<sup>13</sup> Unfortunately, this patient did not undergo radio-

therapy or chemotherapy.

The patient died five months after she was diagnosed with pancreatic cancer. This was longer than the median survival time reported (3 months).<sup>2</sup> Actually, at the time of diagnosis, over 85 percent of tumors have extended beyond the organ.<sup>2,4</sup> Even today pancreatic cancer should be considered as incurable, since even after radical surgery, the majority of the patients die from the consequences of the disease.<sup>13</sup>

## REFERENCES

1. Gold EB, Gordis L, Diener MD, Seltser R, Boitnott JK, Bynum TE, et al. Diet and other risk factors for cancer of the pancreas. *Cancer*. 1985; 55: 460-7.
2. DiMagno EP. Pancreatic adenocarcinoma. In: Yamada T, editor. *Textbook of gastroenterology*. 2<sup>nd</sup> ed. Philadelphia: JB Lippincott Company. 1995; p. 2113-31.
3. Cruickshank AH, Benbow EW. *Pathology of the pancreas*. 2<sup>nd</sup> ed. London: Springer; 1995.
4. Warshaw AL, Fernandez-del Castillo C. Pancreatic carcinoma. *N Engl J Med* 1992; 326: 455-65.
5. Lowelfels AB, Maisonneuve P, Cavallini G, Amman RW, Lankisch PG, Andersen JR, et al. Pancreatitis and the risk of pancreatic cancer. *N Engl J Med* 1993; 328: 1433-7.
6. Rutsgi A. Pancreatic cancer: epidemiology to molecular pathology. *Medscape. Digestive Disease Week 2000 Day 3 – May 23, 2000* [cited 2000 Oct 10]; [4 screens]. Available from: URL: [http://www.medscape.com/medscape/cno/2000/DDW/Story.cfm?story\\_id=1293](http://www.medscape.com/medscape/cno/2000/DDW/Story.cfm?story_id=1293).
7. Williams SR. Pancreatic Cancer. In: Djulbegovic B, Sullivan DM, editors. *Decision making in oncology, evidence-based management*. New York: Churchill Livingstone. 1997. p. 187-91.
8. Pulay I, Tihanyi TF, Flautner L. Pancreatic head mass: what can be done? Classification: the clinical point of view. *J Pancreas* 2000; 1: 85-90.
9. Pleskow DK, Berger HJ, Gyves J, Allen E, McLean A, Podolsky DK. Evaluation of a serologic marker, Ca 19-9, in the diagnosis of pancreatic cancer. *Ann Intern Med* 1989; 110: 704-9.
10. Rabitti PG, Germano D. Pancreatic head mass: How can we treat it? Tumor: conservative treatment. *J Pancreas* 2000; 1: 162-70.
11. Connolly MM, Dawson PJ, Michelassi F, Moossa AR, Lowenstein F. Survival in 1001 patients with carcinoma of the pancreas. *Ann Surg* 1987; 206: 336-70.
12. Crist DW, Sitzmann JV, Cameron JL. Improved hospital morbidity, mortality and survival after the Whipple procedure. *Ann Surg* 1987; 206: 358-65.
13. Tihanyi TF, Pulay I, Winternitz T, Flautner L. Pancreatic head mass: How can we treat it? Tumor: Surgical treatment. *J Pancreas* 2000; 1: 171-7.
14. Castleman C, Scully RE, McNeely BU. Case records of the Massachusetts General Hospital: case 25-1972. *N Engl J Med* 1972; 286: 1353-9.
15. Warshaw AL, Gu Z, Wittenberg J, Waltman AC. Preoperative staging and assessment of resectability of pancreatic cancer. *Arch Surg* 1990; 125: 230-3.