

A Case of Primary Ileocecal Lymphoma

Wulyo Rajabto*, Djumhana Atmakusuma*, Ivan Onggo S*, Dadang Makmun**

*Division of Hematology-medical Oncology, Department of Internal Medicine, Faculty of Medicine Universitas Indonesia/Dr. Cipto Mangunkusumo General Hospital, Jakarta

**Division of Gastroenterology, Department of Internal Medicine, Faculty of Medicine Universitas Indonesia/Dr. Cipto Mangunkusumo General Hospital, Jakarta

Corresponding author:

Wulyo Rajabto. Division of Hematology-medical Oncology, Department of Internal Medicine, Dr. Cipto Mangunkusumo General Hospital. Jl. Diponegoro No. 71 Jakarta Indonesia. Phone: +62-21-391830120; Facsimile: +62-21-3926286. E-mail: wulyo02@gmail.com

ABSTRACT

Primary lymphoma in gastrointestinal tract is not very common. Ileocecal region is the commonest site for primary lymphoma and diffuse large B cell lymphoma (DLBCL) is the most prevalent subtype. The clinical presentation in this condition is pain in right lower quadrant region and this can very confusing since many diseases can also cause this problem like infection and inflammatory disease. In this paper, we report a case of primary lymphoma subtype DLBCL in ileocecal region that come to emergency department with ileus obstruction. Abdominal computerized tomography (CT) scan and colonoscopy revealed tumour in ileocecal region ascendens colon. Hemicolectomy was performed and the specimen was sent to pathology which revealed non-Hodgkin lymphoma with subtype DLBCL CD20 (+). The patient had undergone of Rituximab, Cyclophosphamide, Doxorubicine, Vincristin, and Prednison (RCHOP) chemotherapy regimen and had complete remission.

Keywords: lymphoma, primary, ileocecal, RCHOP chemotherapy.

ABSTRAK

Limfoma primer di saluran cerna jarang ditemukan. Regio ileosekal merupakan lokasi limfoma primer yang sering terjadi dan diffuse large B cell lymphoma (DLBCL) adalah sub tipe limfoma non-Hodgkin yang paling sering terjadi pada regio ileosekal. Presentasi klinis DLBCL ileosekal tidak khas yaitu nyeri abdomen kuadran kanan bawah, yang bisa juga ditemukan pada penyakit-penyakit lainnya seperti infeksi dan penyakit-penyakit inflamasi saluran cerna. Kami melaporkan sebuah kasus DLBCL ileosekal yang datang ke unit gawat darurat dengan keluhan ileus obstruksi. Computerized tomography (CT) scan abdomen dan kolonoskopi menunjukkan tumor di kolon asenden ileosekal. Pasien menjalani operasi hemikolektomi dan hasil patologi anatomi menunjukkan limfoma non hodgkin jenis DLBCL CD 20 (+). Selanjutnya pasien menjalani program kemoterapi Rituximab, Cyclophosphamide, Doxorubicine, Vincristin, and Prednison (RCHOP) dan respon pasca kemoterapi RCHOP adalah remisi komplit.

Kata kunci: limfoma, primer, ileokal, terapi RCHOP

INTRODUCTION

Gastrointestinal tract is the most common place for extranodal metastasis by lymphoma that account 5-20% from all cases.¹ But primary gastrointestinal lymphoma, precisely small intestine is very rare that accounts about less than 2% of all gastrointestinal malignancies. From the small intestine lymphoma accounts 20-30% of all small intestine neoplasm, which ileocecal is the most common site (60-65%).² From primary intestinal Lymphoma B-cell Lymphoma is more frequent than T-Cell, with DLBCL is the most common subtype.

DLBCL ileocecal may have presenting symptoms such as abdominal pain, weight loss, ileus obstruction, or intussusception.^{3,4,5} There are many diseases affecting ileocecal region such as malignant tumour, inflammatory disease, infectious disease, and miscellaneous condition.⁶

RCHOP chemotherapy is the first line treatment of DLBCL and consists of Rituximab combination with Cyclophosphamide, Doxorubicine, Vincristin, and Prednison. The response rate of treatment of DLBCL with RCHOP is good.⁴

CASE ILLUSTRATION

A 61 year old male with chief complaint pain in right illiac fossa come to emergency department of three months duration with a sudden increase in severity of pain. The pain started in epigastric then radiating to right illiac fossa. He had history of weight loss 20 kg in 3 months, decrease appetite, no night sweat. Physical examination revealed abdominal bloating and mass in right lower quadrant region. His laboratory examination revealed normochromic normocytic anemia, leucocytosis with high level serum lactic dehydrogenase(915 U/L). CT scan of the abdomen (Figure 1) revealed calcified mass in the colon region cecum with peripancreatic and left paraaortic lymphadenopathy, while colonoscopy (Figure 2) revealed tumour in colon ileocecal region.

A right hemicolectomy was performed and the specimens of the tumour were sent to pathology. A histology diagnosis Non Hodgkin Lymphoma was made then immunohistochemistry result was positive for CD 20, CD 10, Ki-67 confirming the diagnosis of diffuse large B-cell lymphoma (DLBCL) with germinal center B-cell like subtype.

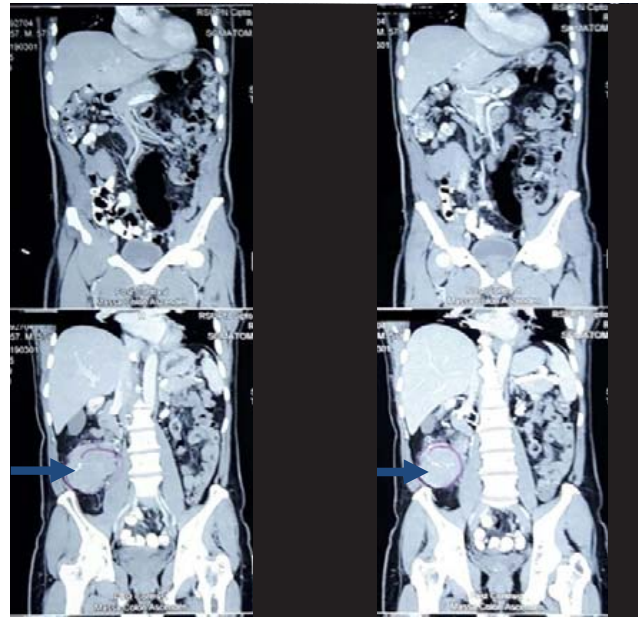


Figure 1. CT-scan result of the patient showed calcified mass in the colon region cecum with peripancreatic and left paraaortic lymphadenopathy

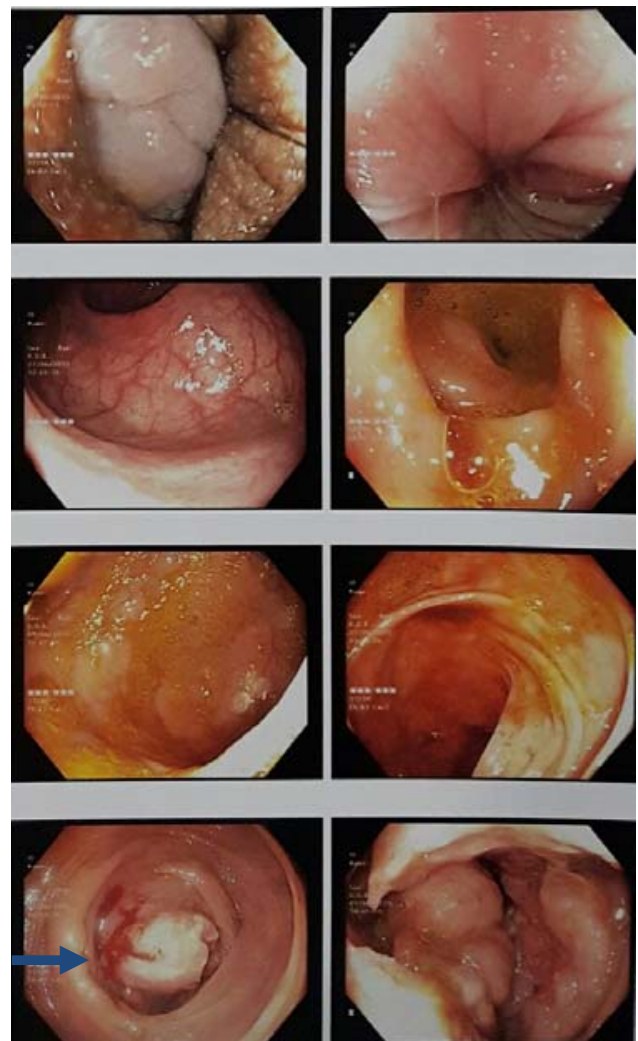


Figure 2. Colonoscopy result from the patient showing tumor in ileocecal region

The patient then undergone chemotherapy with R-CHOP regiment 8 cycles and now had complete remission. Figure 3 and 4 below showed the abdominal PET CT and CT scan in abdominal region after chemotherapy and 6 months following the last RCHOP chemotherapy.

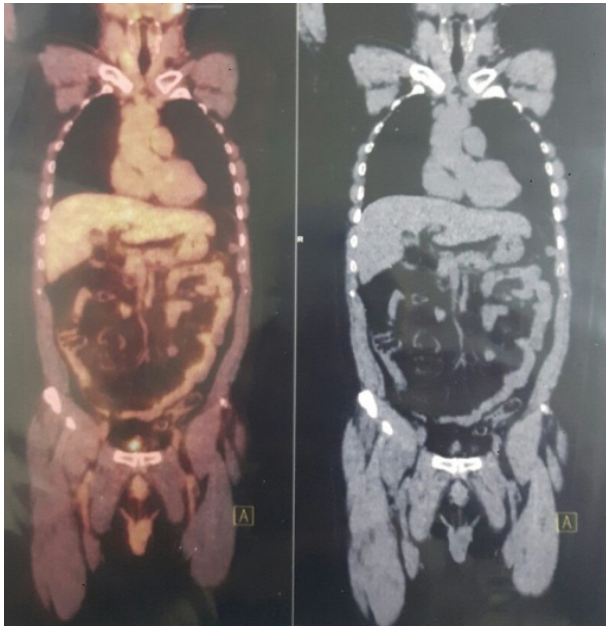


Figure 3. Abdominal PET SCAN post chemotherapy showed no tumour

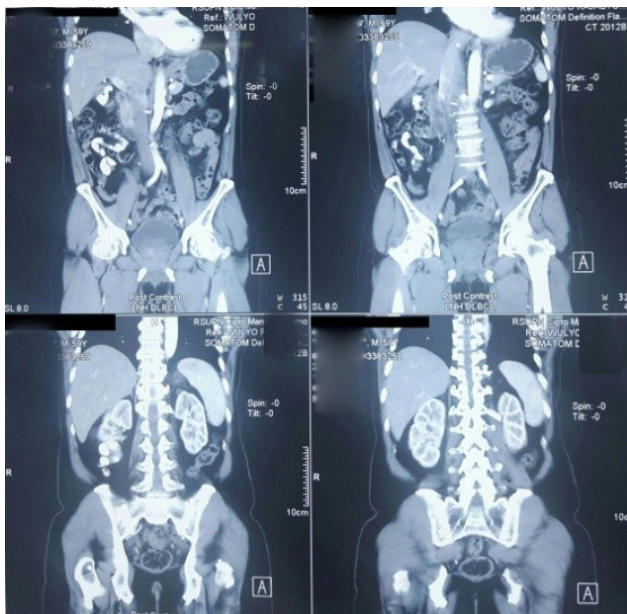


Figure 4. Abdominal CT-scan 6 months post chemotherapy showed no tumour

DISCUSSION

Lymphoma in small intestine usually have presenting symptoms such as abdominal pain, nausea, vomiting, weight loss, abdominal mass, obstructive symptoms, intussusception, perforation, and diarrhea with commonest pathological subtypes DLBCL.^{3,4,5}

Ileocecal region is relative short segment in gastrointestinal tract that have various component that close one to another. Because of this structure the diagnosis of pain in right illiac fossa must be made considering many condition such as malignant tumour, inflammatory disease, infectious disease, and miscellaneous condition.⁶ Table 1 below shown many condition that must be considered before made diagnostic related to pain in right illiac fossa.

Serum lactic dehydrogenase (LDH) is usually elevated at the time of the diagnosis of aggressive NHL. The high activity of LDH at the time of diagnosis reflects increased tumor bulk.⁷ Based on histology examination, DLBCL usually composed of intermediate large cells, which shows B-cell lineage with expression of pan B-cell antigens (CD 19, CD 20, CD 22, CD79A, and PAX5/BSAP) and is less commonly positive for germinal centre cell markers (CD 10 and BCL 6).⁸ We performed Computed Tomography (CT) scan to delineate the location of the tumor and it is now recommended as the gold standard for staging DBCL patients because more sensitivity for nodal and extranodal site.⁹

Tumor resection is the main treatment for primary gastrointestinal lymphoma because it also provide data to see the histology, staging, and extension for prognosis.¹⁰ In study by Kim SJ et al in DLBCL patient that had surgery have better overall survival than patient who did not.¹¹ While the recommended chemotherapy for DLBCL in patient 60-80 years old is R-CHOP (Rituximab, Cyclophosphamide, Doxorubicin, Vincristine, Prednisone) 8 cycles given every 21 days.¹² Complete response was achieved in 76% patients with R-CHOP regiment compared to CHOP with 63%, and disease progression were lower in R-CHOP regiment (9%) than in CHOP (22%) in study by Coffier et al.¹³

Primary Lymphoma that involved ileocecal region usually has better survival rates than in small and large

Table 1. Several condition that can cause right lower abdominal quadrant problem⁶

Malignant tumour	Inflammatory disease	Infectious disease	Miscellaneous tumour
Adenocarcinoma	Appendicitis	Tuberculosis	Thyphilitis (Neutropenic Colitis)
Carcinoid tumour	Diverticulitis	Infectious terminal ileitis	Ischemic condition
Lymphoma	Chron disease	Inflammatory reaction to an extrinsic infectious procces	Volvulus of cecum
Metastatic tumour	Ulcerative colitis		Ileocecal enteric duplication cyst
			Endometriosis

intestine.¹⁴ In this case hemicolectomy was done as the primary treatment, and then chemotherapy RCHOP definitely administered to the patient.

REFERENCES

1. Freeman C, Berg JW, Cutler SJ. Occurrence and prognosis of extranodal lymphomas. *Cancer* 1972;29:252-60.
2. Schottenfeld D, Beebe-Dimmer JL, Vigneau FD. The epidemiology and pathogenesis of neoplasia in the small intestine. *Ann Epidemiology* 2009;19:58-69.
3. Ghimire P, Wu GY, Zhu L. Primary gastrointestinal lymphoma. *World J Gastroenterol* 2011;17:697-707.
4. L Yin, Chen CQ, Peng CH, Chen GM, Zhou HJ, Han BS, et al. Primary small-bowel non-Hodgkin's Lymphomas: a study of clinical feature, pathology, management, and prognosis. *The Journal of International Medical Research* 2007;35:406-15.
5. William BM, Bongu NR, Bast M, Bociek RG, Bierman PJ, Vose JM, et al. The utility of Lactate Dehydrogenase in the follow up of patients with diffuse large B-Cell lymphoma. *Rev Bras Hematol Hemoter* 2013;35:189-91.
6. Hoeffel C, Crema MD, Belkacem A, Azizi L, Lewin M, Arrive L, et al. Multi-detector row CT: spectrum of diseases involving the ileocecal area. *Radiographics* 2006;26:1373-90.
7. Ferraris AM, Giuntini P, Gaetani GF. Serum lactic dehydrogenases a prognostic tool for non-Hodgkin lymphomas. *Blood* 1979;54:928-32.
8. López-Guillermo A, Colomo L, Jiménez M, Bosch F, Villamor N, Arenillas L, et al. Diffuse large B-cell lymphoma: clinical and biological characterization and outcome according to the nodal or extranodal primary origin. *J Clin Oncol* 2005;23:2797-804.
9. Barrington SF, Mikhaeel NG, Kostakoglu L, Meignan M, Hutchings M, Mueller SP, et al. Role of imaging in the staging and response assessment of lymphoma: consensus of the International Conference on Malignant Lymphomas Imaging Working Group. *J Clin Oncol* 2014;32:3048–58.
10. Gavrilidis P, Christoforidou B, Michalopoupou I, Nikolaidou A. Primary ileocecal B-cell non-Hodgkin lymphoma (NHL): a rare underlying cause of right iliac fossa pain. *BMJ Case Report* 2013;3:10.1136/bcr-2013-009052.
11. Kim SJ, Choi CW, Mun YC, Oh SY, Kang HJ, Lee SI, et al. Multicenter retrospective analysis of 581 patients with primary intestinal non-hodgkin lymphoma from the Consortium for improving survival of lymphoma (CISL). *BMC Cancer* 2011;11:321.
12. Tilly H, Gomes DSM, Vitolo U, Jack A, Meignan M, Lopez-Guillermo A, et al. Diffuse large B-cell lymphoma (DLBCL): ESMO clinical practice guidelines for diagnosis, treatment, and follow up. *Annals of Oncology* 2015;26:116-25.
13. Coiffier B, Lepage E, Briere J, Herbrecht R, Tilly H, Bouabdallah R, et al. CHOP chemotherapy plus Rituximab compared with CHOP alone in elderly patients with diffuse large-B-cell lymphoma. *N Engl J Med* 2002;346:235-42.
14. Koch P, del-Valle F, Berdel WE, Willich NA, Reers B, Hiddemann W, et al. Primary gastrointestinal non-Hodgkin's lymphoma: I. Anatomic and histologic distribution, clinical features, and survival data of 371 patients registered in the German Multicenter Study GIT NHL 01/92. *J Clin Oncol* 2001;19:3861-73.