

# Treatment Options of Lemmel's Syndrome: A Case of Benign Obstructive Jaundice in the Elderly

Abigail Prasetyaningtyas\*, Aru Wisaksono Sudoyo\*\*, Perdana Aditya Rahman\*

\*Department of Internal Medicine, Faculty of Medicine

University of Indonesia/Dr. Cipto Mangunkusumo General National Hospital, Jakarta

\*\*Division of Hematology and Medical Oncology, Department of Internal Medicine

Faculty of Medicine, University of Indonesia/Dr. Cipto Mangunkusumo General National Hospital, Jakarta

## Corresponding author:

Aru Wisaksono Sudoyo. Division of Hematology and Medical Oncology, Department of Internal Medicine, University of Indonesia/ Dr. Cipto Mangunkusumo General National Hospital. Jl. Diponegoro No. 71 Jakarta Indonesia. Phone: +62-21-3162497/3919680; Facsimile: +62-21-3926286. E-mail: arusudoyo@yahoo.com

## ABSTRACT

Lemmel's syndrome, also known as duodenal diverticulum obstructive jaundice, is a rare cause of benign obstructive jaundice that should be included in the differential diagnosis of biliary obstruction when PAD is present, in the absence of cholelithiasis or other detectable obstacle. Diagnosing Lemmel's syndrome could be challenging, but being aware of this condition is important to avoid mismanagement and it begins with identification of periampullary diverticula (PAD), while interpreting any bile duct imaging. It can be misinterpreted as periampullary tumors, biliary stones, or pancreatic pseudocyst. Symptomatic patients can be successfully managed endoscopically in many cases but surgical management would be necessary in selected cases.

We present a patient with benign obstructive jaundice caused by Lemmel's syndrome who was successfully treated with endoscopic sphincterectomy. A 67 years old female presented to the emergency department with chief complaint of jaundice. The patient was assessed to have obstructive jaundice cause by a duodenal mass, elevation of transaminase enzyme suspected caused by drug induced liver injury, hypertension (controlled), and anterior extensive coronary ischemia. Endoscopic retrograde cholangiopancreatografi (ERCP) showing multiple giant diverticle in second part of duodenum, stenosis of the distal common bile duct (CBD) with compression of diverticular extra luminal as a differential diagnosis. Endoscopic ultrasound (EUS) was performed to exclude a periampullary tumor, resulting distal CBD stenosis due to compression of multiple PAD. We performed an endoscopic sphincterectomy (EST) and the stent was removed. A further evaluation of the tuberculous lymphadenitis was planned as outpatient setting. One month follow-up, no recurrence of jaundice was observed.

**Keywords:** Lemmel's syndrome, obstructive, jaundice, endoscopic sphincterectomy

## ABSTRAK

Sindrom Lemmel, yang juga dikenal sebagai divertikulum duodenum ikterus obstruktif, merupakan penyebab yang jarang dari ikterus obstruktif jinak yang harus dipikirkan dalam diagnosis diferensial obstruksi bilier dengan divertikula periampulla, saat tidak ditemukannya cholelithiasis atau obstruksi lainnya. Mendiagnosis sindrom Lemmel merupakan suatu tantangan, tetapi menemukan kondisi ini penting untuk menghindari salah dalam penatalaksanaan pasien dan hal ini dimulai dengan identifikasi divertikula periampulla, ketika membaca setiap pencitraan saluran empedu. Divertikula periampulla seringkali salah diinterpretasi sebagai tumor periampulla, batu empedu, atau pseudokista pankreas. Pasien simptomatik dapat ditatalaksana dengan endoskopi dalam kebanyakan kasus, akan tetapi dalam kasus-kasus tertentu tetap diperlukan manajemen bedah.

*Dalam laporan kasus ini, kami melaporkan seorang pasien dengan ikterus obstruktif jinak yang disebabkan oleh sindrom Lemmel, yang berhasil diterapi dengan sphincterotomi endoskopi. Seorang wanita 67 tahun datang ke gawat darurat dengan keluhan utama ikterus. Pasien ini didiagnosa memiliki ikterus obstruktif yang disebabkan oleh massa duodenum, kenaikan enzim transaminase yang dicurigai disebabkan oleh kerusakan hati akibat obat, hipertensi (terkontrol), dan iskemia koroner anterior yang luas. Endoskopi retrograde cholangiopancreatografi (ERCP) menunjukkan divertikulum raksasa multipel pada bagian kedua dari duodenum, stenosis saluran empedu umum distal dengan kompresi divertikulum luminal tambahan sebagai diagnosis diferensial. Endoskopi ultrasonografi dilakukan untuk mengeksklusi tumor periampulla, yang menyebabkan stenosis distal CBD akibat kompresi dari beberapa divertikula periampulla. Sphinterektomi endoskopi dilakukan dan stent diangkat. Evaluasi lebih lanjut dari limfadenitis TB direncanakan dalam rawat jalan. Setelah satu bulan follow-up, tidak ada jaundice yang muncul kembali.*

**Kata kunci:** sindrom Lemmel, obstruktif, ikterus, sphinterektomi endoskopi

## INTRODUCTION

Lemmel's syndrome, also known as duodenal diverticulum obstructive jaundice syndrome was first described in 1934 by Lemmel, characterized by obstructive jaundice due to periampullary diverticula (PAD), in the absence of cholelithiasis or other detectable obstacle. Very few cases of Lemmel's syndrome have been published and fully investigated.<sup>1-3</sup> Duodenal diverticulum is a well known entity since the early eighteenth century when it was first reported by a French pathologist, Pierre Jean Baptiste Chomel, in 1710.<sup>4</sup> The duodenum is the second most common site of diverticula in the small bowel following the jejunum. It is difficult to ascertain the exact prevalence of duodenal diverticula; they are seen in 1-6% of upper gastrointestinal contrast studies, 12-27% of endoscopic studies and in 15-22% of autopsies.<sup>4,5</sup> Diverticula usually found in people above 40 and has a tendency to increase with age.<sup>5-9</sup> PAD occurred in up to 65% of elderly patients in some studies.<sup>10</sup>

Diverticula occur at locus minoris in the duodenal wall such as the site of entry of the common bile duct, pancreatic duct and perivascular connective tissue sheath. The etiology is not clear, it might be the end result of duodenal motility disorder, advancing age, progressive weakening of intestinal smooth muscles and increase of intraduodenal pressure may all encourage the outpouching of the duodenum.<sup>11</sup> About 70-75% of duodenal diverticula are periampullary. PAD were defined as extraluminal outpouchings of the duodenum adjacent to or containing the ampulla of Vater or intraluminal component of the common bile duct (CBD). Diverticula arising within 2-3 cm radius of the ampulla but not containing it are referred to as juxtaampullary diverticula (JPD). However, if the papilla arises within a diverticulum it is called an intradiverticular papilla (IDP).<sup>5,11</sup>

In the majority of cases, diverticula arise on the inner or pancreatic border of the duodenum. The possibility of PAD should be kept in mind while interpreting any bile duct imaging. It can create a filling defect in biliary passage; hence, can be mistaken for periampullary tumors or biliary stones. It can also be misinterpreted as pancreatic pseudocyst when it is large and fluid filled.<sup>11</sup> We report a case of an elderly patient with obstructive jaundice due to Lemmel's syndrome that was successfully managed endoscopically.

## CASE ILLUSTRATION

A 67 years old female presented to the emergency department with chief complaint of jaundice. Three weeks before admission, she noticed yellow-colored sclera and brown discoloration of urine. The patient also complained of nausea and decrease in appetite. Weight loss and fever was denied. Five weeks before admission, the patient was diagnosed with tuberculous lymphadenitis and was taking anti tuberculosis drugs (rifampicin, pyrazinamide, and isoniazid), and took the drugs for two weeks. She complained nausea and stopped consuming the drugs. She went to a hospital in Purwakarta then referred to Jakarta for further investigation. Abdominal computerized tomography (CT) performed with result of distal bile duct blockage. She was advised to undergo endoscopic retrograde cholangiopancreatografi (ERCP) at Cipto Mangunkusumo Hospital.

Her medical history included incomplete treatment of tuberculous lymphadenitis in 2006, hypertension since 2014 treated by hydrochlorothiazid. No history of malignancy and jaundice in the family. From the physical examination, patient with normal vital sign. The nutritional status obtained good impression with height 152 cm, and weight 55 kg. The patient's body mass index was 23 kg/m<sup>2</sup> (obese). We found she was

icteric with no tenderness in abdomen. Laboratory tests showed hemoglobin 12.4 g/dL, hematocrit 35.4%, leukocytes 6300/mm<sup>3</sup>, and platelets 171,000/mm<sup>3</sup>. There was an elevation of liver function test AST of 447 U/L and ALT of 204 U/L, total bilirubin of 12.92 mg/dL, direct bilirubin of 9.82 mg/dL and indirect bilirubin of 3.1 mg/dL, gama glutamyl traspeptidase of 57 mg/dL, alkaline phosphatase of 137 mg/dL, and non-reactive for HBsAg, anti-HCV and IgM anti HAV.

ECG examination showed sinus rhythm, QRS rate of 62 times per minute, normoaksis, PR interval 0.12 seconds, QRS interval 0.8 seconds, no changes in the ST waveform, T inversion in I, AVL, V1-V6, and no hypertrophy. The X-ray examination in 22 January 2015 revealed aorta calcification elongation and no abnormalities of the lungs. Abdominal CT scan with contrast in 13 January 2015 show thickening wall of the pylorus (1.28 cm) and duodenal wall at second part and third part (approximately: 2.32 cm) suspected was an intraluminal mass, widening CBD (13.6 mm) and pancreatic duct (2,8mm); simple cyst in the upper pole of the right kidney (8 mm), multiple cysts in the lower pole of the left kidney (the largest size of 1.44 cm), and aortic calcification (Figure 2).

The patient was assessed to have obstructive jaundice cause by a duodenal mass, elevation of transaminase enzyme supected caused by drug induced liver injury, hypertension (controlled), and anterior extensive coronary ischemia. Prophylactic cefoperazone sulbactam 2 gram per day was administered for prevention of cholangitis, total bilirubin decreased to 6,89 mg/

dL. Endoscopic retrograde cholangiopancreatografi (ERCP) and CBD stenting performed. The ERCP showing mutiple giant diverticle in second part of duodenum, stenosis of the distal CBD with compression of diverticular extra luminal as a differential diagnosis (Figure 3). Endoscopic ultrasound (EUS) was performed to exlude a periampullary tumor, resulting distal CBD stenosis due to compression of multiple periampullary diverticula (PAD).

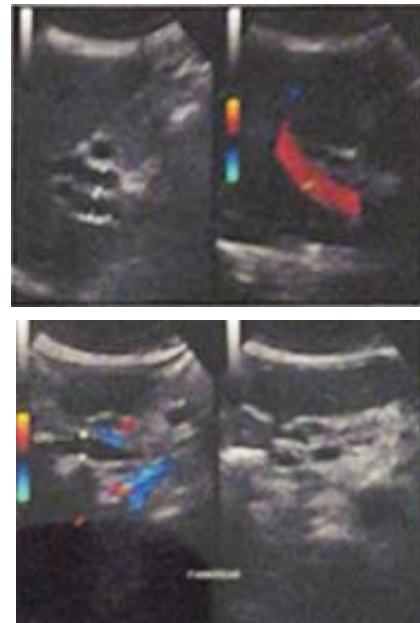


Figure 1. Abdominal ultrasound showed hepatomegaly, dilatation of intra and extra hepatic bile duct and the pancreatic duct which was suspected caused by an obstruction in the distal common bile duct (CBD) (due to mass with strictures as the differential diagnosis)

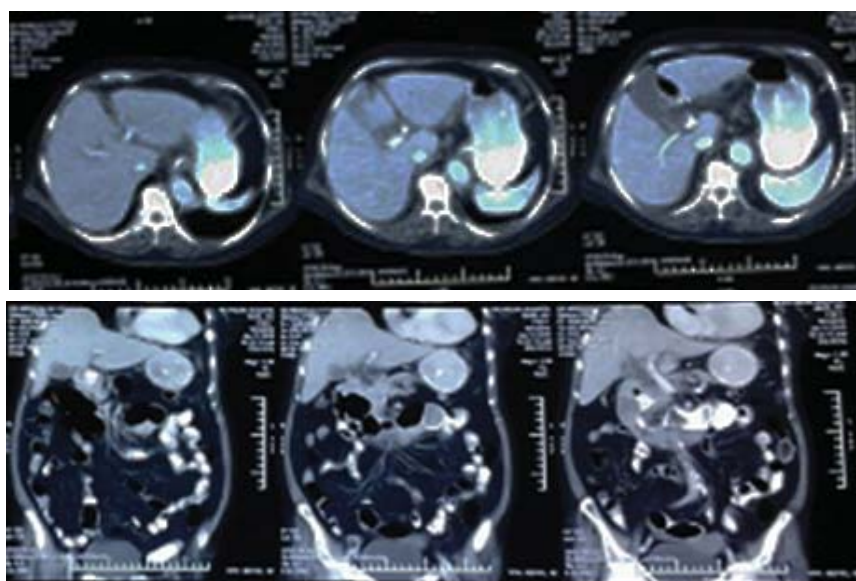
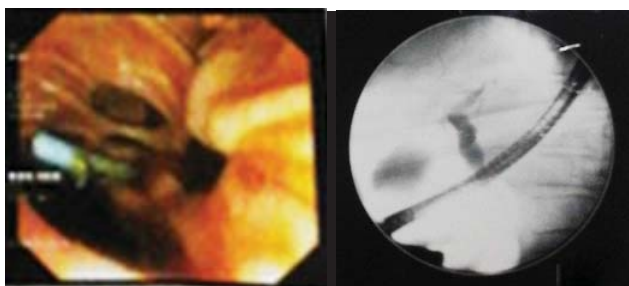
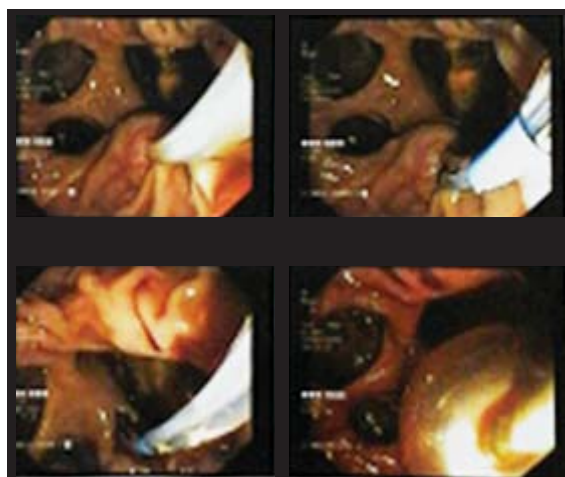


Figure 2. Abdominal CT scan showed thickening wall of the pylorus (1.28 cm) and duodenal wall at second part and third part (approximately: 2.32 cm) suspected was an intraluminal mass, widening CBD (13.6 mm) and pancreatic duct (2,8mm); simple cyst in the upper pole of the right kidney (8 mm), multiple cysts in the lower pole of the left kidney (the largest size of 1.44 cm), and aortic calcification



**Figure 3. ERCP showed perampullary diverticula and stenosis of the distal CBD**

We performed an endoscopic sphincterectomy (EST) and the stent was removed (Figure 4). Patient was discharged with bilirubin further decreased to 2,1 mg/dL. A further evaluation of the tuberculous lymphadenitis was planned as outpatient setting. One month follow-up, no recurrence of jaundice was observed.



**Figure 4. Endoscopic Sphincterectomy showed the stent was removed**

## DISCUSSION

Lemmel's syndrome is characterized by obstructive jaundice due to perampullary diverticula (PAD), in the absence of cholelithiasis or other detectable obstacle.<sup>1-3</sup> Most patients with Lemmel's syndrome present with jaundice, abdominal pain or acute cholangitis, mimicking perampullary tumors.<sup>2,12,13</sup>

Diverticula of the gastrointestinal tract are outpouchings of all or part of the intestinal wall which can occur anywhere throughout the gastrointestinal tract. The duodenum is second most common site of diverticula in the gastrointestinal tract after colon, followed by jejunum, ileum and stomach. Duodenal diverticula was first reported by the French pathologist, Pierre Jean Baptiste Chomel in 1710 and first well documented report was made by Morgagni in 1762 and

it was regarded an anatomic curiosity until 1913 when radiological demonstration was done by JT Case, who displayed roentgenograms of 4 cases.<sup>1,14,15</sup>

PAD were defined as extraluminal outpouchings of the duodenum adjacent to or containing the ampulla of Vater or intraluminal component of the CBD. Diverticula arising within 2-3 cm radius of the ampulla but not containing it are referred to as juxtapapillary diverticula (JPD). However, if the papilla arises within a diverticulum it is called an intradiverticular papilla (IDP).<sup>5,11</sup>

It is difficult to ascertain the true prevalence of duodenal diverticula; they are seen in 1-6% of upper gastrointestinal radiologic exam, 12-27% of endoscopic studies and in 15-22% of autopsies.<sup>5,13</sup> Duodenal diverticula are rare below age 40 years and has a tendency to increase with age.<sup>5-9,11</sup> They can be classified as either congenital or acquired and intraluminal or extraluminal. They typically occur in the perampullary region, along the medial aspect of the second and third part of the duodenum.<sup>16,17</sup> Incidence of Lemmel's syndrome seems higher in patients with intradiverticular papilla than in patients with a juxtapapillary diverticulum, possibly because of their larger size and closer relation to the ampulla.<sup>13</sup>

Among duodenal diverticula, PAD is the most common type comprising about 70% to 75% of all duodenal diverticula. Most PAD are asymptomatic but complications can occur in about 5% of cases and they include bleeding, perforation, diverticulitis, pancreatitis, choledocholithiasis, cholangitis, jaundice, enterolith or bezoar formation, intestinal obstruction, etc. Among these complications, hepatocholangiopancreatic disease seldomly occurs in the absence of choledocholithiasis and is termed Lemmel's syndrome.<sup>1,2</sup>

PAD are acquired, the development of PAD is related to anatomical characteristics of the perampullary region and embryological features of the pancreas, both of which are closely associated with the so-called 'locus minoris resistance'. PAD nearly always penetrate the pancreas along the embryological fusion line of the ventral and dorsal pancreas, which is a weak spot that offers the easiest pathway for a diverticulum. In addition, they demonstrated that PAD also occur at weak spots in the duodenal wall, such as the perivascular connective tissue. In the elderly, a weakened wall and increased luminal pressure may facilitate outpouching of the duodenal mucosa through the vulnerable spot.<sup>18,19</sup>

Pathologic mechanisms through which Lemmel's syndrome is thought to occur include the following. First, diverticulitis or direct mechanical irritation of PAD may cause chronic inflammation of ampulla and lead to chronic fibrosis of papilla (papillitis chronica fibrosa). Second, PAD may cause dysfunction in the sphincter of Oddi. Third, food debris flowing into a diverticulum cause distal CBD or ampulla directly compressed mechanically by PAD.<sup>1-3,6,20,21</sup> In our case, PAD first made a chronic fibrosis of papilla that lead to papillary stenosis. Second PAD directly compressed the distal CBD, PAD seems to have expanded with resultant extrinsic compression of distal CBD. CBD was explored in our patient by ERCP and confirmed by endoscopic ultrasound, no other etiology of obstructive jaundice could be identified other than extra luminal compression by PAD.

Prior to the 1970s, PAD was diagnosed coincidentally during barium meal or surgery, and the discovery rate was low (estimated at less than 1%). After the 1970s, the widespread use of ERCP led to increase diagnosis of PAD.<sup>22</sup> Diagnosing Lemmel's syndrome could be challenging, but being aware of this condition is important to avoid mismanagement and it begins with identification of PAD. PAD are best demonstrated using a side-viewing endoscope during ERCP. On CT scan or MRCP, PAD appear as thin-walled cavitory lesions situated on the medial wall of the duodenum second part that typically contain gas. However, PAD are sometimes filled with fluid and frequently be misinterpreted with pancreatic pseudocyst, pancreatic abscess, cystic neoplasm in the pancreas head or even metastatic lymph node.<sup>1,23-25</sup> Therefore, high index of suspicion is necessary to establish right diagnosis in such cases. In our case, the common bile duct dilatation was at first considered cause by mass, however, after ERCP and then confirmed by endoscopic ultrasound, the dilatation was confirmed cause by the compression of PAD. Currently, the diagnosis of Lemmel's syndrome is mostly made by EUS and ERCP. These examinations confirm the diagnosis, exclude other possible causes such as choledocolithiasis and tumors, and allow to perform treatment by endoscopic sphincterotomy.<sup>13</sup>

The therapeutic options for Lemmel syndrome are surgical resection, endoscopic intervention and conservative treatment.<sup>3</sup> The most simple treatment of Lemmel's syndrome is endoscopic sphincterotomy to release CBD obstruction.<sup>13</sup> But until now, there are no guidelines of the management of Lemmel's syndrome. Earlier this century, surgical diverticulectomy was frequently carried out for non-specific symptoms.

There is now consensus that elective surgical treatment of asymptomatic or minimally symptomatic diverticulum is not justified. Surgical procedures for diverticula in the second part of duodenum are particularly difficult since often it requires mobilization of the duodenum which is retroperitoneal. Surgical or endoscopic interventions should only be reserved for symptomatic diverticulum.<sup>11</sup> Diverticulectomy for abdominal discomfort and indefinite pain is dangerous and unrewarding; it carries a high morbidity and mortality. Only 50% of patients treated with diverticulectomy were relieved of their symptoms.<sup>11,26</sup>

The patient in our case was successfully treated by endoscopic sphincterotomy. Generally, the length of EST is shorter in patients with PAD than in those without PAD due to the weakness of the sphincter of choledochus and risk of perforation in patients with PAD.<sup>10,29</sup> The complication of EST is pancreatitis (5.4 %) and hemorrhage (2.0 %).<sup>32</sup> Until now, guidelines regarding the therapeutic indication of Lemmel's syndrome have not been established, so we must select a suitable therapeutic strategy for each patient. We should consider the patient's quality of life and comorbidity, because Lemmel's syndrome is a benign disease and is usually found in the elderly.

## REFERENCES

1. Kang HS, Hyun JJ, Kim SY, Jung SW. Lemmel 's syndrome, an unusual cause of abdominal pain and jaundice by impacted intradiverticular enterolith? *J Korean Med* 2014;874-8.
2. Rouet J, Gaujoux S, Ronot M. Lemmel's syndrome as a rare cause of obstructive jaundice. *Clin Res Hepatol Gastroenterol* 2012;36:628-31.
3. Takakura K, Koido S, Kajihara M. Repetitive acute cholangitis and pancreatitis due to Lemmel syndrome: A case report. *Int J Diagnostic Imaging* 2014;1:88-91.
4. Thorson CM, Ruiz PS, Roeder RA, Sleeman D, Casillas VJ. The perforated duodenal diverticulum. *Arch Surg* 2012;147:81-8.
5. Lobo DN, Balfour TW, Iftikhar SY. Periapillary diverticula: consequences of failed ERCP. *Ann R Coll Surg Engl* 1998;80:326-31.
6. Zoepf T, Zoepf D, Arnold JC, Benz C, Riemann JF. The relationship between juxtapapillary duodenal diverticula and disorders of the biliopancreatic system: analysis of 350 patients. *Jpn J Gastroenterol* 2001;1:54.
7. Boix J, Lorenzo-Zúñiga V, Añaños F, Domènech E, Morillas RM, Gassull MA. Impact of periampullary duodenal diverticula at endoscopic retrograde cholangiopancreatography: a proposed classification of periampullary duodenal diverticula. *Surg Laparosc Endosc Percutan Tech* 2006;16:208-11.
8. Rajnakova A, Goh PM, Ngoi SS, Lim SG. ERCP in patients with periampullary diverticulum. *Hepatogastroenterology* 2003;50:625-8.
9. Tham TC, Kelly M. Association of periampullary duodenal

- diverticula with bile duct stones and with technical success of endoscopic retrograde cholangiopancreatography. *Endoscopy* 2004;36:1050-3.
10. Kim HW, Kang DH, Choi CW, et al. Limited endoscopic sphincterotomy plus large balloon dilation for choledocholithiasis with periampullary diverticula. *World J Gastroenterol* 2010;16:4335-40.
  11. Rizwan MM, Singh H, Chandar V, Zulfiqar M, Singh V. Duodenal diverticulum and associated pancreatitis: case report with brief review of literature. *World J Gastrointest Endosc* 2011;3:62-3.
  12. Yoneyama F, Miyata K, Ohta H, Takeuchi E, Yamada T, Kobayashi Y. Excision of a juxtapapillary duodenal diverticulum causing biliary obstruction: report of three cases. *J Hepatobiliary Pancreat Surg* 2004;11:69-72.
  13. Chiang TH, Lee YC, Chiu HM, Huang SP, Lin JT, Wang HP. Endoscopic therapeutics for patients with cholangitis caused by the juxtapapillary duodenal diverticulum. *Hepatogastroenterology* 2006;53:501-87.
  14. Teven CM, Grossman E, Roggin KK, Matthews JB. Surgical management of pancreaticobiliary disease associated with juxtapapillary duodenal diverticula: case series and review of the literature. *J Gastrointest Surg* 2012;1:1436-41.
  15. Mahajan SK, Kashyap R, Chandel UK, Mokta J, Minhas SS. Duodenal diverticulum: review of literature. *Indian J Surg* 2004;66:10-12.
  16. Kua JE, Seah A, So JB. Periampullary diverticulum: a case of bleeding from a periampullary diverticula. *Ann Acad Med Singapore* 2005;34:636-8.
  17. Harford, William. Duodenal diverticula. *Sleisenger and Fordtran's Gastrointestinal and Liver Disease* 2010;337-8.
  18. Egawa N, Anjiki H, Takuma K, Kamisawa T. Juxtapapillary duodenal diverticula and pancreatobiliary disease. *Dig Surg* 2010;27:105-9.
  19. Ko KS, Kim SH, Kim HC, Kim IH, Lee SO. Juxtapapillary duodenal diverticula risk development and recurrence of biliary stone. *J Korean Med Sci* 2012;27:772-6.
  20. Qi C, Zhaodong L, Shengwei L. Diagnosis and treatment of juxta-ampullary duodenal diverticulum. *Clin Investig Med* 2010;33:298-303.
  21. Macari M. Original report cystic neoplasms of the pancreas: CT and MR imaging findings in seven. *AJR Am J Roentgenol* 2003:195-9.
  22. Ono M, Kamisawa T, Tu Y, Egawa N. Clinical imaging MRCP and ERCP in Lemmel Syndrome. *J Pancreas* 2005;6:277-8.
  23. Sherlock, Sheila. *Imaging of the biliary tract: interventional radiology and endoscopy disease of liver and billiary system.* Blackwell Science 2002;562-78.
  24. Mathis KL, Farley DR. Operative management of symptomatic duodenal diverticula. *Am J Surg* 2007;193:305-9.
  25. Martins PN, Benckert C, Vetzke-Schlieker W, Pratschke J, Tullius SG, Neuhaus P. Intraduodenal diverticulum associated with a double common bile duct causing recurrent pancreatitis and cholangitis: Report of a case. *Surg Today* 2007;37:320-4.
  26. Abu Dayyeh BK, Baron TH. Endoscopic sphincterotomy: indications, techniques, and adverse events. *Tech Gastrointest Endosc* 2012;14:141-7.