

Mirizzi's Syndrome

*Fachrull**, *Anggilia Stephanie**, *E Mudjaddid***

*Department of Internal Medicine, Faculty of Medicine,
University of Indonesia/Dr. Cipto Mangunkusumo General National Hospital, Jakarta

**Division of Psychosomatic, Department of Internal Medicine, Faculty of Medicine,
University of Indonesia/Dr. Cipto Mangunkusumo General National Hospital, Jakarta

Corresponding author:

E Mudjaddid. Division of Psychosomatic, Department of Internal Medicine, Dr. Cipto Mangunkusumo General National Hospital. Jl. Diponegoro No.71 Jakarta Indonesia. Phone/facsimile: +62-21-31930956. E-mail: mudjaddid@yahoo.com

ABSTRACT

Mirizzi's syndrome was an obstruction caused by gallstone located in gallbladder neck (or cystic duct) or outside gallbladder that caused a dilatation of gallbladder and narrowing of adjacent duct, sometimes with the presence of cholecystocholedochal fistula. Mirizzi's syndrome was a rare complication of gallbladder stone. We reported a 42 years old woman complained progressive icteric sclera. Patients also complained dark urine and light stool. During physical examination, we found an icteric sclera, pain in right upper quadrant (visual analogue scale/VAS 3), and generalized icterus (greenish yellow). Complete examination revealed a Mirizzi's syndrome.

Keywords: *Mirizzi's syndrome, icteric, gallstone*

ABSTRAK

Mirizzi's syndrome adalah suatu obstruksi yang disebabkan oleh batu pada leher kandung empedu (atau duktus sistikus) maupun di luar kandung empedu yang membuat pelebaran saluran kandung empedu sekaligus penyempitan pada saluran jaringan sekitar; terkadang disertai fistula pada cholecystocholedochal. Mirizzi's syndrome merupakan suatu kasus komplikasi yang relatif jarang ditemukan pada penyakit batu kandung empedu. Kami melaporkan wanita berusia 42 tahun dengan keluhan mata tampak semakin kuning. Buang air kecil seperti teh serta buang air besar dempul. Pemeriksaan fisik ditemukan sklera ikterik, nyeri tekan terutama pada bagian perut kanan atas (visual analogue scale/VAS 3), serta seluruh badan tampak ikterik (kuning kehijauan). Pasien sudah dilakukan pemeriksaan penunjang secara lengkap yang dimana hasilnya sesuai dengan gambaran Mirizzi's syndrome.

Kata kunci : *Mirizzi's syndrome, ikterik, batu empedu*

INTRODUCTION

In 1905, Kehr published the first case of benign gallbladder obstruction caused by stone in gallbladder. In 1948, Mirizzi analyzed that case and make a classification based on clinical manifestation marked by mechanical compression in common hepatic duct caused by gallstone inside gallbladder (Hartmann's

puch) or in cystic duct, ever since its condition was called Mirizzi's syndrome.^{1,2} Mirizzi's syndrome was a rarely found complication of gallbladder stone, and yet it most effective treatment is cholecystectomy. It also possible to find any severe inflammation in subhepatic area involving hepatoduodenal ligament. Otherwise, acute acalculous cholecystitis (ACC) could

lead to clinical condition and supporting examination that similar to Mirizzi's syndrome.^{3,4}

Mirizzi's syndrome was rarely found in developed countries, with less than 1% incidence per year, and found as complication in 1-2% of symptomatic cholelithiasis patients. Incidence rate in Indonesia was unknown because of its rare case and limited publication. Most of gallstone was asymptomatic and did not complicate, so that it does not need any treatment. While in developing countries such as South America, Mirizzi's syndrome was found higher, account for 4.7-5.7%. The more frequent Mirizzi's syndrome detected, the more its surgical treatment frequency.^{5,6} Mirizzi's syndrome was mostly occur in patients aged 53-70 years old, most of them was female (70%), although it is still possible to occur in other age groups since the gallstone was present. This syndrome occur at acute process, but most patients complained its symptoms when entered chronic phase.

Clinical manifestation of Mirizzi's syndrome was unspecific, mostly found as obstructive jaundice (60-100%) with upper right quadrant pain (50-100%), and fever. Mirizzi's syndrome sometimes occur together with acute cholecystitis, acute cholangitis, acute pancreatitis, and rarely gallbladder ileus. Laboratory examination showed hyperbilirubinemia, increase of aminotransaminase, and leukocytosis, simultaneously with acute cholecystitis, acute cholangitis, and acute pancreatitis. Tumor marker could also be found increasing, such as CA19-9 especially in type II Mirizzi's syndrome. In general, CA19-9 was a marker of malignancy so that Mirizzi's syndrome diagnosis should be proven, otherwise, it was a malignancy.^{5,7,8} Treatment was done by surgery after it was diagnosed preoperatively. Inaccurate diagnosis result in higher morbidity and mortality, approximately 17%. To ensure the diagnosis, imaging and endoscopic examination could be done.^{5,9} This case report discuss about obstructive jaundice caused by gallstone. Diagnosis was obtained by several examination which is suitable for Mirizzi's syndrome.

CASE ILLUSTRATION

A woman aged 42 years old came to polyclinic complaining a progressive yellow eyes since 7 days before admission. Patients looked jaundice, complaining itch in whole body even after consuming drugs (patients forget the drugs name), postprandial abdominal pain especially after high-fat diet consumption, nausea without vomiting, fever, dark urine, and light stool. One month before admissions,

patients went to Persahabatan Hospital and said to have gallbladder obstruction, hospitalized for 7 days before finally referred to Cipto Mangunkusumo Hospital. After physical and laboratory examinations, patients were planned to undergo endoscopic retrograde cholangiopancreatography (ERCP). This is the first time patient having jaundice and none in her family have the similar symptoms and jaundice.

Physical examination showed a 120/70 mmHg blood pressure, 90 x/minutes heart rate, 20 x/minutes respiratory rate, 37°C body temperature, 99% oxygen saturation, visual analogue scale (VAS) 3 abdominal pain, and body mass index (BMI) of 23,43 kg/m². It also found an icteric sclera, no lymphadenopathy, heart and lung was normal, abdominal examination showed a soft and supple abdominal wall, right upper quadrant pain, no hepatomegaly and splenomegaly, bowel sound (+), no ascites (shifting dullness), and whole body was icteric (greenish yellow).

Laboratory examination showed hemoglobin (Hb) 11 g/dL, hematocrite (Ht) 20%, leukocyte 10370, thrombocyte 344000, aspartate aminotransferase (AST)/alanine aminotransferase (ALT) 149/109, amylase/lipase 53/75, total bilirubin of 22,14 mg/dL, with direct/indirect bilirubin of 19,87/2,27 mg/dL. It also found an alkaline phosphatase of 601 U/L, gamma GT 201 U/L, CA 19-9 155,5 U/mL, CEA 2,61 mg/mL. Posterior anterior thorax x-ray and electrocardiography found no abnormalities. Computed tomography (CT) scan revealed a distal common bile duct (CBD) stone caused obstruction and dilatation of proximal CBD, common hepatic duct, and both right and left intrahepatic duct. Abdominal ultrasonography (USG) showed a dilatation of both intra and extrahepatic duct, chronic cholecystitis, and splenomegaly. ERCP findings showed a dilatation of both intra and extrahepatic biliary duct caused by large gallstone in cystic duct, concluded as Mirizzi's syndrome. From clinical, physical, and supporting examination, patients was diagnosed with obstructive jaundice caused by Mirizzi's syndrome. Patients was given Omeprazole 1 x 20 mg, Ultracet 3 x 1 tab (for pain management), Urdafalk 3 x 1 tablet, soft-low fat diet, and planned to digestive surgeon consultation.

During hospitalization, patient was having a clinical improvement by diminished jaundice, reduced abdominal pain before and after meals, clear urine and slight light stool, less pruritus and no fever present. The latest laboratory examination showed total bilirubin of 6,50 mg/dL, conjugated bilirubin 6,19 mg/dL, unconjugated bilirubin 0,31 mg/dL, and AST/AT 61/36

U/L. Patient then prepared for elective surgery and routine control to gastroenterology polyclinic.

After outpatients care, magnetic resonance cholangiopancreatography (MRCP) was done. The result showed a gallstone in cystic duct sized 2 x 1,4 cm without dilatation and the presence of stone in gallbladder, and no dilatation of intrahepatic biliary duct and common bile duct.

DISCUSSION

Mirizzi's syndrome was an obstruction caused by gallstone located in gallbladder neck (or cystic duct) or outside gallbladder that caused a dilatation of gallbladder and narrowing of adjacent duct, sometimes with the presence of cholecystocholedochal fistula. This was one of the most rarely found complication of cholelithiasis.⁷

Patient was a woman aged 42 years old and overweight, a risk factor condition for gallbladder stone. Mirizzi's syndrome was commonly found in woman aged 53-70 years old in range, even there is still possibilities to occur in other aged and gender group. Patients looked jaundice in whole body suddenly with colic pain in right upper quadrant, dark urine, and light stool. All sign and symptoms was identic for obstructive jaundice, so that several radiologic examination was done to find its etiology, among them was USG, CT Scan, ERCP, and MRCP.⁵

Laboratory examination showed an increase of amylase/lipase (53/75) and bilirubin level (total bilirubin 22,14 mg/dL, conjugated bilirubin 19,87 mg/dL, unconjugated bilirubin 2,27 mg/dL), and also alkaline phosphatase (601 U/L) and Gamma GT (201 U). This was similar to findings in bile duct obstruction. Mirizzi's syndrome was also one of the cause of bile duct obstruction, shown by the high level of alkaline phosphatase and Gamma GT. It also found an increase of CA 19-9 level (155,5 U/mL) that commonly suspecting a malignancy, was also found to be higher in Mirizzi's syndrome.^{5,7}

USG examination showed a dilatation of both intra and extrahepatic bile duct and chronic cholecystitis, suitable for posthepatic obstruction. There were several cause of posthepatic obstruction, such as gallstone, tumor, or stricture. To differentiate those possibility, USG was specific enough in several cases. Gallstone was specifically seen in USG as hyperechoic mass with acoustic shadow.

In Mirizzi's syndrome, a gallstone could be found to obstruct in gallbladder neck, accompanied with

dilatation of proximal bile duct and adjacent duct. USG was a simple radiologic examination that used to detect obstructive jaundice and help to diagnose Mirizzi's syndrome with 29% sensitivity and 8,3-27% specificity. In this patient, the presence of gallstone was doubtful, so that further examination was done.^{1,3,5} CT scan examination showed a gallstone in distal CBD that cause the obstruction and dilatation of proximal CBD, common hepatic duct, and both right and left intrahepatic duct. A unique findings in Mirizzi's syndrome using CT Scan was that the presence of stone in cystic duct or bladder neck with bile duct dilatation.^{1,5}

ERCP examination showed a dilatation of biliary duct (intra and extrahepatic) caused by large gallstone in cystic duct, suspect a Mirizzi's syndrome. This was suitable for the characteristic of Mirizzi's syndrome. ERCP has a higher sensitivity that CT Scan (42%) with 55-90% accuracy that can showed any malignancy in liver and hepatic portal vein. Even ERCP was known as diagnostic and therapeutic tools, a large and unusual location of stone that present in this case was hard to be extracted using ERCP. A moving stone location in this case was caused by spontaneous detachment of obstruction.^{1,5}

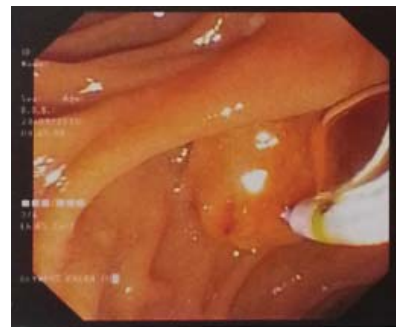

Figure 1. ERCP in patient showed a large stone in syctic duct

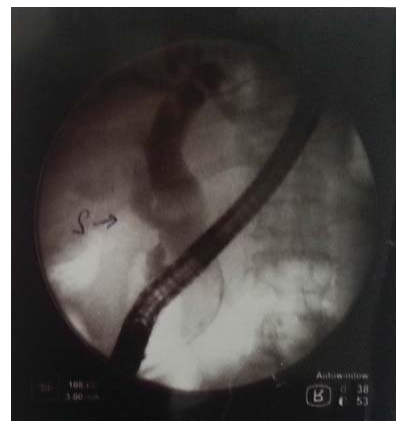

Figure 2. ERCP patients showed a radiopaque findings in cystic duct

MRCP result showed a gallstone inside distal cystic duct sized 2 x 1,4 cm without any dilatation and stone in gallbladder, no intrahepatic biliary and common bile duct dilatation. The weakness of this case report was that MRCP was done after patient having bilirubin improvement. A gallstone findings located in cystic duct without bile duct dilatation in this case was suspected for spontaneous moving of gallstone. This spontaneous moving of gallstone could improve patient clinical outcome without any operative surgery.

The accuracy of MRCP was 50%. This examination was used to know the location of the obstruction (in cystic duct or other place) and to find the presence of fistula. Because of no fistula found in this examination, we can concluded that patient was having Mirizzi's syndrome type I.¹

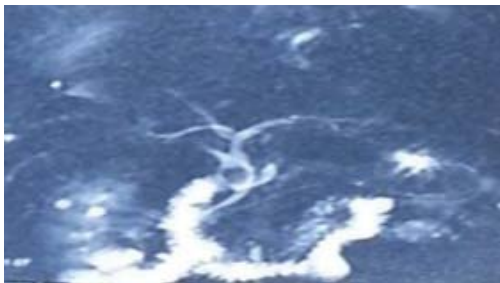


Figure 3. MRCP in patient showed a gallstone in distal cystic duct

REFERENCES

1. Pariani D, Zetti G, Galli F, Cortese F. Mirizzi syndrome: from ultrasound diagnosis to surgery. *Case Rep Surg* 2013;2013:1-4.
2. Peterli R, Geering P, Huber AK. Mirizzi syndrome: preoperative diagnosis and therapeutic management. *Swiss Surg* 1995;6:298-303.
3. Milone M, Musella M, Maietta P, Guadiso D, Pisapia A, Coretti G, et al. Acute acalculous cholecystitis determining Mirizzi's syndrome. *BMC Surg* 2014;14:90.
4. Mirizzi P. Syndrome del conducto hepatico. *Journal International de Chirurgie* 1948;8:731-77.
5. Beltran M. Mirizzi's syndrome: history, current knowledge and proposal of a simplified classification. *World J Gastroenterol* 2012;18:4639-50.
6. Lesmana LA. Penyakit batu empedu. In: Sudoyo AW, Setyohadi B, Alwi I, Simadibrata M, Setiati S, eds. *Buku ajar ilmu penyakit dalam*. 4th ed. Jakarta: Interna Publ 2006:IV,p.479-82.
7. Gibor U, Perry Z, Netz U, Glazer Y, Laufer L, Kirshtein B. CA 19-9 in the presence of obstructive jaundice due to Mirizzi's syndrome. *Imaj* 2015;17:60-1.
8. Hazzan D, Golijanin D, Reissman P, Adler SN, Shiloni E. Combined endoscopic and surgical management of Mirizzi's syndrome. *Surg Endosc* 1999;13:618-20.
9. Ibrarullah, Mishra T, Das AP. Mirizzi's syndrome. *Indian J Surg* 2008;70:281-7.
10. Cases Info. Mirizzi's Syndrome [serial online] 2015 [cited 2015 Oct 4]. Available from: URL: <http://www.ultrasoundcases.info/Default.aspx>.