

Upper Gastrointestinal Endoscopy as Diagnostic Test for Detection of Gastric Malignancy in Sanglah Hospital Denpasar

Hendra Koncoro*, Putu Prathiwi Primadharsini**,
Luh Putulin Indrayani Maker***, I Dewa Nyoman Wibawa**

*Department of Internal Medicine, Faculty of Medicine, University of Udayana Sanglah Hospital
Denpasar

**Division of Gastroentero-hepatology, Department of Internal Medicine, Faculty of Medicine
University of Udayana/Sanglah Hospital, Denpasar

***Department of Anatomy Pathology, Faculty of Medicine
University of Udayana/Sanglah Hospital, Denpasar

Corresponding author:

I Dewa Nyoman Wibawa. Division of Gastroentero-hepatology, Department of Internal Medicine, Sanglah General Hospital. Jl. Diponegoro Denpasar Indonesia. Phone: +62-361-244177; Facsimile: +62-361-244177. E-mail: dnwib@dps.centrin.net.id

ABSTRACT

Background: Gastric malignancy is the third most common cause of cancer-related death in the world. Upper gastrointestinal (UGI) endoscopy for detection of gastric malignancy has been used widely in Indonesia. This study aimed to determine the prevalence of gastric malignancy and diagnostic value of UGI endoscopy in detection of gastric malignancy in Sanglah Hospital, Denpasar.

Method: A retrospective study on patients undergoing UGI endoscopy in Endoscopy Unit of Sanglah Hospital Denpasar between January 2012 and December 2014 was conducted. Endoscopic and histological diagnosis were documented. The diagnostic test of endoscopic diagnosis were conducted by showing its sensitivity, specificity, positive predictive value, negative predictive value, and accuracy.

Results: One thousand and sixty eight patients with upper gastrointestinal symptoms were subjected to endoscopy between January 2012 and December 2014. Of the 1068 cases, 39 patients were suspected for gastric malignant lesions on UGI endoscopy. During the study period, histopathologically-confirmed gastric malignancy was found in 2.72% patients. The sensitivity, specificity, positive predictive value, negative predictive value, and accuracy of UGI endoscopic diagnosis for these neoplastic lesions were 100%, 99.04%, 74.36%, 100%, and 99.06%, respectively.

Conclusion: The prevalence of gastric malignancy was higher compared to western countries. Endoscopy is important as diagnostic tool in patients with suspicion of gastric malignancy. Greater suspicion in clinical judgment and carefulness in excluding malignancy through one histopathology negative findings need to be done to reduce the number of misdiagnoses of gastric malignancy.

Keywords: prevalence, gastric malignancy, histopathology, gastric biopsy

ABSTRAK

Latar belakang: Keganasan gaster merupakan penyebab kematian ketiga paling banyak terkait kanker di dunia. Endoskopi saluran cerna bagian atas (SCBA) untuk deteksi keganasan gaster telah digunakan secara

luas di Indonesia. Penelitian ini bertujuan untuk menentukan prevalensi keganasan gaster dan nilai diagnostik endoskopi SCBA dalam deteksi keganasan gaster di Rumah Sakit (RS) Sanglah, Denpasar.

Metode: Suatu penelitian retrospektif dilakukan pada pasien yang dilakukan endoskopi SCBA di Unit Endoskopi RS Sanglah Denpasar antara Januari 2012 dan Desember 2014. Diagnosis endoskopis dan histologis dicatat. Uji diagnostik diagnosis endoskopis dilakukan dengan menunjukkan sensitivitas, spesifisitas, nilai prediktif positif, nilai prediktif negatif, dan akurasi.

Hasil: Seribu enam puluh delapan (1068) pasien dengan keluhan pada saluran cerna bagian atas dilakukan endoskopi antara Januari 2012 dan Desember 2014. Dari 1068 kasus, 39 pasien diduga terdapat lesi ganas gaster pada endoskopi SCBA. Selama periode penelitian, keganasan gaster yang dikonfirmasi melalui histopatologi ditemukan pada 2,72% pasien. Sensitivitas, spesifisitas, nilai prediksi positif, nilai prediksi negatif, dan akurasi diagnosis endoskopi SCBA untuk lesi neoplastik ini berturut-turut adalah 100%, 99,04%, 74,36%, 100%, dan 99,06%.

Simpulan: Prevalensi keganasan gaster lebih tinggi dibandingkan dengan negara-negara Barat. Endoskopi penting sebagai alat diagnostik pada pasien dengan dugaan keganasan gaster. Kewaspadaan dalam penilaian klinis dan kehati-hatian dalam mengeksklusi keganasan berdasarkan pemeriksaan histopatologi yang negatif perlu dilakukan untuk mengurangi jumlah kesalahan diagnosis keganasan gaster.

Kata Kunci: prevalensi, keganasan gaster, histopatologi, biopsi gaster

INTRODUCTION

Nearly one million new cases of gastric malignancy were estimated to occur in 2012, making it the fifth most commonly diagnosed cancer in the world.¹ Gastric malignancy itself remains a global killer being the world's third commonest cause of death from malignant disease.^{1,2} Global Burden of Cancer Study (GLOBOCAN) estimates that 723,000 cancer related deaths occurred worldwide in 2012 were caused by gastric malignancy.¹ More than 70% of the world's new cases occur in developing countries, and half of the world total occurs in Asia. World Health Organization South-East Asia Region (WHO SEARO) recorded 91,000 new cases of gastric cancer in 2012, 6,000 (6.6%) of them were from Indonesia. Although the incidence of gastric cancer in Indonesia is very low, gastric cancer may result in 5,400 deaths in 2012.¹ Due to high rate of mortality, accurate diagnostic study is necessary in order to establish early diagnosis.

Endoscopy has facilitated early diagnosis of patients with upper gastrointestinal (UGI) malignancy and provided modalities in obtaining samples for histological diagnosis of gastric cancer.³ It is widely known that the endoscopic appearances highly suggestive but not pathognomonic and needs further histological confirmation. The diagnostic accuracy for detection of gastric cancer are varied among studies, ranging from 86-97.4%.^{4,5} For the distinction between malignant and non-malignant lesion, histological evaluation remains the gold standard.⁶ Therefore, we

aim to determine the prevalence of gastric malignancy and diagnostic value of UGI endoscopy in detection of gastric malignancy in Sanglah Hospital, Denpasar.

METHOD

This is a retrospective analytical study of UGI endoscopy conducted on patients in Endoscopy Unit of Sanglah Hospital Denpasar between January 2012 and December 2014. Inclusion criteria were all patients with dyspepsia, heartburn, or history of gastrointestinal bleeding. Exclusion criteria were patients under 17 years old and patients with documented chronic liver disease.

Endoscopy was done by using flexible video endoscope (Olympus Exera II GF-170). On endoscopy, gastrointestinal lesions were visualized. Details of the site, extent, and type of the lesion were recorded. After visualization of the lesion, biopsies were retrieved by using forceps. Two biopsies were taken for non-malignant lesion, and 6 biopsies for malignant lesion. Biopsies were transferred to a container bottle containing 10% formalin buffer, labelled with patient's identity, immediately after the biopsies were obtained. Biopsy tissues then processed and cut by using microtome until 4-5 series of slides were resulted. Slides were stained routinely with Giemsa. The histopathological interpretations were derived according to WHO classification.⁶ Biopsies were interpreted as negative and positive for malignancy. Malignant lesion were interpreted as a well-demarcated lesion and irregularity in color/surface pattern.

Malignant ulcer were defined as an ulcerated mass with nodular looking folds and irregular overhanging, nodular margin.

SPSS 17 was used in statistical analysis of this study. Age was summarized as mean and standard deviation (SD). Sex was presented as counts and percentages. Using histological examination as the gold standard for diagnosis of gastric malignancy, we calculated sensitivity, specificity, positive predictive value (PPV), negative predictive value (NPV), and accuracy by generating 2 x 2 tables.

RESULTS

Between January 2012 and December 2014, 1478 underwent UGI endoscopy. Three hundred and ten patients were excluded because of documented chronic liver disease or had age less than 17 years old. One thousand and sixty eight patients were included in this study. Mean age of patients was 51.24 ± 15.14 years. There were 614 (57.49%) males and 454 (42.51%) females. Thirty nine (39) out of 1068 patients with endoscopically proven gastric malignancy were identified. On histopathological examination, biopsies were positive for malignancy in 29 (2.72%) cases and negative in 10 cases. Majority of the lesions were found in the antrum (51.28%), 14 (35.9%) in the body, 2 (5.13%) in the cardia, and 3 (7.69%) were diffuse. A histological diagnosis of gastric cancer was established in 29 (74.36%) patients. In 10 (25.64%) patients the histology was negative for malignancy (Table 1, Figure 1). Eighteen out of 29 (62%) patients were less than 55 years old (Figure 2).

Out of the 39 cases diagnosed as probable gastric malignancy endoscopically, 29 were found to be malignant and 10 were negative for malignancy (Table 2). The sensitivity, specificity, positive predictive value and negative predictive value were shown in table 3.

Table 1. Endoscopical and histological findings in study population

Criteria	n (%)
Upper GI endoscopy	
No malignancy	995 (93.16%)
Esophageal malignancy	18 (1.69%)
Gastric malignancy	39 (3.65%)
Duodenal malignancy	16 (1.5%)
Gastric cancer histology	
Adenocarcinoma	20 (51.28%)
Signet ring cell carcinoma	6 (15.38%)
Others (GIST, MALT lymphoma)	3 (7.7%)
Negative for malignancy	10 (25.64%)
Gastric cancer location	
Cardia	2 (5.13%)
Corpus	14 (35.9%)
Antrum	20 (51.28%)
Diffuse	3 (7.69%)

GIST: gastrointestinal stromal tumor; MALT: mucosal-associated lymphoid tissue

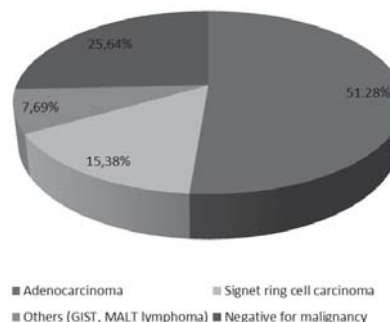


Figure 1. Suspected gastric cancer histology

Gastric Cancer Age Group

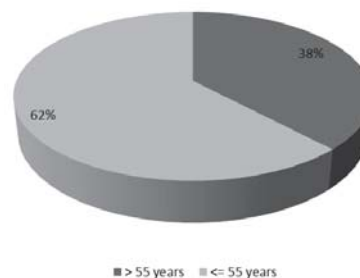


Figure 2. Gastric cancer age group

Table 2. Comparison of endoscopical and histological findings in gastric malignancy

Endoscopic diagnosis	Histopathological diagnosis	
	Positive for malignancy	Negative for malignancy
Probable malignancy	29	10
Not malignancy	0	1029
Total	29	1039

Table 3. Diagnostic test of endoscopy in diagnosing gastric malignancy

Diagnostic test	n (%)
Sensitivity	100%
Specificity	99.04%
Positive predictive value	74.36%
Negative predictive value	100%
Accuracy	99.06%

DISCUSSION

Although the prevalence of gastric cancer has been declining over several decades, it still represents major health problem.¹ By knowing the prevalence, physician may build awareness towards gastric cancer. In this study, prevalence of gastric malignancy confirmed by histopathological study was 2.72%. Among patients in Western Countries who had endoscopic evaluations, gastric carcinoma were found in 1-2% of cases.⁷ However, this number is higher in Asia. Study in Cipto Mangunkusumo hospital showed prevalence of 2.98%.⁸ Malignancy was noted in 3.5% of the total 3,432 patients performing endoscopy in India.⁹ Study in East Asian Countries showed more dramatic results,

performed by Bai et al which generate prevalence of 4.25%.¹⁰

This study also showed that 62% of gastric cancer patients were < 55 years old. The increased frequency of gastric cancer patients younger than traditional cut-off for alarm signs showed that increased surveillance on younger age group need to be taken. Study in Jakarta from 2007-2011 showed that there was shifting toward younger age. This condition may reflect an increased health awareness of patients, increased number of endoscopists and endoscopic facilities in Indonesia.¹¹

Macroscopic appearance in endoscopy has shown high probability of gastric malignancy. However, there has been few reports of studies questioning the accuracy of endoscopy.^{4,5} In the current study, we found that overall accuracy rate of endoscopic biopsy calculated for all patients was 99.06%. Tatsuta et al calculated the accuracy of endoscopic biopsy in diagnosis of malignancies of the upper GI tract and gave 97.4% as the result.⁵ Like our result, this study clearly indicate that endoscopic biopsy is a very reliable method for the early diagnosis of gastric cancer.

This study found 10 (0.94%) false-negative diagnoses of malignancy among 1,068 patients who underwent UGI endoscopy. There are multiple factors that may caused misdiagnosis of gastric cancer. In a study conducted by Pailoor et al, 2 out of 23 (9.7%) endoscopically suspected gastric malignancy were proven to be chronic gastritis and 8 out of 14 (57.12%) benign gastric ulcer found on endoscopy were adenocarcinoma when examined by pathologists.¹² The difference between endoscopy and histology findings may be caused by non-representative material. Aslan et al in a case report of an UGI malignancy stated that large lesion size and the small sample taken via the endoscopic biopsy forceps may result in inaccurate diagnosis.¹³ Other reason stated by Tatsuta et al that may caused low accuracy in diagnosing gastric malignancy was that the cancer tissues were usually covered by normal gastric mucous, and when biopsy specimens were too small and too superficial, malignant tissues were difficult to obtain. Therefore, it was suggested that superficial erosions or shallow ulcerations may serve as the most suitable target sites for biopsy.⁵

Medication used for relieving dyspeptic symptoms may also cause false-negative diagnosis. Most patients in this study had proton pump inhibitors prior to endoscopy. Use of the powerful acid suppressing agents such as proton pump inhibitors and H₂ receptor antagonists can mask endoscopic signs of early gastric

cancer. This condition resulted from mucosal healing of lesion, especially in early gastric cancer. The improved mucosal lesion may also covered malignant tissue when biopsied.¹⁴

In order to reduce false-negative diagnosis, Amin et al recommended to take multiple biopsies and for gastric ulcers these should be obtained from both the rim and base.¹⁵ Recommendations on the optimum number of biopsies differ but some studies noted that the greater the biopsy number performed, the more accurate the diagnosis of UGI malignancy.^{15,16,17} Graham et al stated that the first biopsy specimen yielded a correct diagnosis in 70% of gastric carcinomas while a total of seven biopsy specimens yielded greater than 98%.¹⁶ Other study suggested at least 6 biopsy specimens should be taken from suspected malignant gastric lesions to obtain diagnostic accuracy of 100%.^{17,18} However, multiple biopsies posed some issues need to be remembered, such as high tendency to post procedure bleeding, increased time taken on endoscopy, and extra hour for examination by pathologists.¹⁹

Some techniques may also be used in obtaining malignant tissue, such as brushing, aspiration, suction, salvage, and imprint cytology to improve the diagnostic yield of biopsy specimens in UGI malignancies.¹² These may be done in some difficult gastric malignancy, especially those located in sub mucous. Submucous tumors present some difficulties in their diagnosis, especially because its definitive diagnosis needs histologic confirmation. In our study, biopsy samples were only obtained by using forceps and only limited to the covering mucous. Kojima et al used endoscopic resection for lesions originating in the muscularis mucosa or submucous.²⁰

This study has several implications. First, UGI endoscopy still remain important modality in diagnosing malignancy and therefore need to be distributed throughout every district hospital as screening tool. Second, several important factors such as evaluation of the clinical data, supporting laboratory or imaging data, experience in choosing appropriate biopsy number and site, proper processing of biopsy tissue and meticulous report by the histopathologist for interpretation of endoscopic biopsies may be noticed in establishing diagnosis of gastric malignancy. Diagnosis can't be excluded by only one negative findings on histopathology, therefore follow-up endoscopy may be needed. Endoscopy is an informative tool with high sensitivity and specificity to diagnose gastric malignancy.

CONCLUSION

Gastric cancer was found to be high compared to Western Countries. Endoscopy is important as diagnostic tool in patients with suspicion of gastric malignancy. Greater suspicion and more rigorous protocol in endoscopy and biopsy must be implemented in order to reduce the number of missed diagnoses of UGI malignancy.

REFERENCES

1. Ferlay J, Soerjomataram I, Ervik M, Dikshit R, Eser S, Mathers C, et al. Globocan 2012 v1.0. Cancer incidence and mortality worldwide: IARC cancer base No. 11. International Agency for Research on Cancer [serial online] 2013 [cited 2015 Feb 1]. Available from: URL: <http://globocan.iarc.fr>.
2. Kelley JR, Duggan JM. Gastric cancer epidemiology and risk factors. *J Clin Epidemiol* 2003;56:1-9.
3. Hirota WK, Zuckerman MJ, Adler DG, Davila RE, Egan J, Leighton JA, et al. ASGE guideline: the role of endoscopy in the surveillance of premalignant conditions of the upper GI tract. *Gastro intest Endosc* 2006;63:570-80.
4. Jorde R, Ostensen H, Bostad LH, Burhol PG, Langmark FT. Cancer detection in biopsy specimens taken from different types of gastric lesions. *Cancer* 1986;58:376-82.
5. Tatsuta M, Iishi H, Okuda S, Oshinia A, Taniguchi H. Prospective evaluation of diagnostic accuracy of gastro fiber scopic biopsy in diagnosis of gastric cancer. *Cancer* 1989;63:1415-20.
6. World Health Organization classification of tumours. In: Hamilton SR, Aaltonen LA, eds. *Pathology and Genetics of Tumours of the Digestive System*. Lyon: IARC Press 2000.p.37-52.
7. Sundar N, Muraleedharan V, Pandit J, Green JT, Crimmins R, Swift GL. Does endoscopy diagnose early gastrointestinal cancer in patients with uncomplicated dyspepsia?. *Post grad Med J* 2006;82:52-4.
8. Yusuf AI, Syam AF, Abdullah M, Makmun D, Simadibrata M, Manan C, et al. Upper gastrointestinal malignancy among dyspepsia patients in Cipto Mangunkusumo Hospital Jakarta. *Indones J Gastroenterol Hepatol Dig Endosc* 2009;10:92-5.
9. Sumathi B, Navaneethan U, Jayanthi V. Appropriateness of indications for diagnostic upper gastrointestinal endoscopy in India. *Singapore Med J* 2008;49:970-6.
10. Bai Y, Li ZS, Zou DW, Wu RP, Yao YZ, Jin ZD, et al. Alarm features and age for predicting upper gastrointestinal malignancy in Chinese patients with dyspepsia with high background prevalence of *Helicobacter pylori* infection and upper gastrointestinal malignancy: an endoscopic database review of 102,665 patients from 1996 to 2006. *Gut* 2010;59:722-8.
11. Makmun D, Simadibrata M, Abdullah M, Syam AF, Fauzi A, Renaldi K, et al. Changing trends in gastrointestinal malignancy in Indonesia: The Jakarta experience. *J Cancer Res Ther* 2014;2:160-8.
12. Pailoor K, Sarpangala MK, Naik RCN. Histopathologic diagnosis of gastric biopsies in correlation with endoscopy – a study in tertiary care center. *Adv Lab Med Int* 2013;3:22-31.
13. Aslan S, Cetin B, Markoc F, Cetin A. A duodenal villous adenoma associated with in situ carcinoma: A case report. *Turk J Cancer* 2001;31:162-7.
14. Suvakovic Z, Bramble MG, Jones R, Wilson C, Idle N, Ryott J. Improving the detection rate of early gastric cancer requires more than open access gastroscopy: a five year study. *Gut* 1997;41:308-13.
15. Amin A, Gilmour H, Graham L, Paterson-Brown S, Terrace J, Crofts TJ. Gastric adenocarcinoma missed at endoscopy. *J R Coll Surg Edinb* 2002;47:681-4.
16. Graham DY, Schwartz JT, Cain GD, Gyorkey. Prospective evaluation of biopsy number in the diagnosis of esophageal and gastric carcinoma. *Gastroenterology* 1982;82:228-31.
17. Lal N, Bhasin DK, Malik AK, Gupta NM, Singh K, Mehta SK. Optimal number of biopsy specimens in the diagnosis of carcinoma of the oesophagus. *Gut* 1992;33:724-6.
18. Misumi A, Mori K, Ikeda T, Misumi K, Ookubo F, Shimamoto M, et al. Evaluation of fibergastroscopic biopsy in the diagnosis of gastric cancer. A study of 339 cases. *Gastroenterol Jpn* 1978;13:255-63.
19. Choi Y, Choi HS, Jeon WK, Kim BI, Park DI, Cho YK, et al. Optimal number of endoscopic biopsies in diagnosis of advanced gastric and colorectal cancer. *J Korean Med Sci* 2012;27:36-9.
20. Kojima T, Takahashi H, Parra-Blanco A, Kohsen K, Fujita R. Diagnosis of submucosal tumor of the upper GI tract by endoscopic resection. *Gastro intest Endosc* 1999;50:516-22.