

# Adenoid Cystic Carcinoma of the Esophagus

*Chaidir Aulia*

Department of Internal Medicine, Pondok Indah Hospital, Jakarta

## ABSTRACT

*Adenoid cystic carcinoma is an extremely rare case of the esophagus. We present a female patient, aged 76 years who present with dysphagia and weight loss for the last three month. On endoscopy there was a luminal narrowing in the middle third of the esophagus. Diagnosis was challenging due to the stenosis and the tumor size. Histopathological confirmation was obtained by subcarinal fine-needle aspiration biopsy. This type of cancer is very aggressive with short survival time. Further studies are needed to define optimal treatment.*

**Keywords:** *dysphagia, adenoid cystic carcinoma*

## INTRODUCTION

Cancer of the esophagus is relatively uncommon, but it is the eighth most common cancers worldwide (4.2%). The incidence of esophageal cancer is differs in different countries. A 20-fold variation is observed between high-risk in China and low-risk in Western Africa. The incidence for men and women per 100,000 population are 27.4 : 12.0 in China and 1.3 : 0.6 in Western Africa. The incidence in South-Eastern Asia is 3.1 : 1.2 per 100,000 population for men and women. Esophageal cancer is more common in men than in women; in most areas, the sex ratio is 7:1.<sup>1</sup>

Most esophageal cancers are found in two distinct histopathological types, i.e. squamous cell carcinoma and adenocarcinoma. Several rare cancers of the esophagus have been described, including adenoid cystic carcinoma. This neoplasm is indistinguishable clinically and prognostically from the more common types of esophageal carcinoma.<sup>2</sup> Here we report a female patient with adenoid cystic carcinoma and the diagnostic work-up.

## CASE REPORT

A woman, 76 years old, came to hospital presented with dysphagia since the last 3 months. She also reported 10 kg weight loss in the past 3 months. Last week, she also felt pain when swallowing food and nausea but not vomiting. On physical examination, the patient was pale and thin. Vital signs were normal. No abnormalities found on chest, abdominal and nodes examination. No liver enlargement.

The problems of the patient were dysphagia, weight

loss, odynophagia, and dyspepsia. At that time the differential diagnoses were malignancy of upper gastrointestinal tract, achalasia, Zenker's diverticle, esophageal spasm and esophageal dysmotility. Routine blood tests were normal except erythrocyte sedimentation rate (ESR) = 105 mm/hr (Westergreen). LDH was 336 U/L.

Patient was asked to undergo upper gastrointestinal tract endoscopy. On examination, the scope could only be inserted into the middle third of the esophagus. There is luminal narrowing but intraluminal mucous appearance was normal (see figure 1).

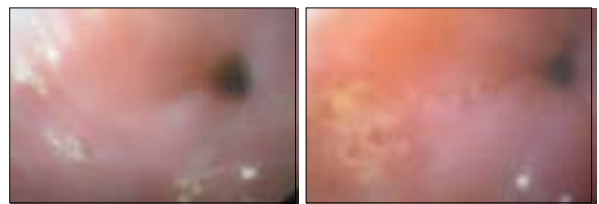


Figure 1. Intraluminal narrowing of the middle third of the esophagus

Esophagography with barium swallow showed a marked stenosis of the middle third of the esophagus (figure 2). Abdominal ultrasonography showed mild hepatomegaly but no mass. CT scanning of the thorax showed a diffuse circular thickness in the middle third of esophagus with luminal stenosis and infiltration to middle mediastinum (figure 3). Other organs were normal. Therefore, it was suspected that the patient had lymphadenopathy (subcarinal) which extend to the upper right hilum.

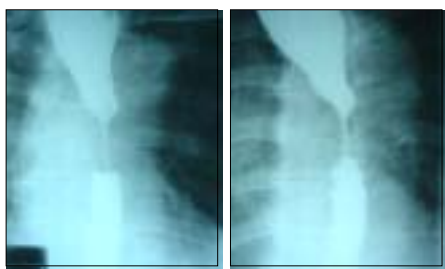

Figure 2. The narrowing of the middle third of the esophagus

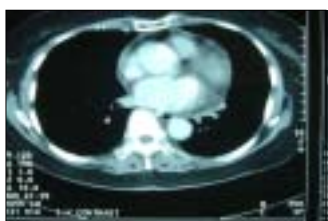

Figure 3. Diffuse circular thickness in the middle third of the esophagus

The next management of the patient was esophageal dilatation with Savary-Guillard dilatator 5 Fr to 14 Fr. Afterwards, the patient was planned to undergo esophagogastroduodenoscopy (EGD) biopsy and esophageal ultrasonography (EUS) guided biopsy or bronchoscopy with subcarinal fine-needle aspiration (FNA) biopsy.

EGD biopsy was done after successful dilatation of the esophagus, but no abnormality found in the mucosa of the esophagus and antrum either macroscopically or histopathologically. Because of limited facility in our hospital and the patient's preference, she was sent to Singapore where she underwent EUS-guided biopsy and bronchoscopy with subcarinal FNA biopsy. Histopathological report from EUS only found non-specific mild reactive changes, which might be due to the under-representative specimens of more deeply seated pathology. In addition, the access for biopsy was difficult due to the mass in the middle third of the esophagus. Histopathology report from subcarinal FNA biopsy confirmed a diagnosis of adenoid cystic carcinoma.

Approximately one month after the patient returned to our hospital, she was re-hospitalized due to progressive dysphagia, decreasing appetite and more weight loss. There was again a narrowing of the middle third of the esophagus and she underwent a second esophageal dilatation to 14 Fr. Magnetic Resonance Imaging (MRI) of the thorax showed a tumor mass in the middle of mediastinum which surrounds and compresses the esophageal lumen. There were multiple vertebral metastases in cervical, thoracic and lumbar vertebrae. Several multiple coin lesions were also seen in the liver. The patient was diagnosed as adenoid cystic carcinoma of the esophagus stage IV

(T<sub>4</sub>N<sub>1</sub>M<sub>1</sub>). Palliative radiotherapy was then scheduled for 12 times at the dose of 250 cGy for each schedule.

After radiation, the patient developed progressive disease with bone, lung, and liver metastases. She received one dose of paclitaxel, but she died 4 months after the completion of radiation therapy or less than 8 months after the first admission.

## DISCUSSION

In this report we present an extremely rare type of esophageal cancer. There is not much publication about adenoid cystic carcinoma of the esophagus. There are only about 60 cases have been published in the literature so far. One large study involving 2,454 esophageal carcinoma treated between 1949 and 1991 found only 30 cases of unusual variants, among which, adenoid cystic carcinoma was found in only 2 patients (0.08%).<sup>3</sup> Data from Japanese Society for Esophageal Disease 1995-1997 found only 3 cases out of 1,948 esophageal cancers (0.15%).<sup>4</sup>

Dysphagia was the only complain of the patient when she came. Most patients with adenoid cystic carcinoma of the esophagus present with dysphagia, but other symptoms might also present such as retrosternal chest pain, nausea and vomiting, and post prandial epigastric fullness.<sup>5</sup> Progressive dysphagia was reported in a patient.<sup>6</sup> The average duration of symptoms is three months before presentation.<sup>7</sup> The disease was also reported to be found after being treated for craniopharyngioma<sup>8</sup> and incidentally during an examination of cholelithiasis.<sup>9</sup>

The narrowing of esophageal lumen seen by endoscopy suggested a tumor or another cause. It is supported by the radiographic examination and CT scanning. However, it was difficult to know whether the mass was originated from the esophagus or lymph node. By endosonography, adenoid cystic carcinoma of the esophagus is isoechoic and primarily submucosal.<sup>5</sup> Most of the reported tumors were found in the middle third of the esophagus.<sup>10,11</sup> Our patient also has sub-mucosal tumor which was located in the middle third of the esophagus.

Histopathological confirmation was difficult due to the presence of esophageal stenosis. EGD and EUS-guided biopsy showed only normal mucosae of the esophagus and antrum. In fact, the tumor might be covered by normal esophageal epithelium, but localized entirely in the submucosal layer.<sup>9</sup> An alternative approach to perform subcarinal biopsy through bronchoscopy has not been reported in previous publications. Most definitive diagnosis could be made only after tumor removal (subtotal esophagectomy).<sup>12</sup> In this report, preliminary biopsy suggested poorly differentiated adenocarcinoma but after resection, it was confirmed to adenoid cystic

carcinoma which histologically contained basaloid cells, cribriform foci, and a certain amount of eosinophilic hyaline substance.

This type of cancer commonly originates in the major salivary glands and respiratory tract.<sup>13</sup> Histologically, it is similar to adenoid cystic carcinoma and mucoepidermoid carcinomas of the salivary glands<sup>14</sup> and it is believed to arise from the submucosal gland.<sup>15</sup> This might explain the appearance of normal mucosa on endoscopy and biopsy.

The disease has more aggressive behavior that differs from the same tumor of the salivary glands and other organ.<sup>16</sup> Surgical resection (esophagectomy) is the standard therapy in localized disease, while radiotherapy and/or chemotherapy is the predominate treatment in the advanced stage. However, all these modality of treatments have no consistent effect on survival. The 5-year survival rate of this malignancy is 5-10% with the median survival time of approximately nine months.<sup>5</sup>

## CONCLUSION

Adenoid cystic carcinoma of the esophagus is a very rare case and might not be diagnosed without advanced modalities. Dysphagia and esophageal narrowing could be the main signs and symptoms, but a histopathological confirmation is required. The delay of diagnosis could affect the patient's management. Unfortunately, the disease characteristically exhibits a clinically aggressive behavior with short survival time. Further studies are needed to elucidate treatment options in this unusual variant of esophageal cancer.

## REFERENCES

1. Parkin DM, Bray F, Ferlay J, Pisani P. Global cancer statistics 2002. *CA Cancer J Clin* 2005;55:74-108.
2. Posner MC, Forastiere AA, Minsky BD. Cancer of the Esophagus. In: DeVita VT, Jr, Hellman S, Rosenberg SA. *Cancer Principles and Practice of Oncology*. 7<sup>th</sup> ed. Philadelphia, Lippincott Williams & Wilkins 2005;p.861-909.
3. Lieberman MD, Franceschi D, Marsan B, Burt M. Esophageal carcinoma. The unusual variants. *J Thorac Cardiovasc Surg* 1994;108:1138-46.
4. Kuwano H, Nakajima M, Miyazaki T, Kato H. Distinctive clinicopathological characteristics in esophageal squamous cell carcinoma. *Ann Thorac Cardiovasc Surg* 2003;9:6-13.
5. Maheshwari S, Erickson RA. Endosonographic evaluation case of esophageal adenoid cystic carcinoma. *Visible Human J Endoscopy* 2005;4:2-4.
6. Kitada H, Yamaguchi K, Takashima M, Tanaka M. Adenoid cystic carcinoma of the esophagus: report of a case. *Surg Today* 1997;27:238-42.
7. Epstein JI, Sears DL, Tucker RS, Eagan JW. Carcinoma of the esophagus with adenoid cystic differentiation. *Cancer* 1984;53:1131-6.
8. O'Sullivan JP, Cockburn JS, Drew CE. Adenoid cystic carcinoma of the esophagus. *Thorax* 1975;30:476-80.

9. Kabuto T, Taniguchi K, Iwanaga T, Terasawa T, Sani M, Tateishi R, et al. Primary adenoid cystic carcinoma of the esophagus: report of a case. *Cancer* 1979;43:2452-6.
10. Pourzand A, Freant L, Levin R, Peabody J, Absolon K. Primary adenoid cystic carcinoma of the esophagus. Report of a case and review of the literature. *J Thorac Cardiovasc Surg* 1975;69:785-9.
11. Cerar A, Jutersek A, Vidmar S. Adenoid cystic carcinoma of the esophagus. A clinicopathologic study of three cases. *Cancer* 1991;67:2159-64.
12. Morisaki Y, Yoshizume Y, Hiroyasu S, Shibata H, Terahata S, Tamai S, et al. Adenoid cystic carcinoma of the esophagus: report of a case and review of the Japanese literature. *Surg Today* 1996;26:1006-9.
13. Karaoglanoglu N, eroglu A, Turkeyilmaz A, Gursan N. Oesophageal adenoid cystic carcinoma and its management options. *Int J Clin Pract* 2005;59:1101-3.
14. Bell-Thomson J, Haggitt RC, Ellis FH Jr. Mucoepidermoid and adenoid cystic carcinomas of the esophagus. *J Thorac Cardiovasc Surg* 1980;79(3):438-46.
15. Allard M, Farkouh E, Atlas H, Paguin JG. Primary adenoid cystic carcinoma of the esophagus. *Can J Surg* 1981;24(405-6).
16. Tonini G, Ragni F, Pezzola D, Balzano R, Villanacci V, Baronchelli C. Cystic adenoid carcinoma of the esophagus. Description of a case and review of the literature. *Minerva Chir* 1995;50:283-7.