

INDONESIAN JOURNAL OF CANCER

Volume 9 • No. 2 • April - June 2015

ISSN 1978 - 3744

Published every 3 month

- Trust Board :** Vice President of “Dharmais” Cancer Hospital
Board of Direction : HRD and Education Director
Medical and Treatment Director
General and Operational Director
Finance Director
- President :** Dr. dr. M. Soemanadi, Sp. OG
Finance : dr. Sariasih Arumdati, MARS
Secretary : dr. Kardinah, Sp. Rad
Artistic : dr. Edy Soeratman, Sp.P
Production Manager : dr. Zakifman Jack, Sp.PD, KHOM
Chief Editor : dr. Nasdaldy, Sp. OG
Editor-in-Chief : dr. Chairil Anwar, Sp.An (Anesthesiologist)
Editor : dr. Bambang Dwipoyono, Sp. OG (Gynecologist)
1. Dr. dr. Fielda Djuita, Sp.Rad (K) Onk Rad (Radiation Oncologist)
2. dr. Kardinah, Sp. Rad (Diagnostic Radiology)
3. Dr. dr. Dody Ranuhardy, Sp.PD, KHOM (Medical Oncologist)
4. dr. Ajoedi, Sp.B, KBD (Digestive Surgery)
5. dr. Edi Setiawan Tehuteru, Sp.A (K), MHA (Pediatric Oncologist)
- Editorial Coordinator :** dr. Edy Soeratman, Sp.P (Pulmonologist)
Peer-Reviewer : 1. Prof. dr. Sjamsu Hidajat, SpB KBD
2. Prof. dr. Errol Untung Hutagalung, SpB , SpOT
3. Prof. dr. Siti Boedina Kresno, SpPK (K)
4. Prof. Dr. dr. Andrijono, SpOG (K)
5. Prof. Dr. dr. Rianto Setiabudy, SpFK
6. Prof. dr. Djajadiman Gatot, SpA (K)
7. Prof. dr. Sofia Mubarika Haryana, M.Med.Sc, Ph.D
8. Prof. Dr. Maksun Radji, M.Biomed., Apt
9. Prof. dr. Hasbullah Thabrany, MPH, Dr.PH
10. Prof. dr. Rainy Umbas, SpU (K), PhD
11. Prof. Dr. Endang Hanani, M.Si
12. Prof. Dr. dr. Moh Hasan Machfoed, SpS (K), M.S
13. Prof. Dr. dr. Nasrin Kodim, MPH
14. Prof. Dr. dr. Agus Purwadianto, SH, MSi, SpF (K)
15. Dr. dr. Aru Sudoyo, SpPD KHOM
16. dr. Elisna Syahrudin, PhD, SpP(K)
17. Dr. dr. Sutoto, M.Kes
18. dr. Nuryati Chairani Siregar, MS, Ph.D, SpPA (K)
19. dr. Triono Soendoro, PhD
20. Dr. dr. Dimiyati Achmad, SpB Onk (K)
21. Dr. dr. Noorwati S, SpPD KHOM
22. Dr. dr. Jacob Pandelaki, SpRad (K)
23. Dr. dr. Sri Sukmaniah, M.Sc, SpGK
24. Dr. dr. Slamet Iman Santoso, SpKJ, MARS
25. Dr. dr. Fielda Djuita, SpRad (K) Onk Rad
26. Dr. Monty P. Satiadarma, MS/AT, MCP/MFCC, DCH
27. dr. Ario Djatmiko, SpB Onk (K),
28. dr. Siti Annisa Nuhoni, SpRM (K)
29. dr. Marlinda A. Yudharto, SpTHT-KL (K)
30. dr. Joedo Prihartono, MPH
31. Dr. Bens Pardamean

Accredited No.: 623/AU2/P2MI-LIPI/03/2015

Secretariat:

Rumah Sakit Kanker “Dharmais” (Pusat Kanker Nasional)
Ruang Indonesian Journal of Cancer Gedung Litbang Lt. 3
Jl. Letjen S. Parman Kav. 84-86, Slipi, Jakarta 11420
Tel. (021)5681570 (ext. 2372) Fax. (021)56958965
E-mail: journal.cancer@gmail.com
Website: www.indonesianjournalofcancer.org

Published by:



Pedoman bagi Penulis

Ruang Lingkup

Majalah ilmiah *Indonesian Journal of Cancer* memuat publikasi naskah ilmiah yang dapat memenuhi tujuan penerbitan jurnal ini, yaitu menyebarkan teori, konsep, konsensus, petunjuk praktis untuk praktek sehari-hari, serta kemajuan di bidang onkologi kepada dokter yang berkecimpung di bidang onkologi di seluruh Indonesia. Tulisan hekdaknya memberi informasi baru, menarik minat dan dapat memperluas wawasan praktisi onkologi, serta member alternatif pemecahan masalah, diagnosis, terapi, dan pencegahan.

Bentuk Naskah

Naskah disusun menggunakan bahasa Indoensia, diketik spasi ganda dengan garis tepi minimum 2,5 cm. Panjang naskah tidak melebihi 10 halaman yang dicetak pada kertas A4 (21 x 30 cm). Kirimkan 2 (dua) kopi naskah beserta CD-nya atau melalui e-mail.

Naskah dikirim ke:

RS. Kanker Dharmais, Ruang Instalasi Gizi, Lt. 1
Jl. S. Parman Kav. 84-86, Slipi, Jakarta 11420
Telp.: 021 581570-71 Ext. 2115 atau 021 5695 8965
Fax.: 021 5695 8965
E-mail: info@indonesianjournalofcancer.org

Judul dan Nama Pengarang

Judul ditulis lengkap dan jelas, tanpa singkatan. Nama pengarang (atau pengarang-pengarang) ditulis lengkap disertai gelar akademiknya, institusi tempat pengarang bekerja, dan alamat pengarang serta nomor telepon, faksimili, atau *e-mail* untuk memudahkan korespondensi.

Abstrak

Naskah tinjauan pustaka dan artikel asli hendaknya disertai abstrak berbahasa Indonesia dan Inggris, ditulis pada halaman pertama di bawah nama dan institusi. Panjang abstrak 100-150 kata untuk naskah panjang atau 50-100 kata untuk naskah pendek.

Tabel dan Gambar

Tabel harus singkat dan jelas. Judul table hendaknya ditulis di atasnya dan catatan di bawahnya. Jelaskan semua singkatan yang dipergunakan. Gambar hendaknya jelas dan lebih disukai bila telah siap untuk dicetak. Judul gambar ditulis di bawahnya.

Asal rujukan table atau gambar dituliskan di bawahnya. Tabel dan gambar hendaknya dibuat dengan program Power Point, Free Hand, atau Photoshop, (menggunakan format jpeg).

Daftar Pustaka

Rujukan di dalam nas (teks) harus disusun menurut angka sesuai dengan urutan pemanipilannya di dalam nas, dan ditulis menurut sistem Vancouver. Untuk singkatan nama majalah ikutilah *List of Journal Indexed in Index Medicus*. Tuliskan sebua nama pengarang bila kurang dari tujuh. Bila tujuh atau lebih, tuliskan hanya 3 pengarang pertama dan tambahkan dkk. Tuliskan judul artikel dan halaman awal-akhir. Akurasi data dan kepastakaan menjadi tanggung jawab pengarang.

Jurnal

1. *Naskah dalam majalah/jurnal*
Gracey M. The contaminated small-bowel syndrome: pathogenesis, diagnosis, and treatment. *Am J Clin Nutr* 1979; 32:234-43.

2. *Organisasi sebagai pengarang utama*
Direktorat Jenderal PPM & PLP, Departemen Kesehatan Republik Indonesia. Pedoman pengobatan malaria. *Medika* 1993; 34:23-8.
3. *Tanpa nama pengarang*
Imaging of sinusitis [editorial]. *Ped Infect J* 1999; 18:1019-20.
4. *Suplemen*
Solomkim JS, Hemsell DL, Sweet R, dkk. Evaluation of new infective drugs for the treatment of intrabdominal infections. *Clin Infect Dis* 1992, 15 Suppl 1:S33-42.

Buku dan Monograf

1. *Penulis pribadi*
Banister BA, Begg NT, Gillespie SH. *Infectious Disease*. Edisi pertama. Oxford: Blackwell Science; 1996.
2. *Penulis sebagai penyunting*
Galvani DW, Cawley JC, Penyunting. *Cytokine therapy*. New York: Press Syndicate of University of Cambridge; 1992.
3. *Organisasi sebagai penulis dan penerbit*
World Bank. *World development report 1993; investing in health*. New York: World Bank; 1993.
4. *Bab dalam buku*
Loveday C. *Virology of AIDS*. Dalam: Mindel A, Miller R, penyunting. *AIDS, a pocket book of diagnosis and management*. Edisi kedua. London: Arnold Holder Headline Group; 1996. H. 19-41.
5. *Attention: konferensi*
Kimura J, Shibasaki H, penyunting. *Recent advanced in clinical neurophysiology*. Presiding dari the 10th International 15-19 Oktober 1995.
6. *Naskah konferensi*
Begston S, Solheim BG, *Enforcement of data protection, privacy and security in medical informatics*. Dalam : Lun KC, Degoultet P, Piemme TE, Reinhoff o, penyunting *MEDINFO 92*. Presiding the 7th World Congress on Medical Informatics: Sep 6-10, 1992; Genewa, Swiss. Amsterdam: North Holland; 1993. H. 1561-5.
7. *Laporan ilmiah*
Akutsu T. *Total heart replacement device*. Bethesda: National Institute of Health, Nation Heart and Lung Institute; 1974 Apr. Report No: NHH-NHL1-69-2185-4.
8. *Disertasi*
Suyitno RH. *Pengamatan vaksinasi dalam hubungannya dengan berbagai tingkat gizi [disertasi]*. Semarang: Fakultas Kedokteran Universitas Diponegoro, 1983.

Publikasi lain

1. *Naskah dalam Koran*
Bellamy C. Gizi bayi adalah investasi masa depan. *Kompas* 26 Januari 2000; hal 8 kolom 7-8.
2. *Naskah dari audiovisual*
AIDS epidemic: the physician's role [rekaman video]. Cleveland: Academy of Medicine of Cleveland, 1987.
3. *Naskah belum dipublikasi (sedang dicetak)*
Connellv KK. *Febrile neutrDpenia*. *J Infect Dis*. In press.
4. *Naskah Jurnal dalam bentuk elektronik*
Morse SS. *Factors in the emergence of infectious disease*. *Emerg Infect Dis* [serial online] Jan-Mar 1995 [cited 5 Jan 1996] 1910: [24 screen]. Didapat dari URL: <http://www.cdc.gov/ncidod/EID/eid.htm>.
5. *Monograf dalam format elektronik*
CDI. *LiniGiiil dermatology illustrated [monograph pada enROM]*. Reeves JRT, Maibach H, CMEAMultimedia Lnnip, produser, edisi ke-2. Versi 2.0. San Diego: CMEA; 1995.
6. *Naskah dari file computer*
Hemodynamics III: the ups and down of hemodynamics [program computer]. Versi 2.2. Orlando (FL); Computerized Educational System; 1993.

INDONESIAN JOURNAL OF CANCER



Volume 9 • No. 2 • April - June 2015

Published every 3 month

Daftar Isi

- 49 – 58 Analisis Drug Related Problems pada Pasien Kanker Padat Stadium Lanjut yang Menjalani Terapi Paliatif di Rumah Sakit Kanker “Dharmais”
(*EMA NILLAFITA PUTRI KUSUMA, RETNOSARI ANDRAJATI, RIZKA ANDALUSIA*)
- 59 – 64 Pregnancy Associated Breast Cancer di Rumah Sakit Ongkologi Surabaya 2006 –2014
(*JACOBUS OCTOVIANUS, SAVITRI KUNTARI, ARIO DJATMIKO*)
- 65 – 70 Ekspresi CTR1 dan ATP7B sebagai Prediktor Respons Kemoterapi Neoadjuvan Cisplatin pada Kanker Serviks IIB
(*PUTU AGUS SUARTA, BRAHMANA ASKANDAR, JULIATI HOOD*)
- 71 – 81 Perbandingan Uji Diagnostik Mesothelin Serum dengan CA-125 pada Kanker Ovarium Tipe Epitel
(*ERI PERDANA USHAN, BRAHMANA ASKANDAR T, BUDIONO*)
- 83– 89 Hubungan antara Ekspresi Hsp 27 dan Hsp 70 Dengan Derajat Diferensiasi dan Angka Ketahanan Hidup Dua Tahun pada Penderita Kanker Endometrium Tipe I Pasca-Pembedahan di RSUD Dr. Soetomo
(*INDRA YULIATI, BRAHMANA ASKANDAR, DYAH FAUZIAH*)
- 89 – 95 A Modified Buttockectomy as a Limb Salvage Procedure in Ischium Osteosarcoma: A Case Report
(*ACHMAD FAUZI KAMAL, YOSHI PRATAMA DJAJA, EVELINA KODRAT, THARIQAH SALAMAH*)

A Modified Buttockectomy as a Limb Salvage Procedure in Ischium Osteosarcoma: A Case Report

ACHMAD FAUZI KAMAL¹, YOSHI PRATAMA DJAJA¹, EVELINA KODRAT², THARIQAH SALAMAH³

¹Department of Orthopaedic and Traumatology Ciptomangunkusumo National Central Hospital/Faculty of Medicine Universitas Indonesia, Jakarta, Indonesia

²Department of Anatomic pathology Ciptomangunkusumo National Central Hospital/Faculty of Medicine Universitas Indonesia, Jakarta, Indonesia

³Department of Radiology Ciptomangunkusumo National Central Hospital/Faculty of Medicine Universitas Indonesia, Jakarta, Indonesia.

Diterima: 5 Maret 2015; Direview: 6 Maret 2015; Disetujui: 20 April 2015

ABSTRACT

Osteosarcoma, which rarely originates from the axial bones such as pelvis, presents a major challenge in limb preservation. We report a 9-year-old girl with osteosarcoma on her buttock. She underwent wide excision "modified buttockectomy" to resect the tumour with sciatic nerve involvement. One year after surgery, she was able to walk and no recurrence was found.

Keywords: buttockectomy, osteosarcoma

ABSTRAK

Osteosarkoma, tulang aksial seperti pelvis jarang sekali ditemukan, dan menjadi tantangan besar dalam upaya penyelamatan ekstremitas. Kami laporkan satu kasus osteosarkoma pada tulang panggul-daerah bokong pada seorang anak perempuan berusia 9 tahun. Pasien menjalani eksisi luas "buttockectomy" yang dimodifikasi untuk mengangkat tumor beserta nervus ischiadikus yang terlibat. Pada pengamatan satu tahun pasca pembedahan, pasien dapat berjalan dan tidak ditemukan tanda-tanda rekurensi.

Kata Kunci: buttockectomy, osteosarkoma

INTRODUCTION

Pelvis is a quite common site for bone tumour in which the pelvic bone tumours constitutes around 10-15% from all bone tumours. Among them, chondrosarcoma, osteosarcoma and Ewing sarcoma are the most common bone tumour found.¹

Osteosarcoma is most commonly found in metaphysis of long bones. It rarely originates from the pelvis or spine. Pelvis only represents 5% of osteosarcoma of all sites. Despite that, the osteosarcoma and other types of bone tumours of the pelvis presents a major challenge in orthopaedic oncology.² These tumours usually present late and their sizes are relatively large with rapid extension to gluteal muscles. In some cases that involves the centrally located pelvic tumour or sacrum, complete resection is not possible. Local control is also hard to achieve and have a poor outcome.³

Buttockectomy is originally the limb salvage procedure indicated for high and low-grade-soft tissue sarcomas of the gluteus maximus which most of them do not extend to the underlying retrogluteal space or involving the femur or sacrum.⁴ We present a case of nine-year-old girl presenting with osteosarcoma of the right ischium

CORRESPONDENCE:

dr. Achamd Fauzi Kamal,
SpOT (K)

Departemen Orthopaedi
dan Traumatologi
FKUI/RSUPN Dr. Cipto
Mangunkusumo Jakarta
Jl. Diponegoro No. 71
Jakarta Pusat.

Email:

fauzikamal@yahoo.com

treated by using limb salvage procedure using modified buttockectomy approach instead of hemipelvectomy or standard utilitarian approach.

CASE

A 6 year old girl was referred to our institution with an enlarging mass on her buttock since 2 years before admission. The mass grew slowly without any pain up until 4 months ago, by which the pain started. Before the pain ensues, she was treated with an alternative medicine (herbs), but there were no improvements and the mass still enlarged. After the pain occurred, she was brought to local general hospital and then was referred to our institution.

Besides the pain and enlarging mass on the buttock, her parents also complained about the patient's inability to stand since about 3 weeks ago due to the pain itself.

On physical examination, there was a hard mass on her right pelvis with a diameter approximately 11 cm (Figure 1). There was no tenderness on the lump or any disturbances on neurovascular function distal to the lump. The movement of the hip joint is limited, but still in the acceptable zone. No limitation was found in the knee and ankle range of motion. The other problem that we found is that the patient has a very low body mass index (malnutrition).

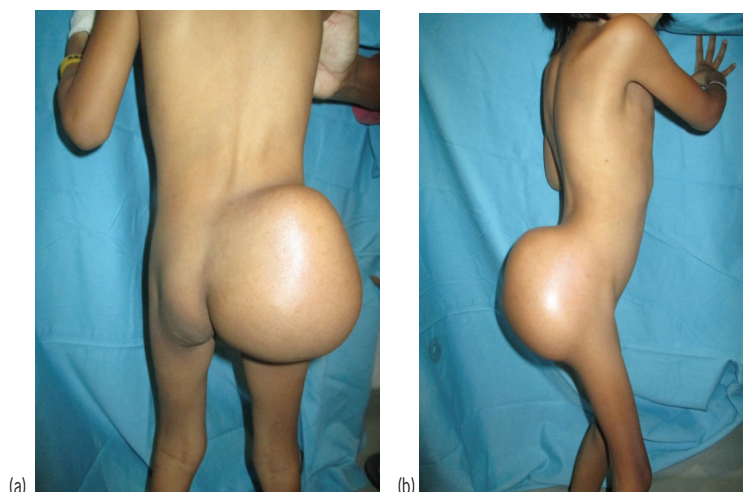

Figure 1: Clinical presentation the mass on the right buttock of the nine year old female patient (AP and lateral)

From the previous hospital, the patient has undergone a series of radiological examination including pelvic plain radiograph and computed tomography (CT) scan (Figure 2). From the pelvic

plain radiograph, we suspected a malignant chondroid tumour on her right ischium with a possible extension to the femoral head.

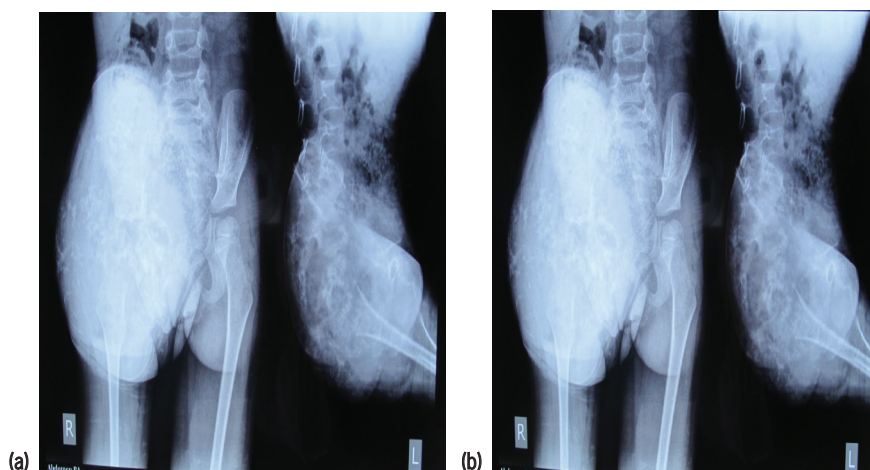

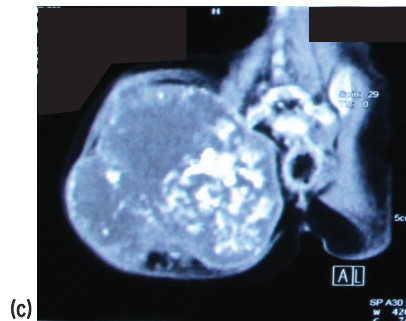


Figure 2: Pelvic X-ray showing a malignant chondroid lesion of the right ischium with the possible involvement of the right femoral head (AP and lateral) (a and b). Axial CT scan showed suggestive a sarcoma on the pelvis (c)

Meanwhile on the abdominal computed tomography scanning, a soft tissue tumour was suspected on her right ischium along with the destruction of the right proximal femur and pelvis. No metastasis was found on the liver or on the lymph nodes. The magnetic resonance imaging (MRI) showed a clearer

image on the pelvis. A malignant chondroid tumour was found on right ischium with soft tissue mass which extended to the gluteus maximus, medius, minimus muscle and piriformis muscle. The mass was also extending to the interior pelvis and involving the ischiadicus nerve [Figure 3].

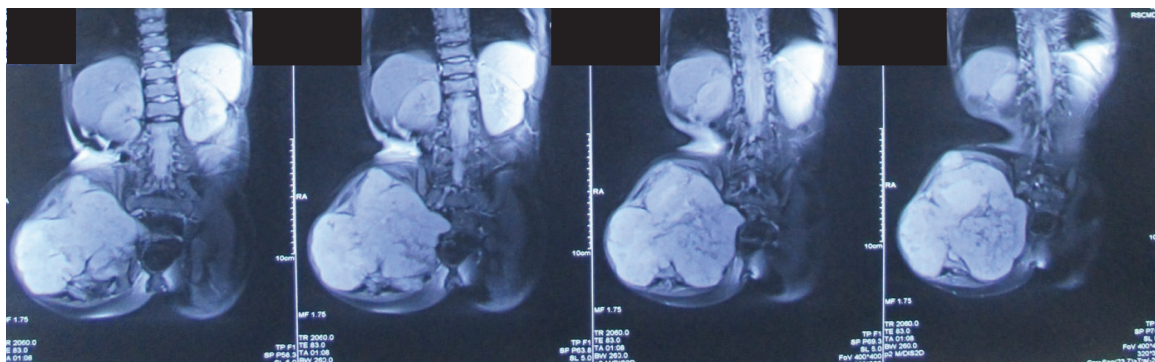


Figure 3: Coronal MRI showing the malignant chondroid lesion of the right ischium along with soft tissue tumour that involved gluteus maximus muscle, medius and minimus along with right piriformis. There was also an extension to intrapelvic organ and sciatic nerve.

Core needle biopsy showed a tendency to chondrosarcoma with differential diagnosis low grade osteosarcoma. Thus, we decided to do a wide excision – buttockectomy followed by adjuvant chemotherapy. A curvilinear incision was performed starting from the posterior iliac crest curving distally following the gluteus maximus muscle until reach the greater trochanter about 3 cm distal. Then the incision was curved posteriorly back to the inner aspect of the thigh to the gluteal fold forming a large posterior skin flap. Identification of the sciatic nerve was taken place. Since the sciatic nerve was unsalvageable we decided to resect it along with the tumour mass [Figure 4].

An osteotomy was performed on the ischium proximally and ilium distally. The fragment on ischium and ilium then was stabilized using ethibone 2.0. The tumour mass then was brought to pathological department and examined. On microscopic view, the tumour mass was consistent with osteosarcoma due to the presence of malignant osteoid and pleomorphic cells [Figure 5].

After surgery, the patient underwent rehabilitation and several chemotherapy session. One year after operation, there was no recurrence and she was able to walk eventhough with a high step page gait [Figure 6].

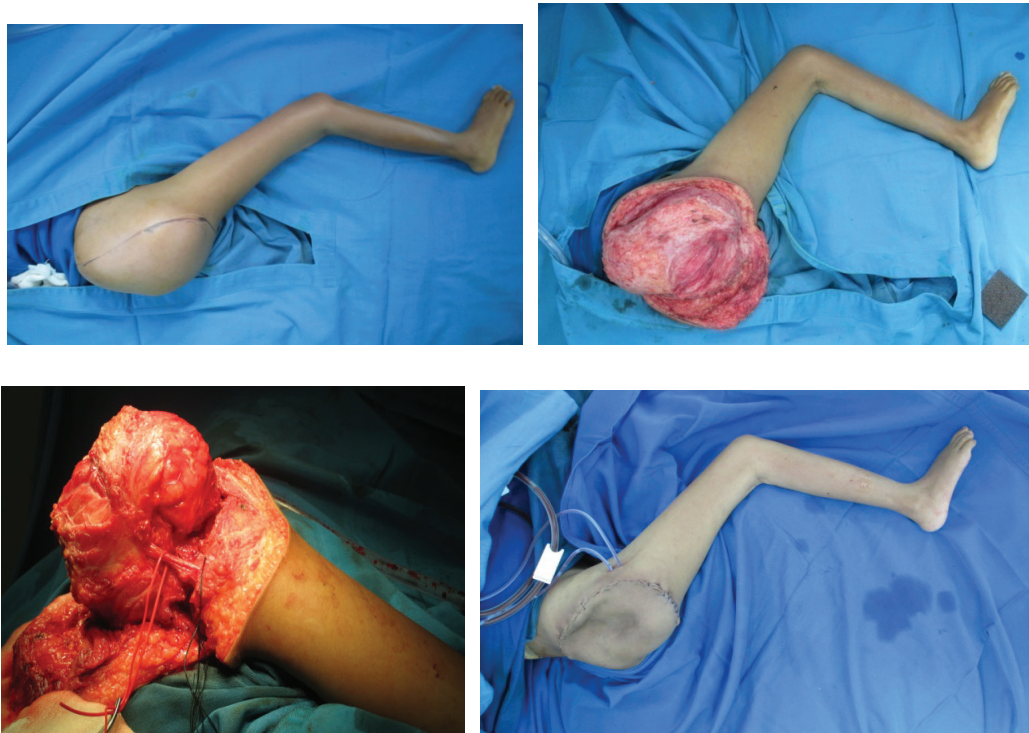

Figure 4: A posterior skin flap was made to expose the gluteus maximus covering the bony tumour mass. Identification of the sciatic nerve which exits from the tumour mass and therefore is unsalvageable

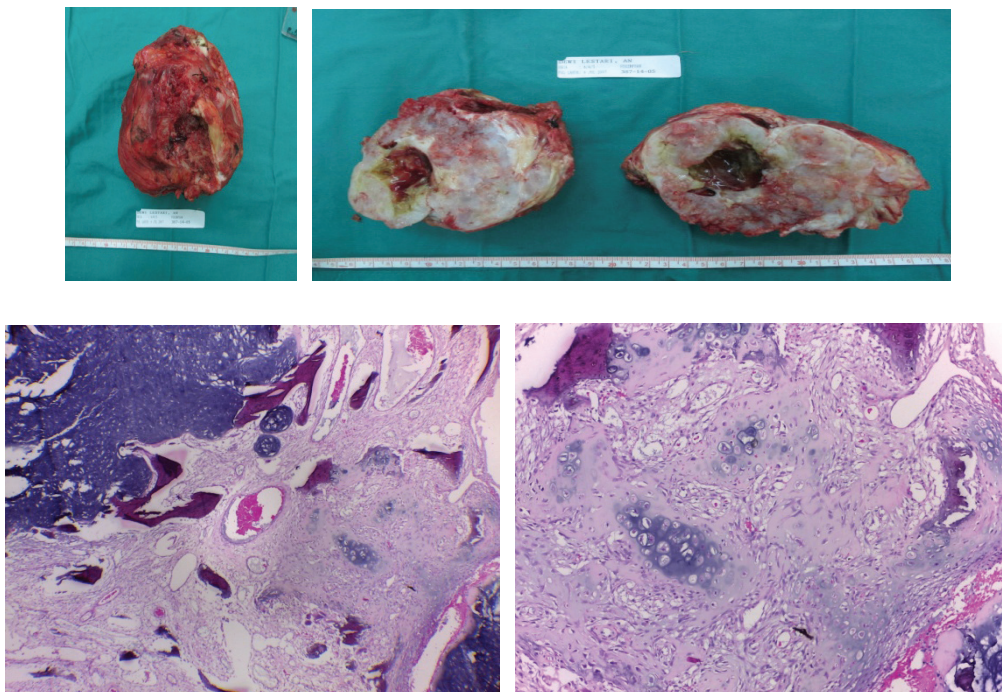


Figure 5: Gross pathology of the tumour showed the lesion is slight chondroblastic which is suggestive to chondrosarcoma. but the existence of malignant osteoid showed that the lesion was osteosarcoma. The histopathology features showed dominant neoplastic cartilaginous component with osteoid production. (H&E 100x , 400x)

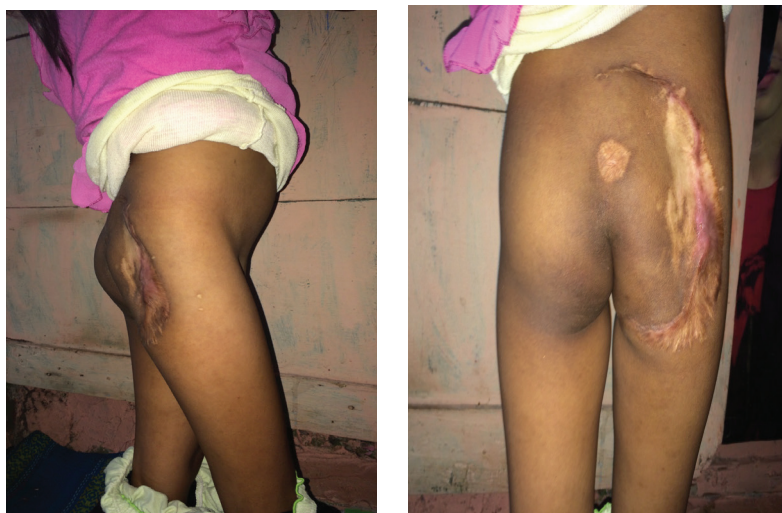

Figure 6: Clinical picture of the patient one year after operation

DISCUSSION

The treatment of osteosarcoma of the pelvis varied from limb ablation (hemipelvectomy) or limb salvage. As mentioned before, limb ablation was the preferred choice until around early 80s. Despite that, it's still regularly performed in cases where it is not possible to obtain both adequate margin of tumour resection and a functional limb.⁵ The advancement of the diagnostic procedure had enabled the surgeons to preoperatively evaluate the extent of the tumour thus made it possible to perform the limb salvage surgery.

Limb sparing procedure combined with adjuvant or neoadjuvant chemotherapy is the gold standard of malignant pelvic bone tumour treatment. Meanwhile some tumours are resistant to chemotherapy, such as chondrosarcoma. It is largely resistant to either conventional chemotherapy or radiation.⁶ In our case, the core biopsy result was suspicious chondrosarcoma or low grade osteosarcoma. Thus, wide en-bloc excision is the treatment of choice.

Meanwhile, there's still some controversies whether the involvement of the sciatic nerve and/or femoral vessels are also the contra-indications for limb salvage surgery. In general, the involvement of one or both of these structures is the contraindication for limb sparing procedure since it will further impair the function of the limb.⁵ A functionally impaired limb however is much preferred rather than an amputation. These patient whose sciatic or femoral nerve has to be sacrificed, will

do well with proper rehabilitation and orthosis.¹ A series of study even reported that a limb salvage procedure has significantly better prognosis compared with patient treated with hemipelvectomy, but it might be related to the extension of the disease that requires a more aggressive treatment.⁷ In this case, the MRI have shown that the sciatic nerve was involved in the tumour and have to be sacrificed along with the tumour. The margin of the tumour itself involves most soft tissues around the gluteus in which the clear margin of tumour was obtainable. Complete resection is always more preferred despite which technique was used to obtain it and salvage surgery is our preference in this case after evaluating the extent of the tumour preoperatively.

Instead of using conventional pelvic resection using the utilitarian approach, we preferred buttockectomy technique due to the extensive involvement of the gluteus maximus muscle. The technique which was proposed by Sugarbaker consist of these following steps: incision of the skin around the tumour, making a skin flap to expose the entire gluteus maximus muscle; identifying the inferior rolled edge of the muscle and traced laterally to its insertion on the iliotibial tract. Then we proceeds counter clockwise starting at inferior aspect of gluteus maximus.⁸

Buttockectomy was initially performed in soft tissue sarcoma cases which occurred in gluteus maximus and was contraindicated if there was an

extension of the sarcoma to the pelvic bone or sacral nerve.⁴ Our approach by using buttockectomy for osteosarcoma of the pelvis was due to the vast soft tissue extension to major muscle in the gluteus region, especially the gluteus maximus. By using the buttockectomy approach, the entire gluteus maximus muscle can be obtained better compared by the utilitarian approach. Our buttockectomy approach is also modified in order to make a pelvic resection type I after the gluteus maximus incision was performed.

Prognosis of this patient remains poor despite the adequate tumour resection and chemotherapy given. Therefore, wide surgical margin is usually hard to obtain. Ham et al⁷, analyzing the factors which influence the prognosis of the pelvis osteosarcoma, mention that positive prognostic factors are complaint less than three months before initial presentation, tumour size less than 8 cm, surgical resection and osteoblastic subtype. Saab et al⁹ mentioned that metastasis at initial presentation contributes to the poor prognosis in pelvic osteosarcoma patients.⁹ In our case, the prognosis remains indeterminate despite the clear surgical margin and no metastasis was found during preoperative examination. The nature of the tumour was chondroblastic thus it might have some resistance to either chemotherapy for systemic control. The size of tumour was also bigger than 8 cm in diameter and late presentation also contributes to the prognosis of our patient.

Wide surgical margin was consistently a significant prognostic factor in osteosarcoma series.^{5,7,10} Ferari et al emphasized the importance of local control in pelvic osteosarcoma due to poor pathological response to chemotherapy and high incidence of chondroblastic variant.¹¹ Complete surgical resection is extremely important in pelvic osteosarcoma, but in the practice, it is very hard to obtain because of the complex anatomy of the pelvis which is associated with the association of the large vessel, nerves and visceral organ with minimal compartmentalization. Even some studies or author regard it is impossible to achieve adequate margin in difficult pelvic area.¹² Furthermore it is not the only deciding factor corresponding to the fact that wider surgical margin in hemipelvectomy does not yield a better survival in several studies.^{5,7,10} Hemipelvectomy itself is reserved for a more advanced tumour or for the potentially curable cases since the devastating functional result and psychological effect to the patients.

Unlike the osteosarcoma of the extremity, the advance of chemotherapy has a limited value in treating pelvic osteosarcoma. Poor response of pelvic osteosarcoma is due to the chondroblastic nature of the tumour.¹³ Recurrence rate was significantly lower in those patients who were treated by wide excision compared with intralesional excision.¹⁴ Five year survival rate of Enneking stage IIB osteosarcoma patients despite surgical and chemotherapy was approximately around 21-40%.^{7,10} Our case have been followed up for about one year, there was no recurrences found clinically eventhough the patient only underwent one series of chemotherapy due to the lack of compliance. As for the functional level, the patient already can performed her daily activities with minimal complaint. In conclusion modified buttockectomy is a considerable approach in treating ischium osteosarcoma with massive soft tissue extension to the buttock.

CONFLICT OF INTERESTS

The authors declare that there is no conflict of interests regarding the publication of this paper.

REFERENCES

1. Bickels J, Malawer M. Overview of pelvic resections: surgical considerations and classification. In: Malawer M, Sugarbaker PH, eds. *Musculoskeletal Cancer Surgery*. The Netherlands: Kluwer Academic Publishers; 2001. p. 204-5
2. Fahey M, Spanier SS, Vander Griend RA. Osteosarcoma of the pelvis: a clinical and histopathological study of twenty-five patients. *J Bone Joint Surg [Am]*. 1992; 74:321-30.
3. Aledavood S A, Amirabadi A, Memar B. Non Surgical Treatment of Sacral Osteosarcoma. *Iran J Cancer Prev*. 2012; 5(1): 46-9
4. Malawer M, Sugarbaker P. Buttockectomy. In: Malawer M, Sugarbaker PH, eds. *Musculoskeletal Cancer Surgery*. The Netherlands: Kluwer Academic Publishers; 2001. p. 410-9
5. Grimer RJ, Carter SR, Tillman RM, Spooner D, Mangham DC, Kabukcuoglu Y. Osteosarcoma of the pelvis. *J Bone Joint Surg [Br]*. 1999;81-B:796-802.
6. Gelderblom H, Hogendoorn PC, Dijkstra SD, van Rijswijk CS, Krol AD, Taminiau AH, Bovée JV. The clinical approach towards chondrosarcoma. *Oncologist*. 2008 Mar;13(3):320-9
7. Ham SJ, Kroon HM, Koops HS, Hoekstra HJ. Osteosarcoma of the pelvis—oncological results of 40 patients registered by The Netherlands Committee on Bone Tumours. *Eur J Surg Oncol*. 2000; 26: 53–60

8. Saab R, Rao BN, Rodriguez-Galindo C, Billups CA, Fortenberry TN, Daw NC. Osteosarcoma of the pelvis in children and young adults: the St. Jude Children's Research Hospital experience. *Cancer* 2005 Apr 1;103(7):1468-74
9. Sugarbaker PH. A surgical technique for buttockectomy. *Surg.* 1992; 91(1):104-7
10. Kawai A, Healey JH, Boland PJ, Lin PP, Huvos AG, Meyers PA. Prognostic factors for patients with sarcomas of the pelvic bones. *Cancer* 1998; 82: 851-9
11. Ferrari S, Palmerini E, Fabbri N, Staals E, Ferrari C, Alberghini M et al. Osteosarcoma of the pelvis: a monoinstitutional experience in patients younger than 41 years. *Tumouri* 2012;98(6):702-708
12. Fuchs B, Hoekzema N, Larson DR, Inwards CY, Sim FH. Osteosarcoma of the Pelvis. Outcome Analysis of Surgical Treatment. *Clin Orthop Relat Res* (2009); 467:510-87.
13. Parades J, Chawla SP, Raymond AK, Carrasco CH, Romsdahl MM, Rich TA. Chemotherapy of osteosarcoma of the pelvis. *Proc Am Assoc Cancer Res.* 1988; 29: A885.
14. Randall RL. Osteosarcoma of the pelvis. In: Conrad EU. Orthopaedic oncology: Diagnosis and treatment. New York: Thieme; 2009: 189-93.

| | |
|----------------------------|----------------------|
| A | |
| ACHMAD FAUZI KAMAL | IJOC 9 ; 2 ; 89 – 95 |
| ARIO DJATMIKO | IJOC 9 ; 2 ; 59 – 64 |
| B | |
| BRAHMANA ASKANDAR | IJOC 9 ; 2 ; 65 – 70 |
| | IJOC 9 ; 2 ; 71 – 81 |
| | IJOC 9 ; 2 ; 83 – 88 |
| BUDIONO | IJOC 9 ; 2 ; 71 – 81 |
| D | |
| DYAH FAUZIAH | IJOC 9 ; 2 ; 83 – 88 |
| E | |
| EMA NILLAFITA PUTRI KUSUMA | IJOC 9 ; 2 ; 49 – 58 |
| ERI PERDANA USHAN | IJOC 9 ; 2 ; 71 – 81 |
| EVELINA KODRAT | IJOC 9 ; 2 ; 89 – 95 |
| I | |
| INDRA YULIATI | IJOC 9 ; 2 ; 83 – 88 |
| J | |
| JACOBUS OCTOVIANUS | IJOC 9 ; 2 ; 59 – 64 |
| JULIATI HOOD | IJOC 9 ; 2 ; 65 – 70 |
| P | |
| PUTU AGUS SUARTA | IJOC 9 ; 2 ; 65 – 70 |
| R | |
| RETNOSARI ANDRAJATI | IJOC 9 ; 2 ; 49 – 58 |
| RIZKA ANDALUSIA | IJOC 9 ; 2 ; 49 – 58 |
| S | |
| SAVITRI KUNTARI | IJOC 9 ; 2 ; 59 – 64 |
| T | |
| THARIQAH SALAMAH | IJOC 9 ; 2 ; 89 – 95 |
| Y | |
| YOSHI PRATAMA DJAJA | IJOC 9 ; 2 ; 89 – 95 |

Ucapan Terimakasih Mitra Bestari

Redaksi Indonesian Journal of Cancer menyampaikan ucapan terimakasih dan penghargaan setinggi-tingginya kepada para Mitra Bestari atas Kontribusinya pada penerbitan Indonesian Journal of Cancer Volume 9, edisi no. 2 tahun 2015.

Prof. Dr. dr. Rianto Setiabudy, SpFKD
Departemen Farmakologi FKUI/RSUPN
Dr. Cipto Mangunkusumo Jakarta

Prof. dr. Errol Untung Hutagalung, SpB, SpO
Departemen Orthopedi dan Traumatologi FKUI-RSUPN
Dr. Cipto Mangunkusumo Jakarta

Prof. Dr. dr. Andrijono, SpOG (K)
Departemen Obstetri & Ginekologi, Divisi Ginekologi-Onkologi FKUI-RSUPN
Dr. Cipto Mangunkusumo Jakarta

Dr. dr. Dimiyati Achmad, SpB Onk (K)
Departemen Bedah Divisi Bedah Onkologi FK-UNPAD/
RS. Dr. Hasan Sadikin Bandung