

Effect of Allicin for Re-epithelialization During Healing in Oral Ulcer Model

Renny Ayu Novianty
Bernadetta Esty Chrismawaty
Goeno Subagyo

*Department of Oral Medicine, Faculty of Dentistry,
Universitas Gadjah Mada
Yogyakarta, Indonesia*

*E-mail: esti_chrismawaty_fkg@ugm.ac.id
Received August 15, 2010; Accepted December 10, 2010*

Abstract

Allicin (diallyl thiosulfinate) is the main component of fresh garlic with multi-bioactivities as therapeutic agent. Recently, allicin is being proposed as alternative therapy for aphthous ulcer. The purpose of this study was to determine the effect of topical allicin in aqueous garlic extract on re-epithelialization during healing of acetic acid induced oral ulcer model. Thirty males SD rats aged 2 months were equally divided into two groups as experimental and control groups. After sedated with 0.2 ml intramuscular Ketamine injection, ulcer model was made by applying 99.5% glacial acetic acid-moistened paper disc on rat buccal mucosa. This would generate an immediate necrotic tissue, which produced a single crateriform ulcer in each of the experimental rats for the next two days. In the experimental group, one drop of allicin was applied twice daily onto the lesion. Three rats in each group were sacrificed on days 2, 3, 6, 9 and 12 after induction and were recorded as H₀, H₁, H₄, H₇ and H₁₀ groups, respectively. The tissue samples from buccal mucosa were processed for Hematoxylin Eosin (HE) staining, and then evaluated histologically. Re-epithelialization was assessed by measuring the thickness of the epithelium using an ocular micrometer under a light microscope. Data were analyzed statistically by Independent t-test with significant p-values of <0.05 (95%). Based on histological findings and trend graphs, it can be concluded that the topical application of allicin can accelerate re-epithelialization of ulcer healing process. This study suggests that allicin in aqueous garlic extract could be developed as therapeutic agent for aphthous ulcer.

Keywords: Allicin, oral ulcer model, re-epithelialization, ulcer healing process, oral ulcer model.

Introduction

Oral or mouth ulcers are a common pathological condition found in the oral cavity. Greenberg and Glick¹ defined an ulcer as a defect in the epithelium; which is a well-circumscribed depressed lesion over which the epidermal layer has been lost. Prevalence of oral ulcers is estimated at more than 25 percent of the population worldwide². Oral ulcers can be

caused by various factors, although in some cases, the etiology cannot be identified. Several factors have been known to cause oral ulcers include trauma as traumatic injury, chemical and thermal trauma; various infectious agents; drugs or medications; hormonal disorders, nutrient deficiencies and²⁻⁴ can be a feature of various systemic disorders including inflammatory bowel disease⁵.

The management of oral ulcers often necessitates a comprehensive approach occasionally involving more than one subspecialty⁶, which are aimed at management of underlying disease⁶⁻⁹. The treatments of oral ulcers depend on the etiology which is intended primarily for symptom management by suppressing inflammatory responses, as well as reducing frequency of recurrences or avoiding the occurrence of new ulcers^{7,8,10}. It can be obtained through non-therapeutic and therapeutic management. Non-therapeutic treatment includes supportive measures with attention to immaculate oral hygiene, prevent trauma or avoid certain foods. Therapeutic treatment options comprise anti-inflammatory agents, antibiotics, immunomodulatory agents and others¹⁰. It can be administered topically or systemically. However the use of topical medications is the most popular method^{1,9}, with corticosteroid as drug of choice⁹.

The existence of some therapies, such as topical corticosteroids, mouth rinses, antibiotics, anesthetic gel or pastilles and immunomodulatory agent supports the fact that there is currently no uniform therapeutic preparation in managing mouth ulcers¹¹. The usage of herbal medicine is widespread worldwide and growing with the increasing number of herbal products as complementary or alternative treatment¹². Garlic is one of the herbal medicines that are being developed as therapeutic agents¹³.

Allicin is an unstable organosulfur compounds, which is immediately formed through enzymatic reactions of alliin by alliinase when garlic is crushed^{14,15}. It has multiple bioactive properties, such as anti-inflammatory, anti-thrombotic, anti-microbial, anti-atherosclerotic, anti-cancer, serum lipid lowering activity¹⁴, immunomodulatory agent and antioxidant, which are expected to accelerate the healing process of mouth ulcers and prevent recurrence⁹. Wound healing is exceedingly controlled and well-coordinated process that involves inflammation, cell proliferation, matrix deposition and tissue remodeling^{16,17}. Wound healing process involves several parameters, such as inflammatory cell count, angiogenesis assessment, re-epithelialization, fibroblast or collagen fiber density, and so on. In this study, we investigated the effect of topical allicin in aqueous garlic extract on re-epithelialization during healing of rat acetic acid induced oral ulcer model.

Materials and Methods

Allicin Preparation

Garlic bulbs (*Allium sativum* L.) were purchased from traditional market (Yogyakarta, Indonesia). Dried garlic bulbs (about 250 g) were blended with 2000 ml of water as solvent, prepared for maceration procedures for 24 hours, afterward it was filtered three times with a Buchner funnel which fitted with filter paper. The end result of maceration was collected into a porcelain cup and heated on water bath while stirring. Furthermore, 50 grams of dried garlic extract was dissolved in 500 ml of sterile distilled water to obtain a concentration of 10%. Afterward the dilution was tested by thin layer chromatography (TLC) methods to determine the existence of an active ingredient of allicin in aqueous garlic extract. The test parameters was disulfide group (-SS). It is considered positive for the existence of allicin if there was a peak referred to disulfide group in the report form. The solution of aqueous extract of garlic was stored in sterile dark bottles at a temperature of 4°C. It can be used for more than 3 months and remain in stable condition¹⁴.

Experimental Procedures

Sprague Dawley rats weighing 180-250 g were divided randomly into 2 groups of 15 animals each. The study began after receiving approval from the Ethics Committee for Health and Medical Research of The Faculty of Medicine, Universitas Gadjah Mada for animal care and experimental protocol. The rats were fed with a standard laboratory diet and water *ad libitum*. An oral ulcer model was made by modification based on Slomiany and Fujisawa^{8,18}. After the rats were sedated with Ketamine (0.2 ml) injection, a 4 mm filter paper disc (Whatman No. 1) soaked in glacial acetic acid (99.5%) was applied to the left buccal mucosa of the rats for 40 seconds. This would generate an immediate tissue necrosis, which then produce a single crateriform ulcer in each of the experimental rats 2 days later. The ulcer normally would remain up to 14 days⁸.

In the experimental group, one drop of allicin was applied twice daily to the lesion. Three rats in

each group were sacrificed on days 2, 3, 6, 9 and 12 after induction and were recorded as H_0 , H_1 , H_4 , H_7 and H_{10} groups, respectively. The tissue samples from buccal mucosa from the ulcer area along with its margin were excised and processed for Hematoxylin Eosin (HE) staining, and then evaluated histologically. Re-epithelialization was assessed by measuring the thickness of the epithelium using an ocular micrometer under a light microscope with 40x magnification. Data were analyzed statistically by Independent t-test with significant p-values of <0.05 (95%).

Results and Discussion

In this study, oral ulcer model was used to determine the effectiveness of topical application of allicin from aqueous extract of garlic (*Allium sativum* L.) on re-epithelialization during healing process of oral ulcer. Re-epithelialization is one of a sequence complex in the wound healing process, which is achieved through the course of migration, proliferation and differentiation of keratinocytes¹⁹. The sequences of re-epithelialization during ulcer healing process were assessed by measuring the thickness of epithelial layer on two opposite edges of the ulcer. The results are shown in Table 1 and Figure 1. There was no epithelial thickness difference between control and experimental groups in period H_0 ($p>0.05$), and measurement results in the next period showed a highly significant differences of the epithelial thickness between period H_1 to H_{10} ($p<0.01$).

Statistically, t-test analysis showed no significant difference in epithelial thickness between control and experimental groups ($p>0.05$) at the period of H_0 (Table 1). This is because the topical application of allicin was started on the day-2 post-induction of acetic acid glacial, wherein this period was considered as the first day of ulcer (period H_0) with both groups had the same characteristic of oral ulcers. On the next observation, the epithelial thickness between both control and experimental groups showed significant differences from the period of H_1 through H_{10} ($p<0.05$) as shown in Table 1.

On histopathology observations, both control and experimental groups in period H_0 showed severe damage of the epithelial layer accompanied by cellular changes, such as infiltration of inflammatory cells. In the period H_1 , control group showed no change in the appearance of epithelial layer with scattered inflammatory cell infiltration. Meanwhile, the experimental group showed the new epithelial layer and the wound started to close (Figure 1, arrow). The epithelial layer of the tissue specimen in the experimental group at period H_4 had completely closed and showed the formation of rete pegs (connective tissue papillae) better than the control group in the same period. The thickness of the epithelial layer in the experimental group at period of H_7 became thinner and continued until entering the period of H_{10} , whereas in the control group, the epithelial layer appeared thickened. The control group also showed widening formation of rete pegs.

Table 1. Means and SD of epithelial thickness from each group.

Period	N	Mean \pm SD	
		Control	Allicin
H_0	3	3.70 \pm 6.35	3.70 \pm 4.80
H_1	3	3.85 \pm 2.44	22.22 \pm 13.82**
H_4	3	159.85 \pm 73.17	272.89 \pm 85.56**
H_7	3	276 \pm 140.82	162.96 \pm 33.96*
H_{10}	3	314.52 \pm 128,81	148.3 \pm 23.23**

* $p<0.05$, ** $p<0.01$, significantly different from the control group.

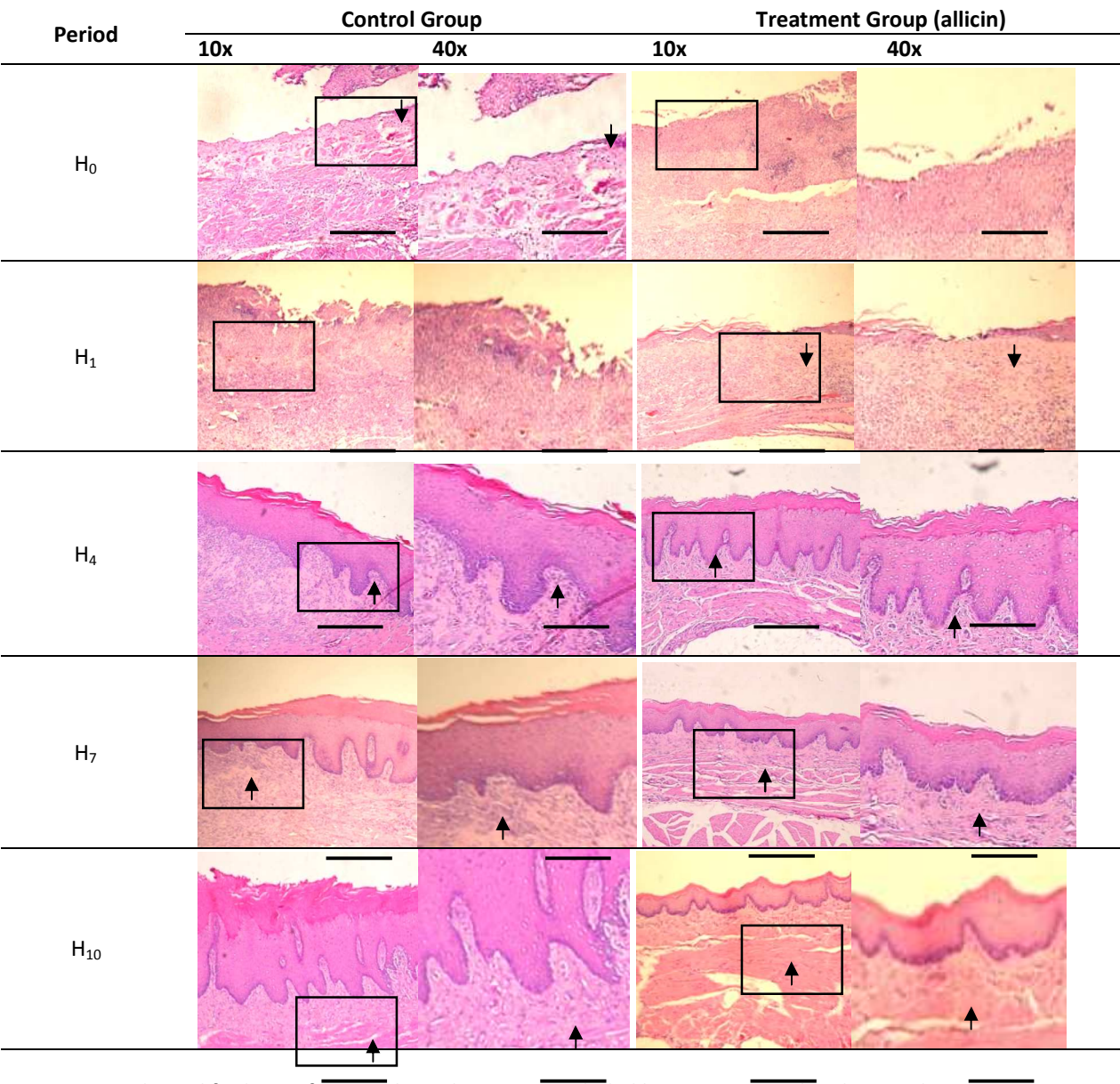


Figure 1. Histological findings of SD rats buccal mucosa epithelial between control and treated groups.

The new epithelial layer in the experimental group had begun to appear along the margin of the ulcer during the period of H₁, while the other groups remained damaged (Figure 1). This probably due to an ability of allicin to immediately initiate the healing process. As an anti-inflammatory agent, allicin started an immunomodulatory activity and accelerated the process of inflammation. The ability of allicin to penetrate the phospholipids membrane

contributes to its bioactivity²⁰. The loss of epithelial continuity that occurs during ulceration facilitates allicin to penetrate easily into the wound area and release its various bioactive contents.

The process of inflammatory is essential to generate mediators that further will initiate the repair phase^{21,22}. However the excessive inflammatory response can lead to cell death and alter the composition of the extracellular matrix.

This can occur as a result from the failure of the re-epithelialization²³. The ability of allicin as an anti-inflammatory and immunomodulatory agent happens via negative feedback mechanism. Whereby allicin can spontaneously reduce and suppress TNF- α , and the next stimulates secretion of IL-1, IL-6, IL-8, and leukotriene by lowering the levels of mRNA and inhibits activation of nuclear factor- κ B (NF κ -B). Allicin is also capable of stimulating the production of IL-10 which in turn would suppress the production of TNF- α and IL-2, IL-6, IL-12 by T cells and ICAM. All of the cytokines and chemokines play a role in the regulation of cellular responses¹¹. Therefore allicin is capable to suppress the excessive inflammatory process. Through that way, the next phase of tissue healing may occur more quickly and favorable.

On subsequent observations, it appeared that epithelial thickness on experimental group reached its peak during the period of H₄ and then decreased from the period of H₇ and lasted during the period of H₁₀, at the same time, the epithelium on control group still remain thickened in the period of H₁₀ (Figure 1 and 2). Furthermore, the arrangement of rete pegs on experimental group better structured than the control group (Figure 1). The formation of rete pegs showed better re-epithelialization in order to re-establish normal epithelial tissues²⁴, as it forms from an elongated papillary epithelial toward the contact area, so that the surface of epithelium, innervations and vascularization within connective tissue will increase to support the optimal epithelial growth²⁵.

The depletion of the epithelial thickness of the experimental group started in the period of H₇, this explained that the healing process has entered a stage of maturation and remodeling, meanwhile in the control group the epithelial layer still continued to thicken until the end of period of H₁₀. This was suspected that the healing process in the control group was still running on proliferative phase. This result is consistent with the other research, which reported that in the allicin group significantly showed lower density of inflammatory cells while fibrocyte and fibroblast density is higher than other groups on the day 7 after wounding²¹. In this study,

six days after acetic acid glacial induction (in the period of H₄) the thickness of the epithelium of the experimental group was showed significantly higher than the control group. It is indicate that the experimental group had entered the healing process, so that the next stages of proliferation, maturation and remodeling can occur more quickly.

Prolonged inflammatory response may inhibit wound healing process²⁶, because the emergence of proliferative growth factors such as TGF- β was inhibited. TGF- β is a growth factor which control the regulatory function of fibroblasts, is also be able to increase transcription of fibroblast genes to synthesize collagen¹⁶. Synthesis and deposition of collagen by fibroblasts are critical parts during the proliferative phase¹⁷. The proliferation phase will ended after enough collagen is produced along with the decreased of fibroblasts density²⁷. In this study, topical application of allicin showed that inflammatory process in the experimental group occurs faster than in the control group. Thus, the appearance of growth factors is crucial for the optimal healing process and rapidly re-epithelialization. The ability of allicin as an antimicrobial defense plays a role in circumventing the wound from infection and keeping the epithelial tissue from excessive response. The organosulfur components contained in garlic, such as alliin, diallylsulfides, and allicin are also known as molecules that have the potential to protect the body from the danger of free radicals by modulating the activity of GSH oxidation and inhibiting reduction of NF κ -B activation in T cells²⁸.

Moreover, allicin can increase cellular antioxidant enzyme, so that it can restore the impaired antioxidant defense system in patients with aphthous ulcer and preventing the recurrences¹¹. Activities that contribute directly to the mechanism of allicin in modulating keratinocyte cells until now have not yet been explained in detail. Even so, based on the overall results, it was indicated that the re-epithelialization in experimental group with allicin occurs more rapidly. The existence of multiple bioactive allicin in aqueous extract garlic can repair and restore oral tissue continuity as the novel state; hence the healing process of oral ulcers can occur faster.

Conclusion

Based on histological findings and statistical analysis, it can be concluded that the topical application of allicin can accelerate re-epithelialization of ulcer healing process. This study suggests that allicin in aqueous garlic extract could be developed as an alternative therapeutic agent for aphthous ulcer.

Acknowledgment

This research was supported by Dana Masyarakat 2009–Faculty of Dentistry, Universitas Gadjah Mada, Yogyakarta.

References

- Greenberg MS, Glick M. 2003. *Burket's Oral Medicine Diagnosis and Treatment*, 10th ed. BC Decker Inc.
- Paleri V, Staines K, Sloan P, Douglas A, Wilson J. 2010. Evaluation of oral ulceration in primary care. *BMJ* 340: 1234-9.
- Wood NK, Goaz PW. 1997. *Differential Diagnosis of Oral and Maxillofacial Lesions*, 5th ed, Mosby Inc.
- Regezi JA, Scuibba JJ, Jordan RCK. 2003. *Oral Pathology: Clinical-Pathologic Correlation*, 4th ed. Saunders.
- Leão JC, Gomes VB, Porter S. 2007. Ulcerative lesions of the mouth: An update for the general medical practitioner. *Clinics* 62(6):769-80
- Bruce AJ, Rogers III RS. 2003. Acute oral ulcers. *Dermatol Clin* 21: 1-15.
- Bricker SL, Langlais RP, Miller CS. 1994. *Oral Diagnosis, Oral Medicine, and Treatment Planning* 2nd ed. Lea & Febiger.
- Fujisawa K, Miyamoto Y, Nagayama M. 2003. Basic fibroblast growth factor and epidermal growth factor reverse impaired ulcer healing of the rabbit oral mucosa. *J Oral Pathol Med* 32: 358-66.
- Barrons RW. 2001. Treatment strategies for recurrent oral aphthous ulcers. *Am J Health-Syst Pharm* 58: 41-53.
- Srinivas-Rao P. 2010. Recurrent Aphthous Stomatitis: A Review. *J Orofac Sci* 2(3): 60-5.
- Jiang XW, Hsu W, Mian FI. 2008. A new therapeutic candidate for oral aphthous ulcer: allicin. *Medical Hypotheses* 71: 897-9.
- Palombo EA. 2009. Traditional medicinal plant extracts and natural products with activity against oral bacteria: potential application in the prevention and treatment of oral diseases. *eCAM*: 1-15. Available at <http://ecam.oxfordjournals.org> on March 12, 2010.
- Raskin I, Ribnicky DM, Komarnytsky S, Ilic N, Poulev A, Borisjuk N, Brinker A, Moreno DA, Ripoll C, Yakoby N, O'Neal MJ, Cornwell T, Pastor I, Fridlender B. 2002. Plants and human health in the twenty-first century. *Trends in Biotechnology* 20: 522-31.
- Shadkchan Y, Shemesh E, Mirelman D, Miron T, Rabinkov A, Wilchek M, Osheroov N. 2004. Efficacy of allicin, the reactive molecule of garlic, in inhibiting *Aspergillus* spp. in vitro, and in a murine model of disseminated aspergillosis. *Journal of Antimicrobial Chemotherapy* 53: 832-6.
- Tattelman E. 2005. Health effects of garlic. *Am Fam Physician* 72: 103-6.
- Diegelmann RF, Evans FC. 2004. Wound healing: an overview of acute, fibrotic and delayed healing. *Bioscience* 9: 283-9.
- Enoch S, Moseley R, Stephens P, Thomas DW. 2008. The oral mucosa: a model of wound healing with reduced scarring. *Oral Surgery* 1: 11-21.
- Slomiany BL, Piotrowski J, Slomiany A. 1999. Suppression of caspase-3 and nitric-oxide synthase-2 during buccal mucosal ulcer healing: effect of chronic alcohol ingestion. *Biochem Mol Biol Int* 48: 121-5.
- Shai A, Maibach HI. 2005. *Wound Healing and Ulcers Of The Skin: Diagnosis And Therapy-The Practical Approach*. Springer.
- Miron T, Rabinkov A, Wilchek L. 2000. The mode of action of allicin: its ready permeability through phospholipid membranes may contribute to its biological activity. *Biochem Biophys Acta* 1463: 20-30.
- Sardari K, Mirshashi A, Maleki M, Aslani MR, Najari Barjasteh M. 2006. Effect of topical allicin on second-intention wound healing in dogs (histological aspects). *Comp Clin Pathol* 15: 98-102.
- Usui ML, Underwood RA, Mansbridge JN, Muffley LA, Carter WG, Olerud JE. 2005. Morphological evidence for the role of suprabasal keratinocytes

- in wound re-epithelialization. *Wound Rep Reg* 13: 468-79.
23. Kumar V, Cotran RS, Robbins SL. 1999. *Basic Pathology* 8th ed. WB Saunders Co.
 24. Ten Cate AR. 1998. *Oral Histology: Development, Structure and Function* 5th ed. Mosby-Year Book Inc.
 25. Avery JK. 1992. *Essentials Of Oral Histology and Embryology: A Clinical Approach*. Mosby- Year Book.
 26. Dubay DA, Franz MG. 2003. Acute wound healing: the biology of acute wound failure. *Surgical Clinics of North America* 83(3): 1-17.
 27. Harrison JW. 1991. Healing of surgical wounds in oral mucoperiosteal tissues. *J Endodont* 17(8): 401-8.
 28. Tapiero H, Townsend D, Tew KD. 2004. Review: organosulfur compounds from alliaceae in the prevention of human pathologies. *J Biomedicine & Pharmacotherapy* 58: 183-93.