

RESEARCH ARTICLE

Accuracy of Core Needle Biopsy for Musculoskeletal Lesion in Cipto Mangunkusumo Hospital Jakarta

Peter Giarso,¹Achmad Fauzi Kamal,^{1*} Nuryati Chairani Siregar²

¹Department of Orthopaedic & Traumatology,

²Department of Anatomic Pathology, dr. Cipto Mangunkusumo Hospital-FM Universitas Indonesia

*Correspondence: fauzikamal@yahoo.com

Diterima: 8 Desember 2015; Disetujui 2 Maret 2016

DOI: 10.23886/ejki.4.5901.8-14

Abstract

Core needle biopsy (CNB) is considered to have similar results with open biopsy in accuracy and already becomes a routine procedure to establish the diagnosis of musculoskeletal lesion. However, the accuracy of CNB for musculoskeletal lesion in Indonesia has not been reported. The aims of the study to know the accuracy of CNB for musculoskeletal tumor diagnoses. From January 2011 to August 2015, all patients with musculoskeletal lesion in dr. Cipto Mangunkusumo Hospital underwent CNB and subsequently, tumour excision were identified and enrolled. Diagnostic accuracy was evaluated for both histopathology and clinicopathological conference (CPC) conclusion. A total of 86 samples were enrolled in this study. The accuracy of CNB compared to post excision histopathology is 74.4%. With CPC conclusion, the accuracy is 83.7% with sensitivity 98%, specificity 59% ($p < 0.001$). The accuracy of CNB after immunohistochemistry was increased from 74.4% to 84.9% with sensitivity 98%. The accuracy of CNB was 97.1% and 82.7% for benign lesion and malignant lesion respectively ($p < 0.01$). The accuracy of CNB to differ and to confirm diagnosis as primary or metastatic lesion was 97.2% and 85.7% respectively ($p < 0.001$). In conclusion, CNB is a reliable diagnostic method to establish musculoskeletal tumor diagnoses. CPC significantly provides better accuracy rate of CNB.

Keywords: core needle biopsy; musculoskeletal lesion; clinical pathology conference

Akurasi Biopsi Jarum Inti untuk Mendiagnosis lesi Muskuloskeletal di Rumah sakit Cipto mangunkusumo, Jakarta

Abstrak

Biopsi jarum inti dianggap memiliki akurasi yang sama dengan biopsi terbuka dan menjadi prosedur rutin untuk menegakkan diagnosis lesi muskuloskeletal. Meskipun demikian, belum ada laporan akurasi penggunaan biopsi jarum inti untuk lesi muskuloskeletal di Indonesia. Tujuan studi ini adalah mendapatkan nilai ketepatan diagnosis biopsi jarum inti pada lesi muskuloskeletal. Dari bulan Januari 2011 hingga Agustus 2015, semua pasien dengan lesi muskuloskeletal di RS dr. Cipto Mangunkusumo menjalani biopsi jarum inti, dilanjutkan dengan eksisi tumor dan identifikasi. Akurasi diagnostik dihitung dengan membandingkan histopatologi biopsi jarum inti dengan histopatologi pasca eksisi tumor dan didiskusikan sebagai hasil akhir histopatologi pada clinico-pathological conference (CPC). Sebanyak 86 sampel diikutsertakan dalam penelitian ini. Perbandingan akurasi biopsi jarum inti dengan eksisi tumor adalah 74,4%. Dengan kesimpulan CPC, akurasi biopsi jarum inti 83,7% dengan sensitivitas 98%, spesifisitas 59% ($p < 0,001$). Akurasi setelah pemeriksaan dengan imunohistokimia meningkat menjadi 84,9% dengan sensitivitas 98%. Akurasi untuk membedakan lesi jinak adalah 97,1% dan lesi ganas 82,7% ($p < 0,001$). Akurasi dalam membedakan lesi primer adalah 97,2% dan lesi metastasis 85,7% ($p < 0,001$). Biopsi jarum inti adalah metode biopsi yang dapat dipercaya, karena memberikan akurasi diagnosis tumor muskuloskeletal yang kurang lebih sama dengan biopsi terbuka. Untuk memperoleh hasil yang lebih baik hasil biopsi jarum inti harus dibicarakan dalam CPC dan dilakukan pemeriksaan imunohistokimia sesuai indikasi. Disimpulkan biopsi jarum inti memberikan hasil yang dipercaya untuk mendiagnosis lesi muskuloskeletal. CPC meningkatkan akurasi biopsi jarum inti pada lesi muskuloskeletal.

Kata kunci: biopsi jarum inti; lesi muskuloskeletal; clinico-pathological conference

Introduction

Open biopsy has long been regarded as the gold standard for establishing diagnosis of musculoskeletal lesions.¹⁻³ However, recent studies show that core needle biopsy (CNB) has a similar diagnostic accuracy with open biopsy. The accuracy of CNB compared with open biopsy is ranging from 70% to 99%, because of the improvement in biopsy and histopathological techniques.⁴⁻⁷ In comparison to open biopsy, the CNB procedure is faster, less invasive, less expensive, more comfortable for the patient, and has a lower risk of morbidity and infection, and also prevents the spreading of malignant cells.^{4,7-8} Therefore, many studies have recommended CNB to establish musculoskeletal tumor diagnosis. In addition, some centers in the world mentioned that CNB as their standard procedure was sufficient to confirm final diagnosis.^{4,5,7-10}

The CNB has been used as a diagnostic tool in dr. Cipto Mangunkusumo National Hospital (CMNH) since 2011, to be confirmed in the clinicopathological conference (CPC), for final diagnosis. Accuracy rate of CNB for diagnosis of musculoskeletal tumors in CMH and Indonesia has not been reported. Therefore, the study about accuracy of CNB compared with final surgical specimen (histopathologic diagnosis of post-excisional tumor) needs to be done.

Methods

This study was a descriptive analytical study with cross-sectional design. Materials used were secondary data obtained from medical records in CMH from January 2011 to August 2015 including oncology registry book of the Department of Orthopaedic and Traumatology as well as data from Department of Anatomic Pathology. The final diagnosis which was not classified by international classification disease for oncology (ICD-O) from the WHO or ICD-10 were excluded.

CNB was conducted by two experienced orthopaedic surgeons using semi automatic cutting needle size 14. The needle was inserted from one point in the skin into intra-tumoral tissue in multiple directions. We took a minimum of five tissue

samples which were directly fixed with formalin 10% to be further examined based on haematoxylin and eosin staining standard.

Lesion that needs computed tomography (CT) guide is usually due to its difficult location or small lesion such as pelvic and sacral bone tumors. The CT guided CNB was conducted also by similar orthopaedic surgeon in Radiology Department CMH. Should an immuno-histochemical staining was necessary to confirm diagnosis, it might be performed upon decision during the CPC forum not by the decision of an expert. Every musculoskeletal tumor diagnosis should be discussed and established among orthopaedic surgeon, radiologist, and pathologist as the main participants of CPC.

Dependent variable in this study was histopathologic diagnosis of post-excisional specimen (control). Meanwhile, independent variables were CNB histopathology and CPC diagnosis of CNB. External variables including immunohistochemical expression, type of the tumor, radiological expertise, primary or metastatic lesions, and size of lesion were also analyzed. All collected data were analyzed using the SPSS program and Fisher's exact test with a confidence level of 95%. $P < 0.05$ was considered as statistically significant.

Results

There were 86 musculoskeletal tumor patients who had both CNB and definitive surgery /excision in CMH within a period of 5 years from January 2011 to August 2015. Final diagnosis from all those cases can be classified based on ICD O or ICD-10 classification. Thus, they were included as study subject. The age distributions were divided into 7 groups: 0-10 year old 6 patients (pts), 11-20 yo 19 pts, 21-30 yo 8 pts, 31-40 yo 13 pts, 41-50 yo 15 pts, 51-60 yo 12 pts, and > 61 yo 13 pts.

Final histopathologic diagnoses of post-excisional specimen were divided into primary bone tumor, primary soft tissue tumor, metastatic lesions and other lesions. Thereafter, they were also divided into benign and malignant lesions as described in table 1.

Table 1. Final Histopathological Diagnosis of Post-excision of Musculoskeletal Lesions

Type of Lesion	Malignant	Benign
Primary Bone Tumor		
Fibrous dysplasia		1
Benign fibrous of histiocyoma		1
Conventional osteosarcoma	3	
Chondroblastic osteosarcoma	5	
Small cell osteosarcoma	1	
Periosteal osteosarcoma	1	
Chondroma		2
Chondrosarcoma	3	
Chondroblastoma		3
Chondromixoid fibroma		2
GCT		10
GCT sarcoma	1	
Ewing's sarcoma	2	
Osteofibrous dysplasia		1
Chondroma	2	
Neurofibromatosis		1
MPNST	1	
Alveolar soft part sarcoma	1	
Lymphoma	5	
Plasmacytoma	4	
Multiple myeloma	1	
Langerhans cell histiocytosis		1
Total	30	22
Primary Soft Tissue Tumor		
Squamous cell carcinoma	1	
Fibroma		2
Rhabdomyosarcoma	4	
Synoviosarcoma	2	
Angiomatosis		3
Neurofibromatosis		1
Alveolar soft part sarcoma	1	
Total	8	6
Metastasis Lesions		
MBD epithelial	4	
MBD SSC	1	
MBD adenocarcinoma	7	
MBD hepatocellular	2	
Total	14	
Others		
Callus		1
Xanthomatosis		2
Osteomyelitis		2
Ganglion cyst		1
Total		6
Total	52	34

The accuracy rate of CNB for musculoskeletal lesion compared to post-excision specimen (control)

is 74.4%. There was an increase in accuracy rate of CNB from 40% in 2011 up to 94.7% in 2015 (Figure 1).

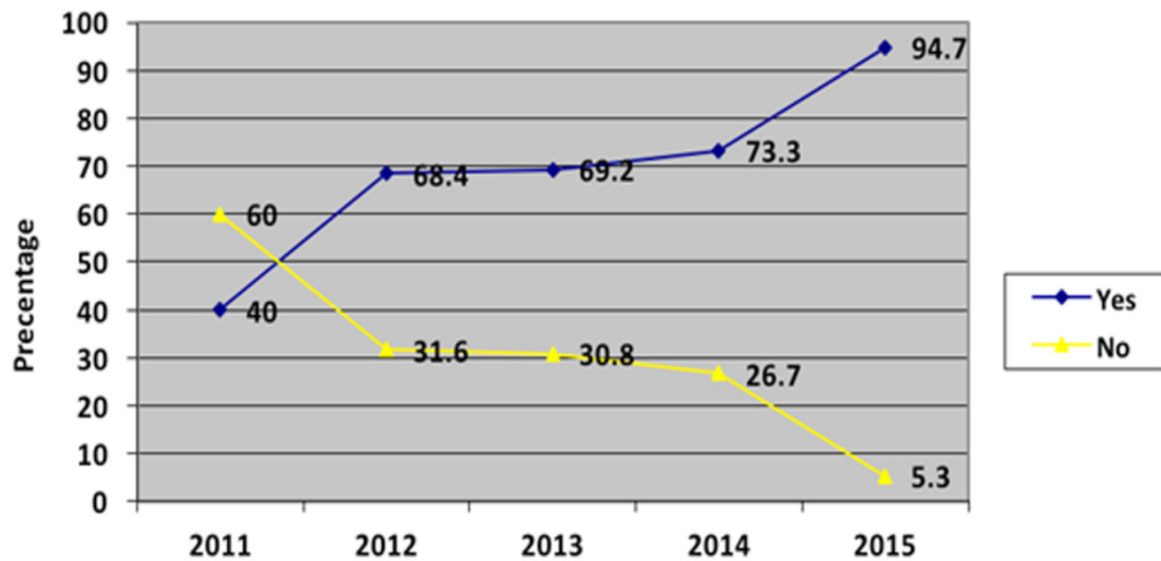


Figure 1. Increased in Accuracy of CNB for Musculoskeletal Tumor Diagnosis

The accuracy rate of CNB after CPC was significantly further increase from 74% to 83.7% (sensitivity 98%, $p < 0.001$). The result of specificity and sensitivity of core biopsy before and after CPC compared with control was shown in table 2. There were 16 cases post CNB which needed

further Immunohistochemical examination. The immunohistochemistry had improved the accuracy of CNB characterized by 9 of 16 cases achieved final diagnosis. The accuracy of CNB after immunohistochemistry was increased from 74.4% to 84.9% with sensitivity 98% (Table 3).

Table 2. Accuracy of Core Biopsy after CPC Compared with Post-Excision Histopathology

CPC	Histopathology		Total	Sensitivity	Specificity	PPV	NPV	LLR (+)	LLR (-)
	Yes	No							
Yes	63	9	72	0.98	0.59	0.87	0.93	2.4	0.031
No	1	13	14						
Total	64	22	86						

PPV: positive predictive value; NPV: negative predictive value; LLR (+): positive likelihood ratio; LLR (-): negative likelihood ratio

Table 3. Accuracy of CNB with Immunohistochemical Staining

After IHC	Core Biopsy		Total	Sensitivity	Specificity	PPV	NPV	LLR (+)	LLR (-)
	Yes	No							
Yes	9	7	16	0.98	0.59	0.87	0.93	2.4	0.031
No	63	7	70						
Total	72	14	86						

IHC: Immunohistochemistry

The accuracy of CNB was 97.1% and 82.7% for benign lesion and malignant lesion respectively. The CNB may distinguish between benign and malignant lesion significantly ($p < 0.001$). After CPC had been done, the accuracy rate of CNB improved significantly from 82.7% to 90.4% ($p < 0.001$) for malignant lesion.

Based on the origin of tumor cells, there were 72 patients who diagnosed with primary tumor and 14 patients with metastatic lesion. The accuracy of CNB to differ and to confirm diagnosis as primary or metastatic lesion was 97.2% and 85.7% respectively ($p < 0.001$). After the CPC, the accuracy rate was increased to 98.6% for primary tumor and 92.9% for metastatic lesion. Overall CNB sensitivity to distinguish between primary and metastatic lesions was 97%.

In this study, 71 of 86 patients (82.6%) had bone lesions and 15 of 86 patients (17.4%) had soft tissue lesions. The accuracy rate of CNB to establish diagnoses of the bone lesions was higher than soft tissue lesions (77.5% versus 60%). However, after the CPC was conducted, the accuracy was increased for both lesions (84.5% versus 80%).

Discussion

After undertaking clinical and radiological examinations, one has to decide whether or not a biopsy is indicated. If the tumour is clinically and radiologically identified as a benign lesion such as osteochondroma and non-ossifying fibroma, one could omit a biopsy. In other words, physician may observe in some benign tumors or treated without prior biopsy.¹¹⁻¹²

Management of bone and soft tissue tumors require high diagnostic accuracy due to the distinctive treatment in benign and malignant lesions. An accurate early diagnosis might lead an increase in patient's prognosis and in CMH, a CPC remains the mainstay in diagnosing a musculoskeletal lesions.

There are two methods of biopsy including closed and open biopsies.^{1,12} Open biopsy is the gold standard procedure to establish musculoskeletal tumor diagnosis^{2-4,12} and a reliable diagnostic method because it allows the pathologist to evaluate cellular morphologic features and tissue architecture from different sites of the lesion. Furthermore, it provides material for performing ancillary studies such as immunohistochemistry, cytogenetics, molecular genetics, flow cytometry, and electron microscopy. Those studies may help in the diagnosis and subclassification of bone and soft-tissue tumors,

therefore guide the definitive treatment.¹³

Open biopsy has some disadvantages and more potential hazards than closed biopsy technique. The open biopsy is more difficult so that it needs more experienced skill from surgeon. It is also more expensive and may cause haematoma, infection, more contamination to the surrounding tissue, and bone destruction. Haematoma and infection may lead to amputation of the limb.¹³⁻¹⁶

Closed biopsy technique consists of fine needle aspiration biopsy (FNAB) and CNB. Both FNAB and CNB are less invasive, fewer potential complications, less expensive and require less time to perform than open biopsy.^{1,4,7} The advantages of FNAB are that it could easily acquire sample material (cells) from different parts of large tumor and be rapidly stained to obtain a rapid diagnosis.¹⁴ Meanwhile, by means of CNB tissue sample architecture is more descriptive. An accurate yet easy to perform and less invasive biopsy procedure is required in diagnosing a musculoskeletal lesion.^{1,13}

Needle biopsy of mesenchymal tumors initially was criticized because the quantity of biopsy material was often insufficient for histopathologic evaluation and ancillary studies that require tissue. FNAB using a 22-gauge needle, is a reliable technique for the diagnosis of soft-tissue tumors that also provides sufficient material for additional studies.^{12,13}

In CMH, CNB had been conducted commonly in patients who had musculoskeletal lesions (after completely clinical and radiological staging). It is also as diagnostic procedure of choice if FNAB failed to determine the final diagnosis or FNAB could not reach the lesions because of intact cortical bone or open biopsy is very difficult.^{13,17}

In this study, 86 cases of musculoskeletal lesion were performed core biopsy then confirmed with histopathology of post excision tissue as control and discussion in CPC. A number of 74.4% cases with CNB technique were correctly diagnosed based on histopathological evaluation only. However, it was increased significantly upon CPC to 83.7% ($p < 0.001$).

Since we performed CNB for musculoskeletal lesion diagnostic approach 2011, there was a trend toward increasing in accuracy over time (from 40% in 2011 up to 94.7% in 2015). The improved accuracy rate was mainly caused by better CNB technique (learning curve), experience of the pathologist to evaluate the small tissue samples from CNB, the more common use of immunohistochemical staining and deep discussion in CPC. This result is

consistent with two previous studies from Pohlig et al.² and Sung et al.¹⁰ which were gaining accuracy of 84.6% and 84.3% respectively upon CPC.

Around 28 of 86 patients (cases) which had the image-guided CNB (CT or fluoroscopy) render diagnostic accuracy of 85.7% (24/28 cases). That result is similar with Sung et al.¹⁰ study that reported accuracy rate of image guided CNB (ultrasound, CT or fluoroscopy) was 84.3%. Heslin et al.¹⁸ reported that CNB had more than 90% accurate in differentiating malignant from benign lesions. He recommended bone biopsies, using a CNB, should be performed under CT or fluoroscopy guidance, and multiple cores should be obtained.

In this study, CNB could significantly distinguish a benign and a malignant musculoskeletal lesion ($p < 0.001$) with accuracy of 97.1% and 82.7%. which after a CPC were done was further increased significantly to 90.4% in distinguishing a malignant lesion. This result is similar to other studies ranging from 76% to 99%.⁵

Although examination of hematoxylin-eosin staining is a gold standard for diagnosis of musculoskeletal tumor, immunohistochemistry remains an integral part of this process especially for soft tissue sarcomas. In this study, immunohistochemistry also provides better accuracy of CNB. Our result is consistent with Pringle¹⁹ who mentioned that immunohistochemistry plays a role to confirm a diagnosis of bone lesion, although it has some limitations. In addition, final result should be discussed among the experts.

In this study, CNB could significantly differ a primary bone tumor from metastatic lesion (97.2% and 85.7%). Should that result discussed in CPC, it was increased until 98.6% and 92.9% respectively. This result shows is similar to a study from Seng et al.²⁰ They reported that the accuracy of CNB in detecting malignancy was 88%. Fraser-Hill²¹ reported the accuracy rate of CNB 82% for metastatic lesion and 83% for primary lesion.

Accuracy rate of CNB in bone lesion is higher than soft tissue lesion (77.5% versus 60%). CPC always provides better accuracy rate of CNB thus, after discussing in CPC it could achieve 84.5% and 80% for each lesion. However, Pohlig et al.² and Sung et al.¹⁰ reported better results than us whether accuracy of CNB in bone lesion or soft tissue lesion. Almost studies reported

that accuracy of histopathology of bone tumor was better than soft tissue tumor, although no statistically significant difference was found. Bone tumor had more pathognomonic cells than soft tissue tumor. Therefore, it is easier to diagnose and to differentiate bone tumor than soft tissue tumor which has much more variations.¹

There were six unrepresentative CNB samples reducing the accuracy. It might be due to some factors the size and location lesion, the surgeon skills and the image-guided biopsy.^{8,17,18} However, there was no morbidity related to the procedure in our research. CNB facilitates the planning of definitive surgery and neo-adjuvant chemotherapy and could be easily repeated or followed by an open biopsy without causing a major morbidity to the patient. It is a safe procedure by skilled persons which complication rate as low as less than 1%.

The indication of the CNB in this study was determined by orthopedic oncologist decision after considering the clinical data and radiologic investigations. There is no guideline of CNB indication yet in CMH previously however, some pathologists in CPC suggested to do CNB in case of FNAB was inconclusive or difficult to establish a certain diagnosis. McCharty²² suggested that CNB was performed after the discussion among orthopedic surgeon, pathologist, and radiologist. Although the analysis of CNB was carried out by a pathologist, clinical and radiologic data also could affect the histopathology conclusion.

Commonly, histopathologic forms were not accompanied by sufficient clinical and radiologic informations, thus the histopathologic conclusion became blunt and affected the diagnostic accuracy test statistically. Significant of a clear clinical information related to final diagnosis should be further investigated.

Conclusion

CNB is a reliable diagnostic method to establish musculoskeletal tumor diagnoses. In this study, the accuracy rate of CNB is comparable with the open biopsy as gold standard. To improve accuracy of CNB, deep discussion in CPC must be done. CPC significantly provides better accuracy rate of CNB. Immunohistochemistry is, an integral part of diagnostic process, able to increase the accuracy of CNB as well.

References

1. Bickels J, Jelinek JS, Shmookler B, Neff RS, Malawer MM. Biopsy of musculoskeletal tumors. Current concepts. *Clin Orthop Relat Res*. 1999;368:212–9.
2. Pohlig F, Kirchhoff C, Grading R, von Eisenhart-Rothe R, Rechl H. Bone and soft tissue sarcoma: principles of biopsy. *InFo Onkologie*. 2010;13:34–7.
3. Mankin HJ, Mankin CJ, Simon MA. The hazards of the biopsy, revisited. Members of the musculoskeletal tumor society. *J Bone Joint Surg Am*. 1996;78:656–63.
4. Pohlig F, Kirchhoff C, Lenze U, Schauwecker J, Burgkart R, Rechl H, et al. Percutaneous core needle biopsy versus open biopsy in diagnostics of bone and soft tissue sarcoma: a retrospective study. *Eur J Med Res*. 2012;17:29.
5. Mitsuyoshi G, Naito N, Kawai A, Kunisada T, Yoshida A, Yanai H, et al. Accurate diagnosis of musculoskeletal lesions by core needle biopsy. *J Surg Oncol*. 2006;94:21–7.
6. Altuntas AO, Slavin J, Smith PJ. Accuracy of computed tomography guided core needle biopsy of musculoskeletal tumours. *ANZ J Surg*. 2005;75:187–91.
7. Kasraeian S, Daniel, Allison, Elke, Ahlmann, Alexander, et al. A comparison of fine-needle aspiration, core biopsy, and surgical biopsy in the diagnosis of extremity soft tissue masses. *Clin Orthop Relat Res*. 2010;468:2992–3002.
8. Welker JA, Henshaw RM, Jelinek J, Shmookler BM, Malawer MM. The percutaneous needle biopsy is safe and recommended in the diagnosis of musculoskeletal masses. *Cancer*. 2000; 89(12):2677–86.
9. Athanasou N, Bielack S, De Alava E, Dei Tos AP, Ferrari S, Hogendoornni PCW, et al. Bone sarcomas: ESMO clinical practice guidelines for diagnosis, treatment and follow-up. *Ann Oncol*. 2010;204–13.
10. Sung KS, Seo SW, Shon MS. The diagnostic value of needle biopsy for musculoskeletal lesions. *Inter Orthop (SICOT)*. 2009;33:1701.
11. Dorfman HD, Vanel D, Czerniak B, Park YK, Kotz R, Unni KK. WHO classification of tumours of bone: introduction. In: Fletcher CDM, Unni KK, Mertens F (ed). *Pathology and genetics of tumours of soft tissue and bone*. Lyon: IARC Press; 2002.
12. Leithner A, Maurer-Ertl W, Windager R. Biopsy of bone and soft tissue tumours. In: Tunn PU (ed). *Treatment of bone and soft tissue sarcomas*. Berlin: Springer-Verlag; 2009.
13. Shmookler B, Bickels J, Jelinek J, Sugarbaker P, Malawer MM. Bone and soft-tissue sarcomas: epidemiology, radiology, pathology and fundamentals of surgical treatment. In: Sugarbaker P, Malawer MM (eds). *Musculoskeletal cancer surgery : treatment of sarcomas and allied diseases*. Washington DC: Springer; 2001.
14. Kilpatrick SE, Renner JB. *Diagnostic musculoskeletal surgical pathology clinicoradiologic and cytologic correlations*. Philadelphia, Pennsylvania. Saunders Elsevier Inc; 2004:1-18.
15. Unni KK, Carrie MBBS, Inwards, Bridge, Kindblom LG, Lester, et al. *Tumors of the bones and joints*, Washington DC: AFIP American Registry of Pathology; 2005:3-10.
16. Mehrotra R, Singh M, Mannan R, Ojha VK, Singh PA, Singh P, et al. Should fine needle aspiration biopsy be the first pathological investigation in the diagnosis of a bone lesion? An algorithmic approach with review of literature. *Cytojournal*. 2007;4(9):1-11.
17. Le HQ, Lee ST, Munk PL. Image guided musculoskeletal biopsies. *Semin Intervent Radiol*. 2010;27(2):191-8.
18. Heslin MJ, Lewis JJ, Woodruff JM, Brennan MF. Core needle biopsy for diagnosis of extremity soft tissue sarcoma. *Ann Surg Oncol*. 1997;4:425–31.
19. Pringle J. The Value of Immunohistochemistry in the diagnosis of Primary Bone Tumors. In: Bertoni FB. *Progress in Bone Pathology*. *Rev Esp Patol* 1999;32(3):362-6.
20. Seng C, Png W, Tan MH. Accuracy of core needle biopsy for musculoskeletal tumors. *J Orthop Surg*. 2013;21(1):92-5.
21. Frase-Hill MA, Renfrew DL. Percutaneous needle biopsy of musculoskeletal lesions, effective accuracy and diagnostic utility. *AJR*. 1992;158:809-12.
22. McCarthy EF. CT-guided needle biopsies of bone and soft tissue tumors: a pathologist's perspective. *Skeletal Radiol*. 2007;36:181–2.