

Glioblastoma in Pregnancy: A Case Report

Bram Pradipta,¹ Cut M. Yeni,² Rajuddin²

¹Department of Obstetrics and Gynecology Faculty of Medicine University of Indonesia

²Department Obstetrics and Gynecology Faculty of Medicine Syiah Kuala University

Abstract

A 33-year-old, Indonesian woman presented with pregnancy and glioblastoma. Chief complaint was headache that worsened since 1 month ago. Other complaints included vomiting, seizure and weakness of the left part of her body when she was 12 weeks pregnant. CT scan result midline shift to the left of falx cerebri with obliterated right ventricle and hypodense mass on right region. Craniotomy was performed but the patient refused to terminate the pregnancy. Patient was supposed to undergo series of radiotherapy but decided not to since it may complicate her pregnancy. After 5 months, patient had recurring complaint and CT scan showed area of hypo and hyperdense in frontoparietal dextra and sinistra with brain edema. Joint operation of cesarean section continued with craniotomy was performed when her condition worsened. The patient treated in the intensive care unit and discharged home in good condition. Every brain tumours in pregnancy bring dilemmas with no standard treatment in medicine. The treatment intention is to minimise mortality and morbidity for both maternal and fetal. The management have to be individualised from a multi-disciplinary team and the consideration of a multitude of factors, including location of the tumour, associated signs and symptoms, fetal gestation and the patient's wishes.

Keywords: glioblastoma, pregnancy, cancer

Glioblastoma dalam Kehamilan: Laporan Kasus

Abstrak

Seorang perempuan Indonesia berusia 33 tahun datang dengan kehamilan dan glioblastoma. Keluhan utamanya adalah sakit kepala yang memberat 1 bulan yang lalu. Keluhan lain adalah muntah, kejang dan kelemahan dari bagian kiri tubuhnya ketika sedang hamil pada usia kehamilan 12 minggu. Hasil CT scan saat itu adalah pergeseran falx cerebri ke kiri dengan ventrikel kanan menghilang dan terdapat massa hipodens dengan. Kraniotomi dilakukan tanpa memperdulikan kehamilannya dan pasien menolak untuk mengakhiri kehamilan. Pasca-operasi pasien menolak menjalani radioterapi karena kehamilannya. Setelah 5 bulan, pasien menjalani CT scan kembali karena keluhanannya berulang dan hasilnya adalah terdapat daerah hipo dan hiperdens di regio frontoparietal kanan dan kiri disertai dengan edema otak. Operasi bersama yaitu operasi sesar dilanjutkan dengan kraniotomi dilakukan karena keadaan pasien yang memburuk. Pasien kemudian dirawat di unit perawatan intensif pasca-operasi dan pulang dalam kondisi baik. Setiap tumor di otak dalam kehamilan membawa dilema tanpa adanya standar pengobatan. Tujuan pengobatan adalah meminimalkan mortalitas dan morbiditas untuk ibu dan janin. Tatalaksana harus dibuat secara individual oleh tim secara multi-disiplin dengan pertimbangan berbagai faktor termasuk lokasi tumor, tanda dan gejala terkait, usia kehamilan dan keinginan pasien tersebut.

Kata kunci: glioblastoma, kehamilan, kanker

Introduction

The incidence of primary intracranial tumour in pregnancy is only 0.36 per 100.000 births.¹ As woman in developed societies defer childbearing to the third or fourth decade of life, this rare association is likely to become more common.² Although considered as the most common intracranial tumour, glioblastoma multiforme has an incidence of only 1 in 33.330 in the general population and carry prognosis of approximately 14 months.³ Glioblastomas are a heterogeneous group of neoplasms that comprise the majority of tumors originating in the central nervous system (CNS).⁴ Although there are no increased incidence of brain tumors in pregnancy, the initial manifestation, especially gliomas, has been found to occur during the first trimester.⁴ It has been noted that pregnancy often masks the presence of an intracranial neoplasm and that the risk of misdiagnosis is high. This is because symptoms such as headache, vomiting, visual disturbance are often encountered in pregnancy. Here we present the case report of a recurrent glioblastoma multiforme in pregnancy.

Case Presentation

History, Examination and Management

A 33- year-old, gravida 2 para 1, Indonesian Acehnese woman presented with pregnancy and recurrent glioblastoma. Her chief complaint was headache that is worsening since 1 month ago. She is a patient of neurosurgery department since 7 months earlier with complaints of major headache, vomiting, seizure and weakness of the left part of her body when she was 12 weeks pregnant. Patients was diagnosed with brain tumor on right temporoparietal region. Her CT scan result were midline shift to the left of falx cerebri with obliterated right ventricle and hypodens mass on right region size 5,04x 5,17 cm x 5,79 cm. (Fig 1)

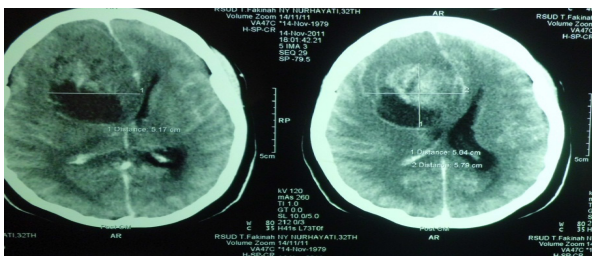


Figure 1. CT Scan Result before the First Operation

Craniotomy was performed with no regards of the pregnancy but the patient refuse to terminate the pregnancy. Post craniotomy patient was supposed to undergo series of radiotherapy but decided not to

since it may complicate her pregnancy. After 5 month went untreated, patient then had another CT scan due to her recurring complaint and the result was there's an area of hypo and hyperdens in frontoparietal dextra and sinistra with brain edema (Figure 2).

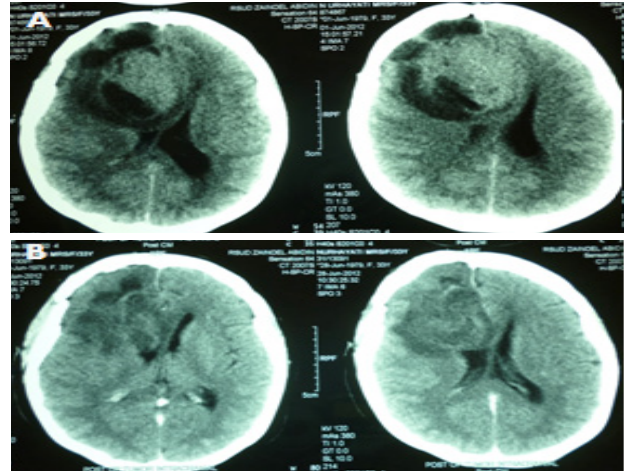


Figure 2. CT Scan Result when The Glioblastoma is Recurring (A) Compared to The Post op Result (B)

The patient was treated for a week when her condition was worsening with loss of consciousness. Joint operation with neurosurgery department was performed, consist of cesarean section that was continued with craniotomy. We delivered a healthy 1900 gram baby boy. The patient was then treated for 2 days in the intensive care unit and another 4 days in the ward then discharged home in good condition.

Discussion

In 2009, the American Cancer Society estimated that one in four deaths in the United States was due to cancer and that cancer was the second most common cause of death during reproductive years.⁵ As woman tend to delay childbearing to the third decade of life, the incidence of gestational cancer is expected to increase.⁵ Of the 18,820 new cases of primary central nervous system tumors diagnosed annually in the United States, gliomas account for over 60% with 30-40% of them being glioblastoma multiforme, 10% being anaplastic astrocytoma and 10% being low grade gliomas.⁴ The most common malignancies associated with pregnancy are reported to be breast cancer, cervical cancer, melanoma, thyroid and hodgekin's lymphoma with less frequent malignancies are leukemia, ovarian, lung and gastrointestinal cancers.⁵ An alternative explanation for the reduced occurrence of primary intracranial neoplasms in pregnant patients may lie not in the patterns of

tumour growth but in reduced fertility of patients with preclinical or undiagnosed brain tumours.⁶

The concurrence of a brain tumour and pregnancy constitutes a clinical problem with symptoms such as headache, vomiting and visual disturbance where it is common to both brain tumours and pregnancy and convulsions caused by a brain tumour may falsely be considered due to eclampsia.⁷ Common presenting symptoms include generalised symptoms such as headache, nausea and vomiting, seizures, syncope and cognitive dysfunction. Common focal symptoms include visual, language, motor and sensory disturbances.⁸⁻⁹ Our patient had recurring symptoms of major headache and vomiting. Since it was early in the pregnancy, a lot of medical doctor that she had visited thought of it as only minor clinical pregnancy complaints. When she complained of seizure and weakness of the left part of her body, that was when her doctor realized it and have it checked. Her CT scan result are midline shift to the left of falx cerebri with obliterated right ventricle and hypodense mass on right region size 5,04x 5,17 cm x 5,79 cm.

It has been shown that pregnancy predisposes the brain to edema formation by upregulation of a type of channel forming trans-membrane protein called aquaporin-4. This protein facilitates the movement of water, glycerol and other solutes across plasma membrane. The likelihood of blood-brain barrier disruption in the presence of neoplasm, further increases the likelihood of edema formation and could become worsened if eclampsia is present.⁵ Others thought that pregnancy does not increase the growth rate of tumour cells and enlargement of tumour size is considered to be a consequence of engorgement of the blood vessels which feed the tumour or to a state of positive water balance as a result of the altered hormonal environment accompanying pregnancy.⁷ In some tumours, such as meningioma, pituitary adenomas and angiomas, however, estrogen and/or progesterone induced proliferation of tumour cells during pregnancy.⁷

Several theories have been advanced to account for the exacerbation of brain tumor-related maternal symptoms that may occur during pregnancy, including steroid hormone-mediated growth (meningiomas) and hemodynamic changes (increased systemic and cerebral blood volume). A potential mechanism that could result in clinical deterioration in expectant mothers with malignant gliomas is an increase in intracranial mass effect from increased tumor blood volume caused by hemodynamic changes inherent to pregnancy.¹⁰

When considering termination of pregnancy, qualified and teamed medical personnel should inform patients about the risks for their health and for the fetus from anti-neoplastic therapy administered during pregnancy.⁵ The management is complicated by the need to consider induced abortion, mode of delivery, neurosurgical management, and adjuvant treatment including radiation therapy to the mother.⁷

Management should be individualised depend on the patient's symptoms and signs, the nature and site of the tumour and the stage of pregnancy. In stable patients with non-life threatening tumours, such as benign supratentorial tumours without any evidence of increased intracranial pressure, management should be based on obstetric criteria.⁷ In patients whose condition rapidly deteriorates, or in whom the brain tumour is malignant, the management should be different from that of patients in a stable condition. Definitive tumour treatment may be required before delivery and, in the worst case, pregnancy may not be allowed to continue.⁷

There are no guidelines for the adjuvant administration of chemotherapy or radiotherapy or the ideal timing of neurosurgical or obstetrical intervention in pregnant women.¹⁰ Because of the relative paucity of reported cases of gliomas diagnosed and treated during pregnancy, the literature right now comprises only case reports and small series.¹⁰ The treatment of malignant gliomas requires a multidisciplinary approach. Current standards of practice for treating newly diagnosed high-grade glioma include maximal safe resection followed by radiotherapy, and, in the instance of newly diagnosed glioblastoma, adjuvant chemotherapy.¹⁰

A patient who presents during the first or early second trimesters may be considered for neurosurgery as the fetus is remote from viability. Radiotherapy, radiosurgery and image-guided surgery may also be an option after the first trimester. Benefits of anti-epileptic medications to control maternal symptoms outweigh their risks of teratogenicity and should not be withheld.⁸

Increased intracranial pressure can occur from the added effects of pressure from the exertions of labor upon the tumor and associated peritumoral edema. This scenario is more of a concern in an undiagnosed, untreated patient. In the case of a symptomatic tumor, an elective Caesarean section should be encouraged.¹⁰ Major operations can be safely performed throughout gestation without increased maternal risk, but a 1–3% risk of foetal loss and minimally increased relative risk (1.5–2.0) for low birth weight and premature delivery exists.²

After the first operation, the patient was supposed to underwent radiation with abdominal shielding. But the patient refused to do so. And after 5 month went untreated, patient then had another CT scan due to her recurring complaint and the result was there's an area of hypo and hyperdens in fronto parietal dextra and sinistra with brain edema. The patient was treated for a week when her condition was worsening with loss of consciousness when we finally decided to perform joint operation cesarean section and continued with craniotomy.

The usage of radiation effect differ correlate to gestation age. During the pre-implantation and implantation period the "all or nothing" rule applies where irradiation of the undifferentiated embryo results in either death or normal development and doses as low as 100 mGy can cause embryonic death, with a reported incidence of 50% with doses of 1 Gy. During the period of organogenesis (weeks 3–12), embryonic death or developmental malformations are frequent with radiation doses of 1 Gy and may occur with doses as low as 50–250 mGy. The foetal dose of 100 mGy (10 rad) during the first trimester is frequently cited as a "threshold dose" for the risk of teratogenesis. Exposure to 250 mGy or higher doses of ionizing radiation during the second and third trimesters is associated with growth retardation, mental retardation, malformations of late-forming tissues (central nervous system, gonads) and premature birth.²

It is well known that therapeutic irradiation of pregnant women can cause microcephaly, mental retardation or even foetal death, especially during the first trimester, or when the pelvis is included within the primary radiation field. When the cranial radiation dose is 40 Gy, the estimated total foetal dose received during the entire course of radiation is approximately 8 Gy.⁷ The risk of cancer up to the age of 15 years attributable to radiation is 1 in 1700 per cGy, of which half will be fatal (i.e. 1 in 3300 per cGy). A dose of 2.2 cGy adds a risk of fatal cancer by the age 15 years of only 1 in 1500. Because the addition of shielding might halve the fetal dose, this risk should be reduced to 1 in 3000.¹¹ For the fetus, these detrimental effects include congenital malformations, potential carcinogenesis, organ toxicity, prematurity, impaired fetal weight gain, growth retardation, and developmental delay. For the mother, chemotherapy associated risks include stillbirth, spontaneous abortion, and maternal sterility.¹⁰

Conclusion

Every brain tumours in pregnancy bring dilemmas with no standard treatment in medicine. Its diagnosis

is challenging because of the need to treat the mother and minimizing the effects of cancer treatment on the fetus. The treatment intention is to minimise mortality and morbidity for both maternal and fetal which can be achieved by prolonging pregnancy while alleviating complications from the brain tumour. The management have to be individualised from a multi-disciplinary team and the consideration of a multitude of factors, including nature and location of the tumor, associated signs and symptoms, fetal gestation and the patient's wishes.

References

1. Erwin G. Exciting new advances in neuro-oncology: The avenue to a cure for malignant glioma. *CA Cancer J Clin.* 2010;60:166-93.
2. Pentheroudakis G, Pavlidis N. Cancer and pregnancy: poena magna, not anymore. *European Journal of Cancer.* 2006;42:126-40.
3. Stupp R, Mason WP. Radiotherapy plus concomitant and adjuvant temozolomide for glioblastoma. *N Engl J Med.* 2005;352:987-96.
4. Felix EO, Richards OC, Ifeanyi AJ, Chukwuka UA, Iwuagwu O. Intracranial tumor manifesting in the 2nd week of pregnancy: case report in a 24 year old female. *Journal of Medicine and Medical Sciences.* 2009;1(2):29-33.
5. Voulgaris E, Pentheroudakis G, Pavlidis N. Cancer and pregnancy: a comprehensive review. *Surgical Oncology.* 2011;20:175-85.
6. Haas J, Janisch W, Staneczek W. Newly diagnosed primary intracranial neoplasms in pregnant women: a population-based assessment. *Journal of Neurology, Neuro-surgery, and Psychiatry* 1986;49:874-80.
7. Nishio S, Morioka T, Suzuki S, Takeshita I, Ikezaki K, Fukui M, et al. Primary brain tumours manifesting during pregnancy: presentation of six cases and a review of the literature. *Journal of Clinical Neuroscience.* 1996;3(4):334-7.
8. Lew PS, Wei Ching Tan, Tan WK, Tan HK. Dilemmas in management of brain tumours in pregnancy. *Annals Academy of Medicine.* 2010;39(1):64-5.
9. McEwan A. Cancer in pregnancy. *Current Obstetrics & Gynaecology.* 2005;15:402-8.
10. Blumenthal DT, Parren MGH, Batten J, Chamberlain MC. Management of malignant gliomas during pregnancy. *Cancer.* 2008;113:3349–54.
11. Haba Y, Twyman N, Thomas SJ, Overton C, Dendy P, Burnet NG. Radiotherapy for glioma during pregnancy: fetal dose estimates, risk assessment and clinical management. *Clinical Oncology.* 2004;16:210-4.