

**How to Cite:**

Wagh, J. G., Veerkar, P. V., Mittal, A., Kumari, R., Sharma, S., & Sharma, S. (2022). Preparation and evaluation of modified herbal “Kumkum Powder” to reduce allergic reactions. *International Journal of Health Sciences*, 6(S5), 11274–11283. <https://doi.org/10.53730/ijhs.v6nS5.11267>

## **Preparation and evaluation of modified herbal “Kumkum Powder” to reduce allergic reactions**

**Dr. Wagh Jyoti G**

MES College of Pharmacy, Sonai, Tal. Newasa, Dist. Ahmednagar, Maharashtra, India

Corresponding author email: [jjyothi2007@gmail.com](mailto:jjyothi2007@gmail.com)

**Prof. Veerkar Prachi V.**

MES College of Pharmacy, Sonai, Tal. Newasa, Dist. Ahmednagar, Maharashtra, India

Email: [prachiveerkar164@gmail.com](mailto:prachiveerkar164@gmail.com)

**Dr. Abhilasha Mittal**

Nims Institute of Pharmacy, Nims University, Jaipur Delhi Highway (NH-11C), Jaipur – 303121, Rajasthan, India

Email: [abhilashamittal24@gmail.com](mailto:abhilashamittal24@gmail.com)

**Dr. Raj Kumari**

ITS College of Pharmacy, Delhi-Meerut Road, Murad Nagar, Ghaziabad, Uttar Pradesh 201206, India

Email: [rajkataria80@gmail.com](mailto:rajkataria80@gmail.com)

**Dr. Shailesh Sharma**

School of Pharmaceutical Studies, Dr. K. N. Modi University, INS-1, RIICO Industrial Area Ph-II, Newai, Dist. Tonk, Rajasthan – 304021, India

Email: [dr.shailus@gmail.com](mailto:dr.shailus@gmail.com)

**Dr. Sonu Sharma**

School of Pharmaceutical Studies, Dr. K. N. Modi University, INS-1, RIICO Industrial Area Ph-II, Newai, Dist. Tonk, Rajasthan – 304021, India

Email: [sonu.sharma283@gmail.com](mailto:sonu.sharma283@gmail.com)

**Abstract**--Sindoor is the mark of a married women in Hinduism. Along the parting-line of a woman's hair (also called mang in Hindi or simandarekha in Sanskrit) or as a dot on the forehead. While in Hinduism, sindoor is the sign of married women. Single women use bindis in a variety of colours for special events, but they do not use sindoor in their hairline parting. Sindoor is the sign of married women in hinduism. A wide prevalence of socio-religious practices in the Asian subcontinent develops multiple skin diseases which may

missed by dermatologist because of lack of awareness. So there is need to develop natural products. 'Kumkum' application can result in pigmented contact dermatitis and lichen planus pigmentosus. Sticker 'bindis' and 'alta' induce contact leukoderma. Irritant and allergic contact dermatitis occurs due to synthetic dyes. Synthetically prepared sindoor unsafe levels of lead which may cause irritation to the skin herbal sindoor has active natural pigments which deliver intense colour that does not that find fade as the day wear on. The herbal sindoor stays for long period without any irritation.

**Keywords**---Sindoor, Dermatitis, Natural Pigments.

## **Introduction**

'Kumkum' is a coloured cosmetic used exclusively by the Hindus. The exact composition of commercial 'kumkum' formulation is unknown; known components include various dyes, fragrances, corn starch, groundnut oil, tragacanth gum, turmeric powder. Kumkum, made with turmeric and slaked lime along with colour enhancing dyes is known to cause allergic contact dermatitis. The possible contact allergens in kumkum include turmeric, Sudan-1, 4-aminoazobenzene, brilliant lake red R. Allergic contact dermatitis to kumkum occurs both due to the dyes (added for enhancing the colour). This study was aim to prepare natural kumkum to avoid various allergic reactions by using *Pterocarpus Santalinus*. The prepared Kumkum is having good acceptance and less side effect than the previous one (Anonymous 2005, Nimkar U. 2006, Premi 1996, Kawai, 1994).

## **Need For the study**

Extensive literature survey have revealed that, the possible contact allergens in kumkum include turmeric, Sudan-1, 4-aminoazobenzene, brilliant lake red R and Cananga oil. Allergic contact dermatitis to kumkum occurs due to the dyes (added for enhancing the color). So it is necessary to develop the method for preparation of alternate, non-toxic and safe Kumkum Powder.

Synthetic dyes that are commonly employed in histopathology for staining tissue sections are harmful to the laboratory personnel and cause skin allergies, respiratory tract infections, irritation and various types of cancers due to the production of toxic waste products on prolonged exposure. For example, dyes with azo bonds, nitro- or amino groups are tumorigenic in causing hepatic and renal carcinomas. To prevent the harmful effects of synthetic dyes, there is a need to identify certain natural substances possessing staining properties, yet are biocompatible, biodegradable and eco-friendly. Therefore, natural dyes have gained interest in the recent years and substantial research is in progress to replace the synthetic dyes (Alturkistani, H. A., et. al. 2016).

Natural dyes are mainly prepared from primary plant sources like fruits, leaves, roots and barks of plants and trees.

Recently, researchers have examined the potential use of natural substances such as curcumin, beetroot, ginger, Pterocarpus osun, rose, henna and *Hibiscus sabdariffa* in staining tissues and microbes. Also rose geranium oil used because geranium oil is a natural anti-oxidant and anti-inflammatory oil, it actively boosts skin's health and natural glow. Ashawagandha is also used to reduce scalp irritation as it has anti-inflammatory properties( Pardeshi et. al. 2022). By helping skin stay conditioned, and soothing irritated or breakout prone skin, it fights against skin affected by harsh weather conditions or prone to acne (Veerkar PV et. al. 2022).

### **Drawbacks of Synthetic Kumkum**

*Kumkum* is one such substance that imparts red color to the tissues and is prepared by mixing turmeric and slaked lime. *Kumkum* powder can be prepared by both natural and commercial methods. Naturally, *Kumkum* is prepared from mixing of turmeric with lime water and camphor or from saffron or combination of turmeric and slaked lime. Commercially, it is prepared by the combination of azo dyes, corn starch, fragrances, chalk powder, ground nut oil, tragacanth gum, turmeric powder and parabens. 'Kumkum' which is available as powder and liquid is usually applied to the center of the forehead, occasionally dusted on the front of the neck or used on the hair parting as "*Sindoor*" (vermilion) to denote the woman's marital status (Nath AK, 2007). Although majority of Hindu women use kumkum, due to it dermatitis develops earlier. This can be explained by either individual susceptibility or constant use for a prolonged period. It is also a common practice for males, especially priests, to use kumkum for religious purposes (Tewary M., 2006).

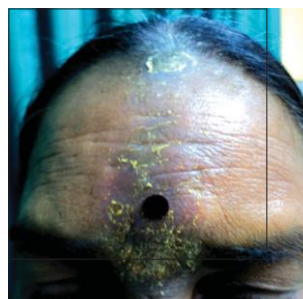
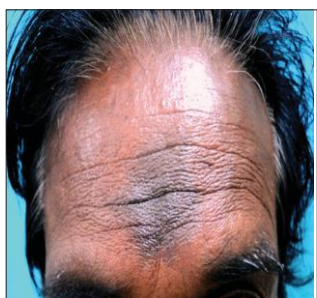
Figure 1: Kumkum-induced pigmented contact dermatitis      Figure 2: Allergic contact dermatitis

Nath and Thappa found pigmented contact dermatitis [Figure 1] in 76% of the patients and allergic contact dermatitis in 24% of the patients using kumkum. The most common site was forehead, followed by the glabellar area, hair parting, abdomen, and neck [Figure 2]. The surrounding skin may be involved if the kumkum trickles down the skin in sweat. Other presentations include only brown or slate gray hyperpigmentation without clinically overt dermatitis (Osmundsen P. E., 2010) and lichen planus pigmentosus (Kumar AS et al. 1986). The terms kumkum and bindi overlap somewhat, but are not synonymous. Kumkum is always applied with paste or powder and can cover the face or other parts of the body. On the other hand, a bindi may be paste or a sticker and is worn only between the eyes. Self-adhesive bindis (sticker bindis) are disposable

substitutes for older liquid bindis, and are popular because of their ease of application (Tewary M., 2006).

Contact leukoderma is one of the most frequent drawback of sticker bindis [Figure 3] (Bajaj 1982, Bajaj 1983, Mathur 1991, Ghosh 2009). In a study of 864 cases of chemical leukoderma, 104 (12%) cases were found due to adhesive bindi (Ghosh 2009). It is possible that bindi-induced depigmentation may be more common in patients predisposed to vitiligo (Bose 1994), and chemical leukoderma must be excluded with certainty from every case of idiopathic vitiligo (Ghosh 2009). While irritation, pruritus and erythema may be seen prior to the development of depigmentation (Mathur 1991). The lag period between use and depigmentation is highly variable, ranging from a few weeks to a few years. Other presentations include allergic contact dermatitis [Figure 4] (Baxter 2002) and granuloma formation (Ramesh 1991).

The sticker bindis are made up of circular discs of polyvinylchloride (PVC) and the adhesive material contains para-tertiary butyl phenol (PTBP) (Mathur 1991, Bajaj 1990, Ghosh 2009), the concentration of which may be as high as 80%. These agents cause depigmentation through their melanocytotoxic effect. Other allergens involved in causation of contact dermatitis due to bindi include epoxy resins (Calnan 1974), Disperse Blue 124, Disperse Blue 106, nickel and thimerosal and gallate mix (Dwyer CM 1994, Lakshmisha 2006). The treatment of bindi leukoderma hinges upon early recognition of the condition and cessation of use of sticker bindis, which can be difficult as most married Hindu women are strongly conditioned to wear a bindi at all times. Other modalities include topical steroids and melanocyte transfer surgery (Bajaj 2010).

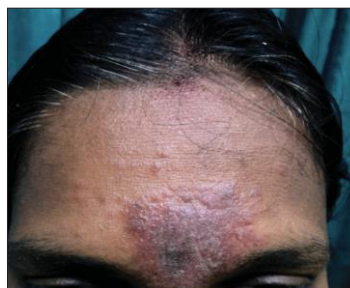
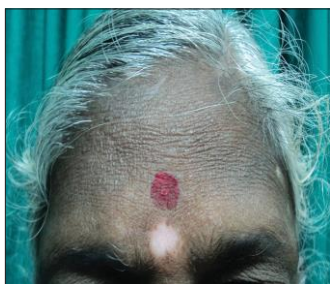
Figure 3: Bindi leukoderma      Figure 4: Allergic contact dermatitis to sticker bindi

### **Novelty of the work**

Allergic contact dermatitis to kumkum occurs due to the dyes (added for enhancing the color). Now-a-days, in the whole world there is turn to return towards the use of herbal products and to adopt more natural way of life, people prefer natural food, herbal medicines and natural curing practices for healthy life. In view of above scenario method for Preparation and Evaluation of Modified Kumkum Powder has been developed to produce an alternate, non-toxic and safe product. The above procedure is novel as natural dye has been taken as a coloring for preparation of Kumkum.

**Material**

Turmeric Powder



Beet Root Powder



Catechu Powder

*Pterocarpus Santalinus* Powder

Figure 5: All Ingredients of Herbal Sindoor

1. Collection and authentication of herbs of plant material
2. Ingredients with their prescribed quantity in the formulation of natural Kumkum.

Table: 1 Ingredients with their prescribed quantity in the formulation of Herbal Kumkum

Sr.No.	Ingredients	Formulation (quantity in gm)
1	Turmeric	2.4
2	Beet Root	1.6
3	Catechu	10
4	<i>Pterocarpus Santalinus</i> powder	6
5	Distilled Water	q.s.

Abbr.: q.s. = quantity sufficient, Note: Composition for 20 gm strength

**Beetroot** contains Betalains which are plant-derived natural pigment that has gained increasing use in recent years as a natural colorant in the food industry

(Gengatharan A, 2015). Beetroot is the most widely used source of betalains (Geogiev V, 2010). In addition to being a natural colorant, beetroot juice has been reported to reduce the cell mutations caused by the effect of nitrosamines, which are formed from nitrate. In addition to this betalains and other bioactive components, beetroot juice and powder have the potential to prevent degenerative diseases such as blood pressure, cardiovascular diseases, and cancer (Gliszczynska-Świgło, A., 2006). Beetroot powder, which is the source of betalains, has both coloring and bioactivity effects as a food ingredient. It is important to ensure the effects of these and other colorant- containing ingredients on the quality properties of products in which we used it and also to ensure that the visual properties they provide are stable throughout their shelf life.

**Acacia catechu** is also known as kattha (Urdu), khadir (Hindustani and Punjabi), khoyer (Bengali and Assamese), khair and babul (Hindi), kaath (Marathi), and kachu (Malay). It is indigenous in India, other Asian countries, and East Africa. Traditionally, *A. catechu* has been used as an antimicrobial, anti-inflammatory and antifungal, coagulant, vermifuge, antidiarrheal, and astringent, and has also been employed to heal wounds, treat obesity and diabetes, and maintain oral hygiene. *Acacia catechu* heartwood extracts have also been used traditionally in the preparation of betel quid (paan masala), which consists of *Piper betle* leaves, *A. catechu* paste, chopped *Areca* nut, lime, and various spices with or without tobacco. Betel chewing is used to produce euphoria, a sense of well-being, heightened sense of alertness, and psycho-stimulation (Chu NS, 2001). This review primarily focuses on applications of *A. catechu* heartwood extracts other than its use in conjunction with betel quid.

**Sandalwood** is very beneficial for skin Psoriasis is a skin condition in which the patient develops itchy, scaly, and red patches commonly on the elbows, knees, trunk, and scalp. When applied topically on the sites where the psoriasis plaques (patches) are present, sandalwood has been shown to have reduced the severity of the disease. This is due to its anti-inflammatory property. When applied topically on the sites where the psoriasis plaques (patches) are present, sandalwood has been shown to have reduced the severity of the disease. This is due to its anti-inflammatory property. Owing to its anti-microbial actions (i.e., anti-bacterial, anti-fungal, and anti-viral actions) along with its anti-inflammatory effects, sandalwood helps in wound healing and is used for the same Eczema is a medical condition where patches of the skin become dry, scaly, red, and cause itching leading to bleeding. Sandalwood oil applied on the skin helps in the management of the condition due to its anti-inflammatory action. Its usefulness in treating acne is due to its anti-inflammatory and anti-bacterial (Healthline).

**Turmeric** Medicinal plants have been used since ancient time, and are sources of important modern drugs. Turmeric (*Curcuma longa* L.) is a widely used condiment and colouring agent. Curcumin has potential in inflammatory and neoplastic disorders of the skin. Turmeric may be the first known cosmetic as it has been traditionally smeared on the skin by women. It is believed to reduce facial hair growth, reduce acne and improve complexion. Many women in Tamil Nadu still apply turmeric on their face daily before taking bath (authors' observation).

The yellow colour has been utilized in skin care products. Tetrahydrocurcumin is an off white hydrogenated form of curcumin that is used topically as a cutaneous antioxidant. It may prevent rancidity of lipids when added to moisturizers. Curcuminoids have potential in cosmeceuticals as antioxidant, anti-inflammatory and skin lightening agents. In-vitro curcuminoids inhibit collagenase, elastase and hyaluronidase (Gurib-Fakim 2006, Gliszczyńska-Świąło, A. 2006, Sivaraman 2007).

**Procedure:** The crude drug was finely powdered by using grinder and passes them by fine mesh sieve. The powdered form of drug was then mixed and thick slurry was made by mixing the water in it. Blending of slurry was done by using stirrer to obtain a liquid colored paste. If water was remained in slurry, therefore, it was filtered and evaporated till dry powder of paste was obtained. Powder obtained was then pulverized to fine powder to get herbal Kumkum.



Figure 6: Prepared Herbal Kumkum

## Results and Discussion

Table 2: Evaluation of formulated herbal Kumkum

S./No.	Evaluation Parameters	Formulation
1	Solubility Water Ethanol Chloroform	Insoluble Insoluble Insoluble
2	Angle of Repose	30.42
3	Sensitivity	Not Sensitive
4	Color Change	Not Observed
5	Water Washability	Washable
6	pH	7

n\*=3

## Biological evaluation

The protocol study was approved by Institute Animal Ethical Committee for animal experimentation. (MES COP-1211/ac/08/CPCSEA).

Primary skin irritation test: There was no any skin irritation observed.




Figure 7: XRD Pattern of Marketed and Prepared Kumkum analysis

XRD pattern of commercial Kumkum shows peaks due to free sulfur, mercury oxide and mercury sulfide (JCPDS File number-20-1227, 01-0896, 02-461, respectively) while the XRD pattern of Modified Kumkum shows peaks only due to mercury sulfide (JCPDS File number-02-461) (Shaffrathul, J., 2007).

## Outcome of Project

The market samples showed itching and redness of forehead skin. In synthetic sindoor, there was deep penetration of the red mark which was not washable by water. It provides an option to replace synthetic dye and heavy metal's salt based sindoor by natural ones, which is safe, stain-free and eco-friendly. The powder provides a synergistic mixture of coloured dry powder which has good sticking capacity to skin and can be easily removed by mop or water washing. The prepared formulation was evaluated and it was found that it was best formulation. Hence, from present investigation it was concluded that this formulated herbal sindoor has better option to women with minimal side effects though a detailed clinical trials may be done to access the formulation for better efficacy.

## Acknowledgments

The Authors are thankful to the Managements of the Institutes and universities for providing the necessary facilities to conduct the research works. Authors are also grateful to two anonymous reviewers for their valuable comments on the earlier version of this paper.

## References

1. Al-Hamid, R. (2021). Bureaucracy culture change of administrative services on COVID-19 pandemic era. *International Journal of Social Sciences and Humanities*, 5(3), 192–202. <https://doi.org/10.53730/ijssh.v5n3.1720>

2. Alturkistani, H. A., Tashkandi, F. M., & Mohammedsaleh, Z. M. (2016). Histological stains: a literature review and case study. *Global journal of health science*, 8(3), 72.
3. Anonymous (2005), The dyestuffs industry in India, Colourage (Annual), 43-46.
4. Bajaj, A. K., & Govil, D. C. (1982). Contact Depigmentation. *Indian Journal of Dermatology, Venereology and Leprology*, 48(2), 112-115.
5. Bajaj, A. K., Govil, D. C., & Bajaj, S. (1983). Bindi depigmentation. *Archives of Dermatology*, 119(8), 629-629.
6. Bajaj, A. K., Gupta, S. C., & Chatterjee, A. K. (1990). Contact depigmentation from free para-tertiary-butylphenol in bindi adhesive. *Contact dermatitis*, 22(2), 99-102.
7. Bajaj, A. K., Saraswat, A., & Srivastav, P. K. (2010). Chemical leucoderma: Indian scenario, prognosis, and treatment. *Indian journal of dermatology*, 55(3), 250.
8. Baxter, K. F., & Wilkinson, S. M. (2002). Contact dermatitis from a nickel-containing bindi. *Contact dermatitis*, 47(1). : 47:55.
9. Bose, S. K. (1994). Is bindi-induced depigmentation common in patients predisposed to vitiligo?. *J Dermatol (Tokyo)*, 21, 370-371.
10. Calnan, C. D., & Cooke, M. A. (1974). Leucoderma in industry. *Occupational Medicine*, 24(2), 59-61.
11. Chu, N. S. (2001). Effects of betel chewing on the central and autonomic nervous systems. *Journal of biomedical science*, 8(3), 229-236.
12. Dwyer CM, Forsyth A (1994). Allergic contact dermatitis from bindi. *Contact Dermatitis*;30:174.
13. Gengatharan, A., Dykes, G. A., & Choo, W. S. (2015). Betalains: Natural plant pigments with potential application in functional foods. *LWT-Food Science and Technology*, 64(2), 645-649. <http://dx.doi.org/10.1016/j.lwt.2015.06.052>.
14. Georgiev, V. G., Weber, J., Kneschke, E. M., Denev, P. N., Bley, T., & Pavlov, A. I. (2010). Antioxidant activity and phenolic content of betalain extracts from intact plants and hairy root cultures of the red beetroot *Beta vulgaris* cv. Detroit dark red. *Plant foods for human nutrition*, 65(2), 105-111. [http://dx.doi.org/10.1007/s11130-010-](http://dx.doi.org/10.1007/s11130-010-.) PMid:20195764.
15. Ghosh, S., & Mukhopadhyay, S. (2009). Chemical leucoderma: a clinico-aetiological study of 864 cases in the perspective of a developing country. *British Journal of Dermatology*, 160(1), 40-47.
16. Gliszczyńska-Świgło, A., Szymusiak, H., & Malinowska, P. (2006). Betanin, the main pigment of red beet: Molecular origin of its exceptionally high free radical-scavenging activity. *Food additives and contaminants*, 23(11), 1079-1087.
17. Goh, C. L., & Kozuka, T. (1986). Pigmented contact dermatitis from 'kumkum'. *Clinical and experimental dermatology*, 11(6), 603-606.
18. Gurib-Fakim, A. (2006). Medicinal plants: traditions of yesterday and drugs of tomorrow. *Molecular aspects of Medicine*, 27(1), 1-93.
19. <https://www.healthline.com/health/what-is-sandalwood>
20. Kawai, A., Zhang, X. M., Nakagawa, M., Kawai, J., Okada, T., & Kawai, K. (1994). Allergic contact dermatitis due to mercury in a wedding ring and a cosmetic. *Contact dermatitis*, 31(5), 330-331.
21. Kumar, A. S., Pandhi, R. K., & Bhutani, L. K. (1986). Bindi dermatoses.

- International journal of dermatology*, 25(7), 434-435.
22. Laxmisha, C., Nath, A. K., & Thappa, D. M. (2006). Bindi dermatitis due to thimerosal and gallate mix. *Journal of the European Academy of Dermatology and Venereology*, 20(10), 1370-1372.
  23. Mathur, A. K., Srivastava, A. K., Singh, A., & Gupta, B. N. (1991). Contact depigmentation by adhesive material of bindi. *Contact dermatitis*, 24(4), 310-311.
  24. Mehta, S. S., & Reddy, B. S. N. (2003). Cosmetic dermatitis—current perspectives. *International journal of dermatology*, 42(7), 533-542.
  25. Nath, A. K., & Thappa, D. M. (2007). Kumkum-induced dermatitis: an analysis of 46 cases. *Clinical and Experimental Dermatology: Clinical dermatology*, 32(4), 385-387.
  26. Nimkar, U., & Bhajekar, R. (2006). Ecological requirements for the textile industry. *Colourage*, 53(4), 135-142.
  27. Osmundsen, P. E. (1970). Pigmented contact dermatitis. *British Journal of Dermatology*, 83(2), 296-301.
  28. Pardeshi R, Veerkar P, Wagh J (2022), Review use of Ashwagandha as Hair Tonic;12;06.36106/ijar.
  29. Premi, G. D. (1996). Indian textile industry: Emerging eco-friendly standards for exports. *Clothline*, 9(9), 105-106.
  30. Ramesh, V. (1991). Foreign-body granuloma on the forehead: reaction to bindi. *Archives of dermatology*, 127(3), 424-424.
  31. Shaffrathul, J., Karthick, P., Rai, R., & Srinivas, C. (2007). Turmeric: Role in hypertrichosis and acne. *Indian Journal of Dermatology*, 52(2).
  32. Silveistr, A., Zozuliak-Sluchyk, R., Iaroshevska, L., Strikhar, O., & Derkach, S. (2022). Assessment of situation in educational activities with need to introduce remote technologies during pandemic. *International Journal of Health Sciences*, 6(1), 32–39. <https://doi.org/10.53730/ijhs.v6n1.3063>
  33. Sivaraman, K. (2007). Agronomy of turmeric. Ravindran P, Ravindran K, Nirmal B, Sivaraman K. Turmeric: the genus Curcuma.
  34. Suryasa, I. W., Rodríguez-Gámez, M., & Koldoris, T. (2021). Get vaccinated when it is your turn and follow the local guidelines. *International Journal of Health Sciences*, 5(3), x-xv. <https://doi.org/10.53730/ijhs.v5n3.2938>
  35. Tewary, M., & Ahmed, I. (2006). Bindi dermatitis to ‘chandan’bindi. *Contact dermatitis*, 55(6), 372-374.
  36. Veerkar P V, Wagh JG (2022). Pelargonium Graveolens Therapeutic Agent for Antibacterial, Antifungal, Anti-inflammatory;12;10.36106/ijar.