

**How to Cite:**

AL-Essawi, D. A.-H. K., Yasir, S. M., Najeeb, I. R., & Hussein, H. M. (2022). Renal histological effects of mebeverine drug on pregnant white rats and their fetuses during late period of pregnancy. *International Journal of Health Sciences*, 6(S5), 5228–5245.  
<https://doi.org/10.53730/ijhs.v6nS5.9776>

## **Renal histological effects of mebeverine drug on pregnant white rats and their fetuses during late period of pregnancy**

**Dalal Abdel-Hussein Kadhemi AL-Essawi**

Department of Biology, Faculty of Education for Girls, University of Kufa, AL-Najaf AL-Ashraf Iraq.

Email: [Dalala.alessawi@uokufa.edu.iq](mailto:Dalala.alessawi@uokufa.edu.iq)

**Shaymaa Malik Yasir**

Department of Biology, College of Education for pure sciences, University of Kerbala, Kerbala Iraq.

Email: [shaimaa.malik@uokerbala.edu.iq](mailto:shaimaa.malik@uokerbala.edu.iq)

**Ibtihal Riyadh Najeeb**

Department of Radiology, Faculty of Medical Technology, The Islamic University, AL-Najaf AL-Ashraf Iraq.

Email: [Ibtihal.Riad@iunajaf.edu.iq](mailto:Ibtihal.Riad@iunajaf.edu.iq)

**Hanaa Mumtaz Hussein**

Al Najaf Education Directorate.

Email: [hanaaalshami48@gmail.com](mailto:hanaaalshami48@gmail.com)

**Abstract**--This study was carried out to indicate the histological changes of mebeverine drug on the renal structure of pregnant white rats and their fetuses for a pregnancy period of 20 days, the number of rats used in this study was 20 female and male rats of type *Rattus rattus* (Sprague Dawley strain), 10 of them were fertile male rats with an average age of (10.5) weeks and an average weight of (231)g, the male rats were used for mating only, and the rest rats were 10 adult female rats with an average age of (11.5) weeks and an average weight of (240) g. The experiments of the current study were conducted in the Department of biology of the Faculty of Education for Girls/University of Kufa for the period from 10/6/2021 to 1/1/ 2022, males and females of rats were mated for the purpose of obtaining the pregnant rats required in this study which were 10 pregnant rats which were divided into two groups: one of the two groups was the control group which it was treated with physiological salt solution only and contained 5 pregnant rats, while the other group was treated with mebeverine drug at a concentration of ( 0.96) mg / kg of body weight

and included 5 pregnant rats, all pregnant rats in the two groups were treated from the second day until the 20th day of pregnancy with a single dose by intraperitoneal injection daily. The results of the study indicated that mebeverine drug affected the histological structure of the kidneys of fetuses and the kidneys of pregnant female rats during pregnancy for a period of 20 days causing various histological-pathological changes such as necrosis, shrinkage, damage and bleeding on the renal glomeruli, wall expansion and damage of the wall of Bowman's capsule, damage of the walls of the renal tubules and enlargement and congestion in some of them and bleeding in others, in addition to necrosis and damage of the renal tissue and the presence of hemorrhage in them, as well as infiltration of inflammatory cells was observed.

*Conclusion:* We can conclude from this study that the use of mebeverine drug during pregnancy caused destruction and damage of the histological structure of the kidneys of pregnant female rats, and it also affected the development of the kidney tissue of the fetuses of these pregnant rats and stimulated pathological effects in it which indicates that the drug can pass through the placenta from mothers to fetuses during pregnancy.

**Keywords**---mebeverine drug, pregnancy, female rats.

## Introduction

Multiple congenital malformations occur due to the exposure of fetuses at different periods of pregnancy to factors that stimulate these malformations which include genetic and environmental factors such as prescription or over-the-counter chemical drugs during pregnancy causing congenital disorders to fetuses or newborns [1].

Mebeverine is an antispasmodic and muscle relaxant drug whose action is directly on the smooth muscles of the digestive tract to reduce painful cramps, mebeverine drug belongs to the class of organic compounds known as p-methoxybenzoic acids, the scientific name of this drug is mebeverine, while its chemical name is 4- (ethyl (p-methoxy-alpha-methylphenethyl) amino), this drug is known by many different trade names like Spasmin, Mebetalin, Beviran, Spasmotalin, Despavine, Sumo, Duspatalin retard, Coloverin sr, Colo relax and others, but the most well-known brand names of the drug are Mebagen and Duspatalin [2].

The exact mechanism of mebeverine action is still unknown, but since mebeverine is a synthetic anticholinergic so it has an antispasmodic effect through its direct action on the smooth muscles of the gastrointestinal tract stimulating the relaxation of these muscles but at the same time it does not affect the normal movement of the intestines [3,4], in addition to that a number of mechanisms have been suggested to explain the action of this drug on the gastrointestinal tract and the most important of these mechanisms are: the drug has a local anesthetic action, inhibiting acetylcholine receptors (84%), reducing

the permeability of ion channels, stimulating changes in the mechanism of water absorption, in addition to its effect on inhibiting norepinephrine reuptake [5].

this drug has many pharmaceutical forms such as slow-acting capsules or tablets, or as a liquid when there is difficulty in swallowing tablets [6,7] and mebeverine is almost completely metabolized mostly by esters and their metabolites are excreted mainly in the urine [8], some studies have indicated that mebeverine exists in two similar forms and commercially available drug is a mixture of them and both of them have different pharmacokinetic properties[9,10].

Mebeverine is classified in the category of gastrointestinal diseases because it treats the symptoms that accompany some diseases affecting the gastrointestinal tract especially those related to the colon, such as irritable bowel syndrome, spastic colitis, spastic constipation, chronic irritable colon and mucous colitis. mucous colitis[11,12] and these symptoms include stomach cramps, bloating and cramps in the abdomen, pain, diarrhea, constipation and stool coming out in the form of small hard pellets [13,14], the side effects that may accompany the use of mebeverine drug are feeling tired, dry mouth, heartburn and indigestion, redness and itching of the skin, slow and irregular heartbeat, dizziness and headache, constipation, loss of appetite, insomnia and difficulty sleeping and general malaise of the body and the immune system disorder which is represented by allergic reactions that cause symptoms of hypersensitivity such as difficulty breathing, swelling of the face, lips or mouth and rashes [15,16].

This drug should not be used by people who are hypersensitive to it or to one of its components, or who suffer from acute porphyria and it is not recommended to use it during pregnancy, mebeverine drug can only be used for treatment with a prescription and the doctor must be informed of diseases or any health problems in the patient, especially problems related to the intestines such as obstruction and severe constipation, kidney and liver problems or problems in the heart such as rapid heartbeat [17,18].

Because there are no adequate studies on whether this drug is excreted in the mother's milk or not, so it is preferable during the lactation period not to be used by lactating females, and it is also recommended that this drug not be used by children and persons under 18 years of age due to the absence of any studies about the safety of this drug in these age groups[19].

**Kay words: mebeverine drug, Renal effects, pregnant rats, fetuses, pregnant females, kidneys**

### ***Aim of study***

Because there are not enough studies on the possible effects of mebeverine drug on the renal histological structure of pregnant females of rats and their fetuses during pregnancy, the current study was planned.

## Materials and Method

### ***-Preparing pregnant rats***

The total number of rats used in this study was (20) rats, 10 male and 10 female rats of the type *Rattus rattus* (Sprague Dawley strain) which were brought from the Faculty of Science - University of Kufa, all rats were placed in plastic cages under the same laboratory conditions in terms of temperature, ventilation, lighting and humidity, the animals were freely provided with water and food throughout the experiment period.

The rat animals included 10 adult female rats with averages age (11.5) weeks and weight (240) g, in addition to 10 fertile male rats with average age (10.5) weeks and weight (231) g, the mating process between rats was conducted by placing one male rat with a one female rat in each mating cage throughout the night, the mated female rats were examined in the morning to see the mating plug in the vagina or in the mating cages as in the figure (1-3), the day when the mating plug was seen was the zero day of pregnancy [20], then 10 pregnant rats were distributed into two groups: the first group contained 5 pregnant rats treated with physiological salt solution (NaCl 0.9%) and represented the control group, while the other group was treated with mebeverine drug at concentration of (0.96) mg/kg of body weight, all pregnant rats in both groups were treated from the 2nd day to the 20<sup>th</sup> day of pregnancy by intraperitoneal injection with one dose per day.



Mating plug :Figure(1-3)

### ***The drug***

The drug used in the current study is mebeverine which was brought from pharmacies in Najaf Al-Ashrif Governorate, This drug was in the form of pills which each pill contained (135) mg, after that the **required** concentration in this study was prepared which was 0.96 mg / kg of body weight, then the drug was dosed to the experimental animals according to body weight.

### ***Anatomy of pregnant rats.***

After 20 days of pregnancy, pregnant female rats were anesthetized by diethylether, then the rats were dissected by fixing them in the autopsy dish with pins, after that the abdominal cavity was opened longitudinally and the two

horns of the uterus and kidneys were removed from the pregnant rats and the adipose tissue and other tissues attached to it were removed, the two uterine horns were opened with sharp scissors and the fetuses in it were extracted which were washed with physiological solution, the fetuses were anesthetized with diethyl ether and dissected to obtain the kidneys, then the kidneys of pregnant females and fetuses were placed in a 10% formalin solution for 48 hours to prepare the sections for histological study.

### **Preparation and examination of tissue sections**

After dissecting the pregnant rats and their fetuses during the 20th day of pregnancy and obtaining the kidneys for them, the tissue sections of the kidneys were prepared according to [21] method, then the tissue slides of the kidneys of pregnant females and their fetuses were examined using a compound light microscope of the type Olympus- Japan, then photographs of the histological sections were taken by using the same microscope with which the slides were examined and which was provided with a Sony camera with two forces (10X, 40X).

### **Results & Discussion**

The results of the microscopic examination of the tissue sections in the untreated pregnant female rats from the control group showed the normal structure of the kidney tissue for a pregnancy period of 20 days as shown in the figures (1,4), while the structure of the kidneys revealed different pathological changes in the tissue of the groups of pregnant female rats treated with mebeverine drug at concentration of (0.96)mg/kg of body weight for the same period of pregnancy compared to the control group, these pathological effects were represented by shrinkage and necrosis of the renal glomeruli and their damage, in addition to hemorrhage, congestion and disintegration of some renal glomeruli, dilation of Bowman's capsule and the damage of its wall, as for the renal tubules, they were also affected and they suffered from the separation of the inner lining from the basement membrane in some tubules, the walls of some renal tubules were destroyed, congestion and bleeding in others, necrosis in the walls of some renal tubules, and bleeding and necrosis in the renal tissue of the kidneys as shown in figures (2,3,5,6,7,8,9,10,11,12,13,14,15,16,17,18), and the fetuses kidneys were also greatly affected when pregnant female rats were treated with mebeverine for 20 days of pregnancy, in addition to the infiltration of inflammatory cells in the renal tissue, as is evident in the figures (20,21,22,24,25,26,27,28,29,30,31,31,33,34,35,36) when compared with the kidney tissue in the control group as shown in the figures (19,23), mebeverine drug belongs to the group of anticholinergic drugs that work to reduce the effects of the neurotransmitter acetylcholine in the central and peripheral nervous system which stimulates the expansion of capillaries and contraction of the striated muscles [22,23], this drug is considered a strong antispasmodic agent and this drug is considered a local anesthetic, but its local anesthetic effects are less compared to other local anesthetics [24], studies have indicated that the drug's relaxing effect is not specific to the blood vessels, but also appears on the heart and other smooth muscles, and the drug's antispasmodic activity is not due to one specific system or mechanism, but several different mechanisms may be involved [25], therefore when this drug is inhibited by the acetylcholine compound,

it leads to a narrowing of the blood vessels causing a lack of ischemia that reduces the delivery of oxygen and nutrients to the various organs of the body including the kidneys stimulating various harmful tissue effects in them, as the drug mebeverine may cause programmed death of cells, necrosis of cells and changes in the body, degenerative changes and thus destroys the renal tissue of mothers and fetuses of rats, and the drug mebeverine drug may have an effect on the development and differentiation of fetuses during pregnancy causing abnormal changes in them, or the reason for the result of this study may be that mebeverine drug stimulated the generation of free radicals as a result of its oxidation of lipids in cell membranes and other intracellular components such as carbohydrates, nucleic acids, proteins and others causing cell breakdown in various body tissues such as the kidneys as a result of oxidative stress resulting from increased levels of oxidative stress, free radicals as oxidizing agents reduce the levels of antioxidants in the body making the body less able to deal with free oxygen radicals to get rid of and restrict them, free oxygen radicals such as hydroxyl and peroxide are highly reactive molecules that are generated primarily in the mitochondria of cells during metabolic activities, especially in the cells of muscle and connective tissue in addition to the cells lining blood vessels, and that its high levels lead to tissue damage as a result of its harmful effect on the body in general, raising oxidative stress, which increases the possibility of infection with various and dangerous diseases such as cancer, or the reason for this is that this drug increased the generation of free oxygen radicals and consumed endogenous antioxidants in the body, thus reducing their levels. In addition, the antioxidant in fetuses is poorly developed in the various periods of embryonic development, especially the early periods causing a delay or lack of development and growth of the various organs of the fetuses during the advanced periods of embryonic development and a catalyst for cytotoxicity, deformed disorders and abnormal changes in the tissue integrity of the kidneys of fetuses and mothers, such as degeneration, damage and damage [26].

Due to the lack of adequate studies on the passage of mebeverine drug through the placenta during pregnancy from the pregnant females to the fetuses, so these pathological effects in the kidney tissues of fetuses that this study showed give evidence that mebeverine drug can crossing through the placenta of mothers to fetuses during pregnancy and causing abnormal changes in fetal tissues and generating toxic effects for both fetuses and pregnant females.

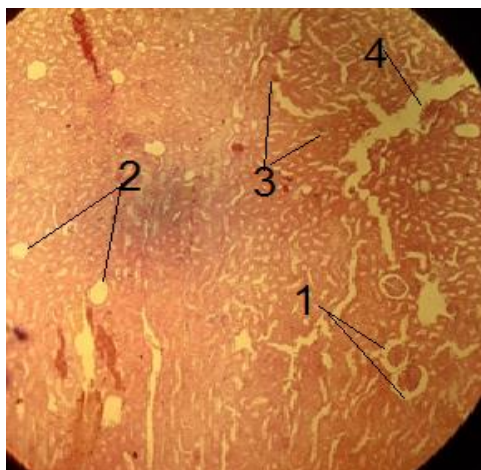

Figure (1) A cross-section in the kidney of a pregnant rat from a control group during a 20-day pregnancy in which it is observed: - (1) Renal glomeruli (2) Renal tubules (Hemotoxylin & Eosin-100x stain).

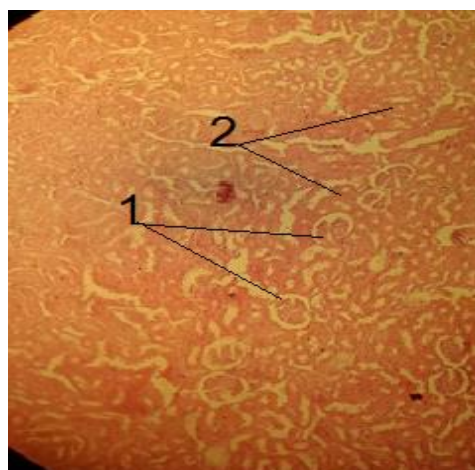


Figure (2) A cross-section in the kidney of a pregnant rat from the group treated with mebeverine drug at a concentration of 0.96 mg/kg during a 20-day pregnancy in which it is observed: - (1) Shrinkage of renal glomeruli (2) Damage of renal glomeruli (3) Hemorrhage in renal tubules (4) Necrosis in renal tissue (Hemotoxylin & Eosin-100x stain).

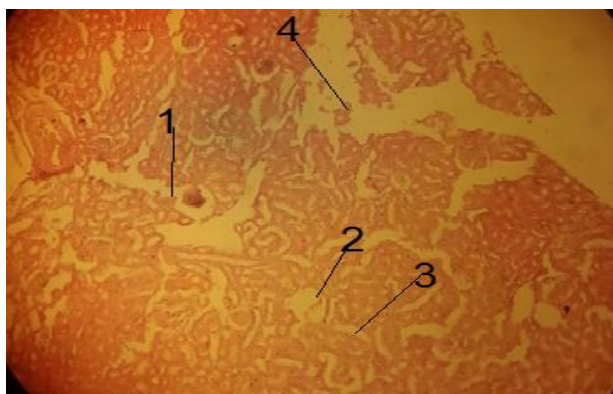


Figure (3) A cross-section in the kidney of a pregnant rat from the group treated with mebeverine drug at a concentration of 0.96 mg/kg during a 20-day pregnancy in which it is observed: - (1) Shrinkage of renal glomerulus & damage the it wall (2) Damage of renal glomerulus (3) Sloughing off wall of renal tubule (4) Necrosis in renal tissue (Hemotoxylin & Eosin-100x stain).



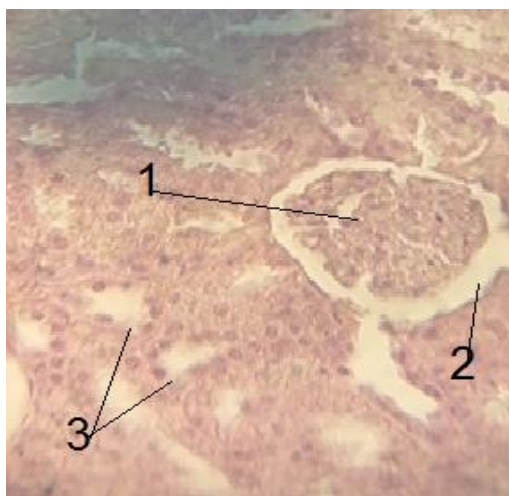


Figure (4) A cross-section in the kidney of a pregnant rat from a control group during a 20- day pregnancy in which it is observed: - (1) Renal glomeruli (2)Bowman capsule (3)Renal tubules (Hemotoxylin & Eosin-400x stain).

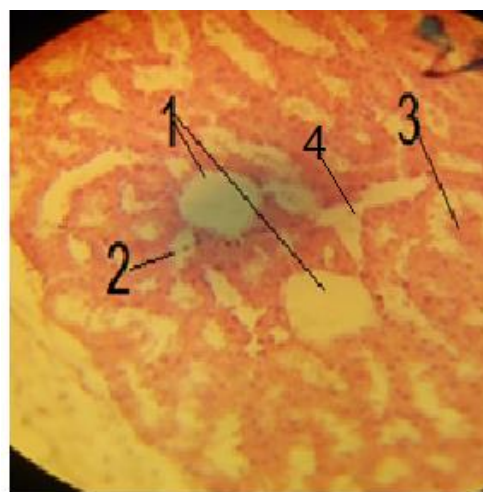


Figure (5) A cross-section in the kidney of a pregnant rat from the group treated with mebeverine drug at a concentration of 0.96 mg/kg during a 20- day pregnancy in which it is observed :- (1) Damage of renal glomeruli (2) Damage of renal tubule(3) Hemorrhage into renal tubule (4) Necrosis in renal tissue (Hemotoxylin & Eosin-400x stain).

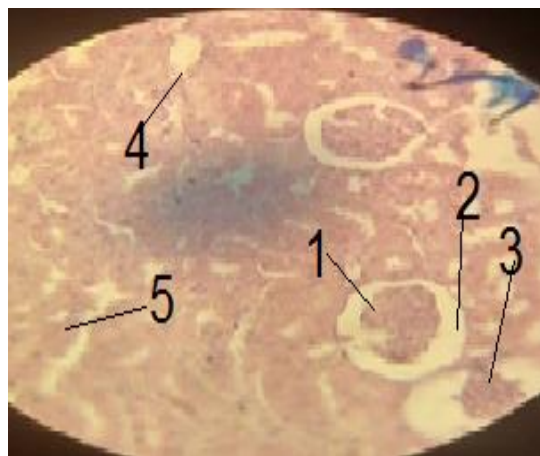


Figure (6) A cross-section in the kidney of a pregnant rat from the group treated with mebeverine drug at a concentration of 0.96 mg/kg during a 20 -day pregnancy in which it is observed :- (1,3) Shrinkage & necrosis of renal glomerulus (2)Bowman's capsule expansion (4) Renal tubule well damage(5) Renal tubule enlargement (Hemotoxylin & Eosin- 400x stain).

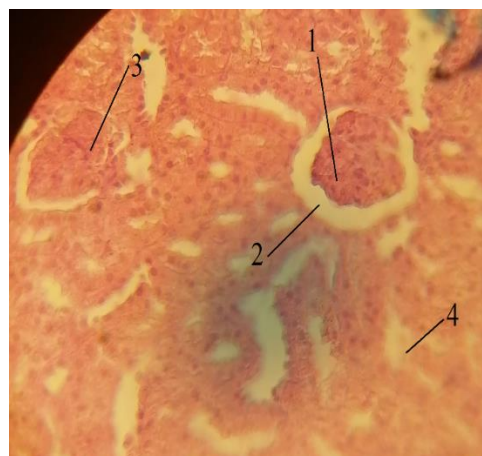

Figure (7) A cross-section in the kidney of a pregnant rat from the group treated with mebeverine drug at a concentration of 0.96 mg/kg during a 20- day pregnancy in which it is observed :- (1) Shrinkage of renal glomerulus (2)Bowman's capsule expansion (3) Hemorrhage into renal glomerulus (4) Renal tubule well damage (Hemotoxylin & Eosin-400x stain).



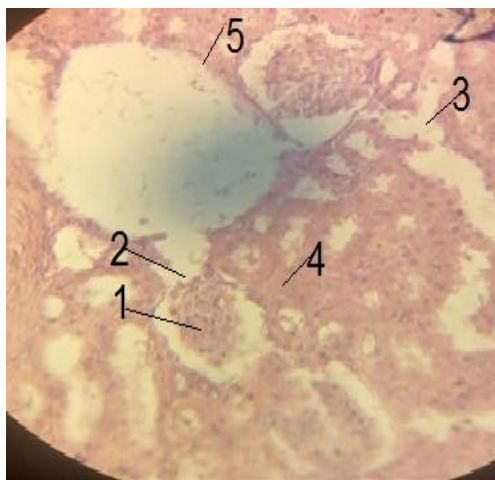


Figure (8) A cross-section in the kidney of a pregnant rat from the group treated with mebeverine drug at a concentration of 0.96 mg/kg during a 20- day pregnancy in which it is observed :- (1) Shrinkage of renal glomerulus (2)Bowman's capsule damage (3) Renal tubule well damage (4) Hemorrhage into renal tubule (5)Necrosis in renal tissue (Hemotoxylin & Eosin-400x stain).

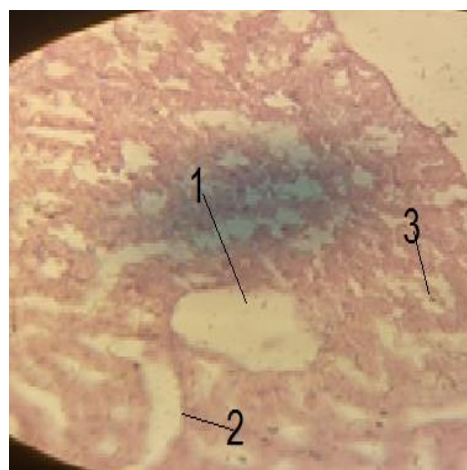


Figure (9) A cross-section in the kidney of a pregnant rat from the group treated with mebeverine drug at a concentration of 0.96 mg/kg during a 20- day pregnancy in which it is observed :- (1) Damage of renal glomerulus (2) Necrosis in renal tubule (3) Hemorrhage into renal tubule(Hemotoxylin & Eosin-400x stain).

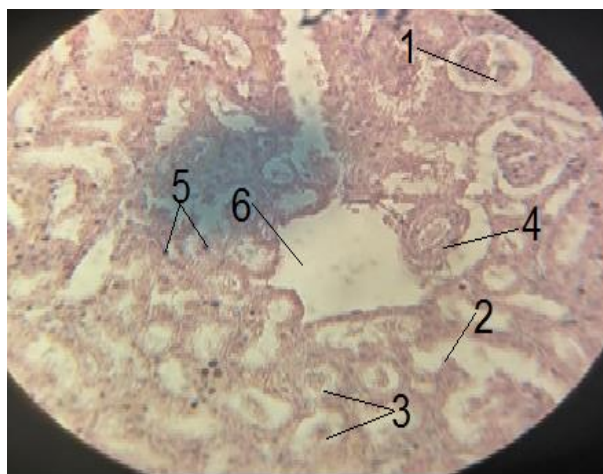


Figure (10) A cross-section in the kidney of a pregnant rat from the group treated with mebeverine drug at a concentration of 0.96 mg/kg during a 20- day pregnancy in which it is observed :- (1) Necrosis in renal glomerulus (2)Bowman's capsule damage (3) Damage of renal tubule (4) Damage in renal tissue (Hemotoxylin & Eosin-400x stain).

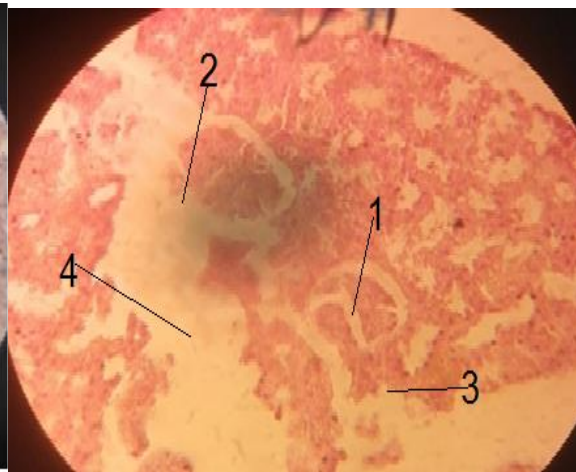

Figure (11) A cross-section in the kidney of a pregnant rat from the group treated with mebeverine drug at a concentration of 0.96 mg/kg during a 20- day pregnancy in which it is observed:- (1) Necrosis & shrinkage of renal glomerulus(2) Damage of renal tubule(3) Hemorrhage into renal tubules (4) Enlargement of the blood vessel (5) Inflammatory cell infiltration(6) Necrosis in renal tissue (Hemotoxylin& Eosin-400x

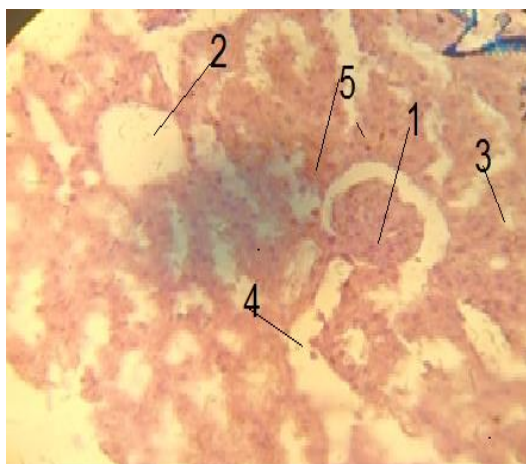


Figure (12) A cross-section in the kidney of a pregnant rat from the group treated with mebeverine drug at a concentration of 0.96 mg/kg during a 20- day pregnancy in which it is observed:- (1) Shrinkage of renal glomerulus (2) Damage of renal glomerulus (3) Enlargement of the renal tubule (4) Necrosis in renal tissue (5) Hemorrhage into renal tissue (Hemotoxylin & Eosin-400x stain).

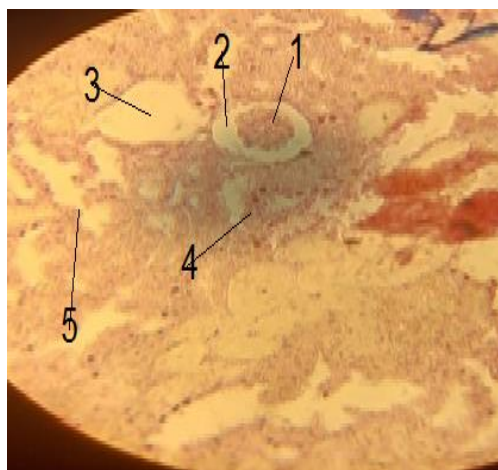

Figure (13) A cross-section in the kidney of a pregnant rat from the group treated with mebeverine drug at a concentration of 0.96 mg/kg during a 20- day pregnancy in which it is observed:- (1) Severe shrinkage of renal glomerulus (2) Bowman's capsule expansion (3) damage of renal glomerulus (4) Separation of the inner lining of the renal tubule (5) Necrosis in renal tissue (Hemotoxylin & Eosin-400x stain).

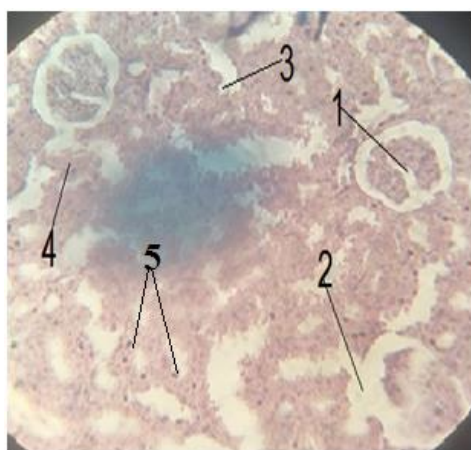

Figure (14) A cross-section in the kidney of a pregnant rat from the group treated with mebeverine drug at a concentration of 0.96 mg/kg during a 20- day pregnancy in which it is observed :- (1) Necrosis & shrinkage of renal glomerulus (2) Bowman's capsule damage (3) Damage of renal tubule wall (4) Separation of the inner lining of the renal tubule (5) Inflammatory cell infiltration (Hemotoxylin & Eosin-400x stain).

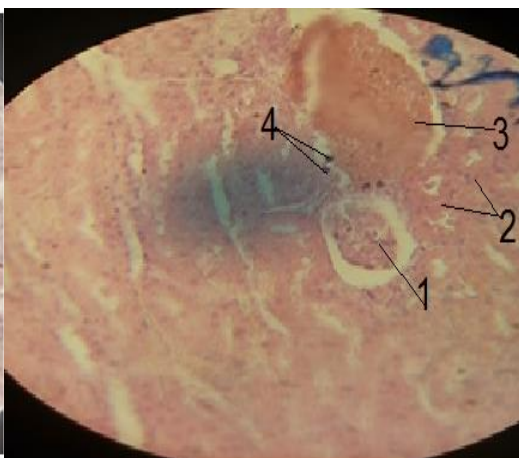


Figure (15) A cross-section in the kidney of a pregnant rat from the group treated with mebeverine drug at a concentration of 0.96 mg/kg during a 20- day pregnancy in which it is observed :- (1) Shrinkage of renal glomerulus (2) Hemorrhage into renal tubules (3) Severe hemorrhage into renal tissue (4) Inflammatory cell infiltration (Hemotoxylin & Eosin- 400x stain).

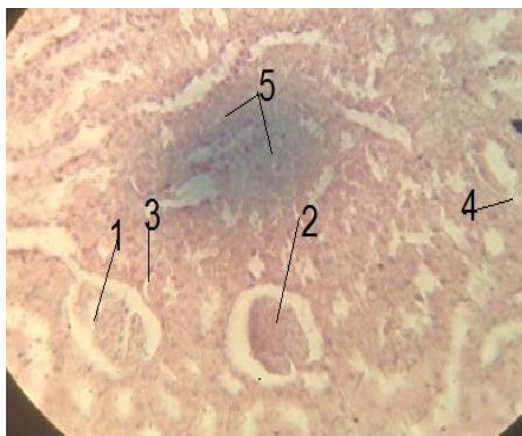

Figure (16) A cross-section in the kidney of a pregnant rat from the group treated with mebeverine drug at a concentration of 0.96 mg/kg during a 20-day pregnancy in which it is observed:- (1) Necrosis in renal glomerulus (2) Shrinkage of renal glomerulus (3) Separation of the inner lining of the renal tubule (4) Damage of renal tubule wall (5) Hemorrhage into renal tubules (Hematoxylin & Eosin-400x stain).

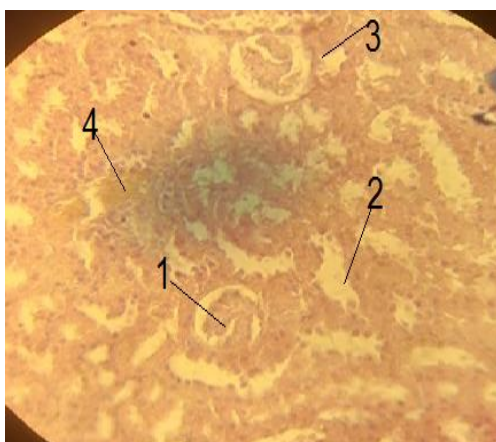


Figure (17) A cross-section in the kidney of a pregnant rat from the group treated with mebeverine drug at a concentration of 0.96 mg/kg during a 20-day pregnancy in which it is observed:- (1) Necrosis & shrinkage of renal glomerulus (2) Damage of the inner lining of the renal tubule (3) Hemorrhage into renal tubule (4) Hemorrhage into renal tissue (Hematoxylin & Eosin-400x stain).

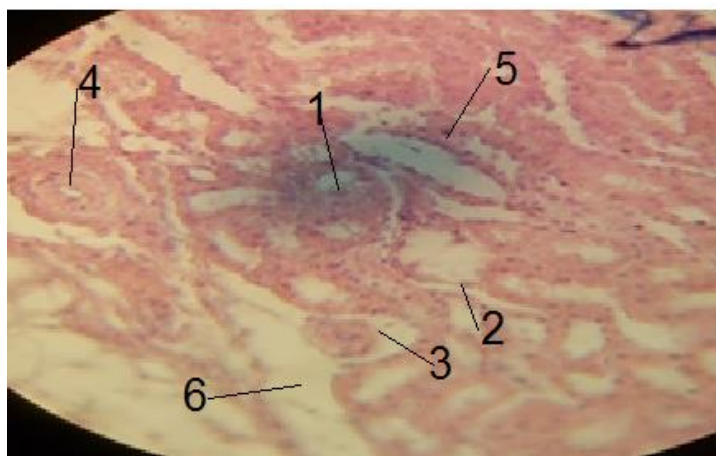


Figure (18) A cross-section in the kidney of a pregnant rat from the group treated with mebeverine drug at a concentration of 0.96 mg/kg during a 20-day pregnancy in which it is observed :- (1) Severe shrinkage of renal glomerulus (2) Renal tubule wall damage (3) Separation of the inner lining of the renal tubule (4) Enlargement of the blood vessel (5) Inflammatory cell infiltration (6) Necrosis in renal tissue (Hematoxylin & Eosin-400x stain).



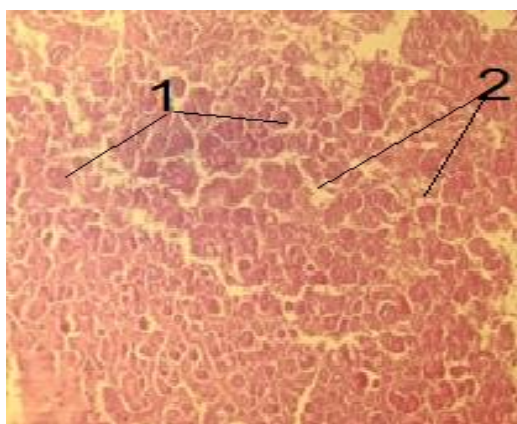


Figure (19) A cross-section in the kidney of a rat fetus from a control group during a 20 day - pregnancy in which it is observed: - (1) Renal glomeruli (2) Renal tubules (Hemotoxylin & Eosin-100x stain).

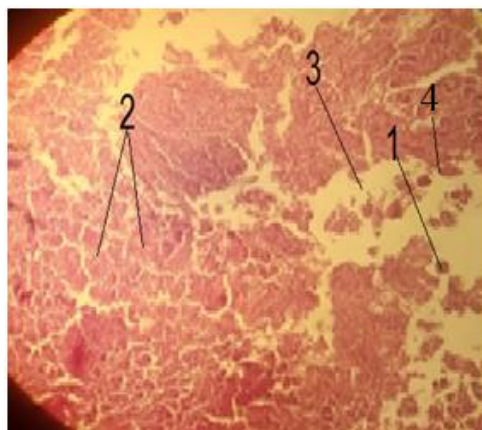


Figure (20) A cross-section in the kidney of a rat fetus from the group treated with mebeverine drug at a concentration of 0.96 mg/kg during a 20-day pregnancy in which it is observed: - (1) Shrinkage of renal glomerulus (2) Hemorrhage into renal tubules (3) Necrosis in renal tissue(4)Bowman's capsule damage (Hemotoxylin & Eosin-100x stain).

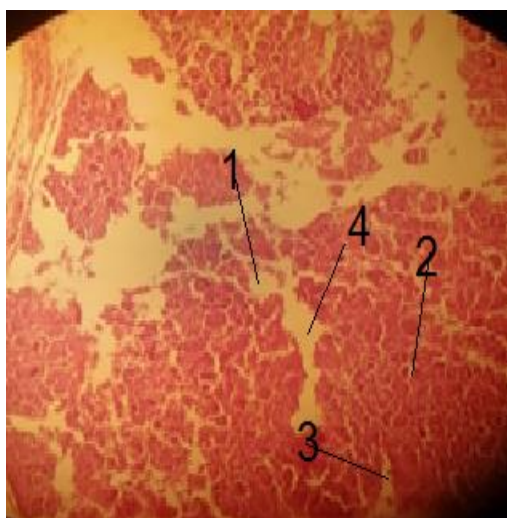


Figure (21) A cross-section in the kidney of a rat fetus from the group treated with mebeverine drug at a concentration of 0.96 mg/kg during a 20-day pregnancy in which it is observed :- (1) Damage of renal glomerulus (2) Hemorrhage into renal glomerulus(3) Hemorrhage into renal tubule (4) Necrosis in renal tissue(Hemotoxylin & Eosin-100x stain).

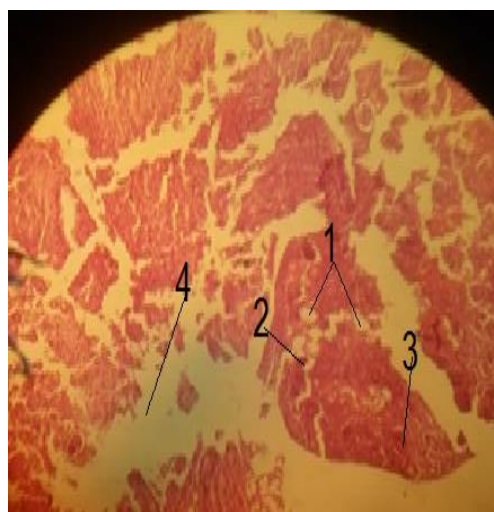


Figure (22) A cross-section in the kidney of a rat fetus from the group treated with mebeverine drug at a concentration of 0.96 mg/kg during a 20-day pregnancy in which it is observed: - (1)Damage of renal glomerulus (2) Hemorrhage into renal tubule (3) Inflammatory cell infiltration (4) Necrosis in renal tissue (Hemotoxylin & Eosin-100x stain).

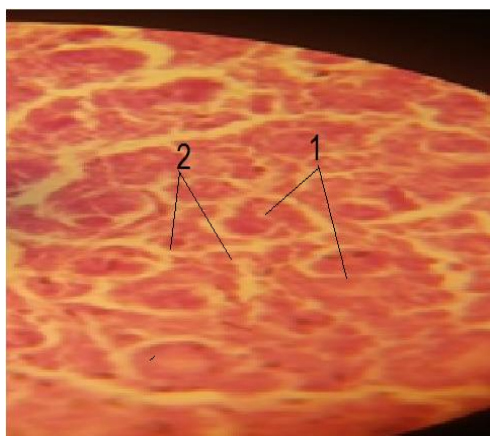


Figure (23) A cross-section in the kidney of a rat fetus from a control group during a 20 day pregnancy in which it is observed: - (1) Renal glomeruli (2) Renal tubules (Hemotoxylin & Eosin- 400x stain).

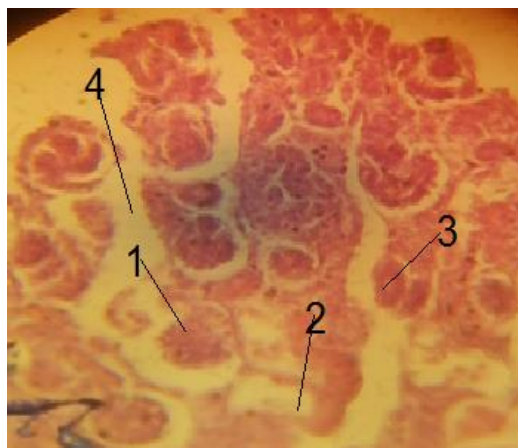


Figure (24) A cross-section in the kidney of a rat fetus from the group treated with mebeverine drug at a concentration of 0.96 mg/kg during a 20-day pregnancy in which it is observed :- (1) Shrinkage of renal glomerulus (2) Renal tubule wall damage (3) Hemorrhage into renal tubule (4) Necrosis in renal tissue(Hemotoxylin & Eosin-400x stain).

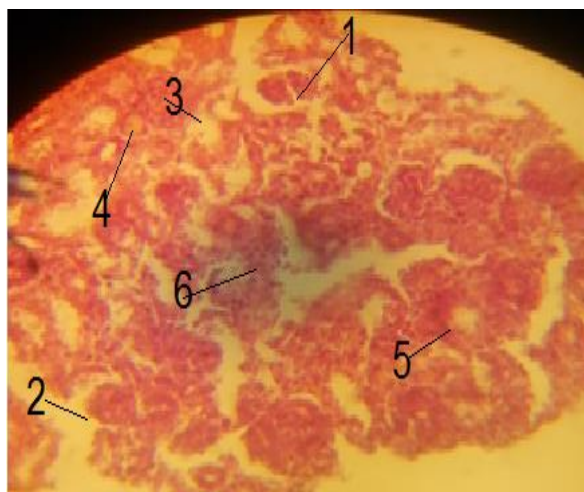


Figure (25) A cross-section in the kidney of a rat fetus from the group treated with mebeverine drug at a concentration of 0.96 mg/kg during a 20-day pregnancy in which it is observed :- (1) Necrosis in renal glomerulus(2)Bowman's capsule wall damage (3) Damage of renal tubule wall(4) Hemorrhage into renal tubule (5)Enlargement of renal tubule(6) Inflammatory cell infiltration (Hemotoxylin & Eosin-400x stain).

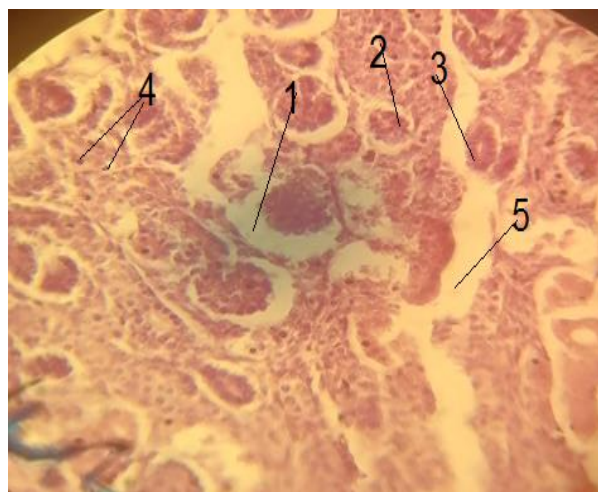


Figure (26) A cross-section in the kidney of a rat fetus from the group treated with mebeverine drug at a concentration of 0.96 mg/kg during a 20-day pregnancy in which it is observed :- (1)Bowman's capsule expansion (2) Shrinkage of renal glomerulus(3) Hemorrhage into renal tubule (4) Inflammatory cell infiltration (5)Necrosis in renal tissue(Hemotoxylin & Eosin-400x stain).



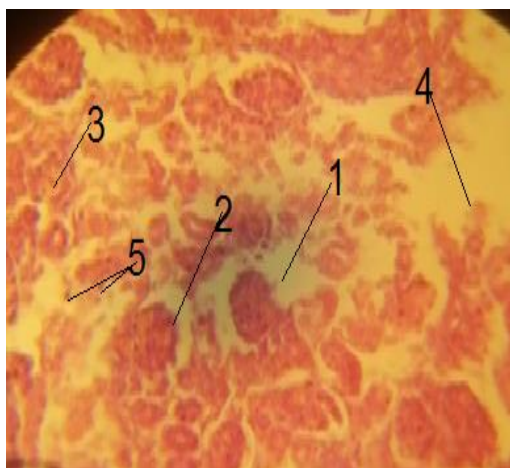


Figure (27) A cross-section in the kidney of a rat fetus from the group treated with mebeverine drug at a concentration of 0.96 mg/kg during a 20-day pregnancy in which it is observed :- (1) Shrinkage & hemorrhage of renal glomerulus (2) Hemolysis of renal glomerulus (3) Damage of renal glomerulus (4) Separation of the inner lining of the renal tubule (5) Necrosis in renal tissue (Hematoxylin & Eosin-400x stain).

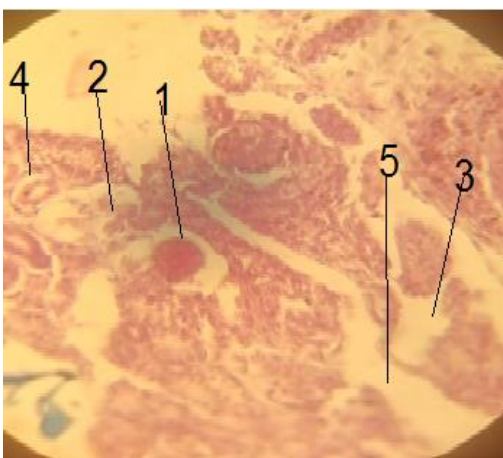


Figure (28) A cross-section in the kidney of a rat fetus from the group treated with mebeverine drug at a concentration of 0.96 mg/kg during a 20-day pregnancy in which it is observed :- (1) Bowman's capsule wall damage (2) Shrinkage of renal glomerulus (3) Damage of renal tubule wall (4) Necrosis in renal tissue (5) Inflammatory cell infiltration (Hematoxylin & Eosin-400x stain).

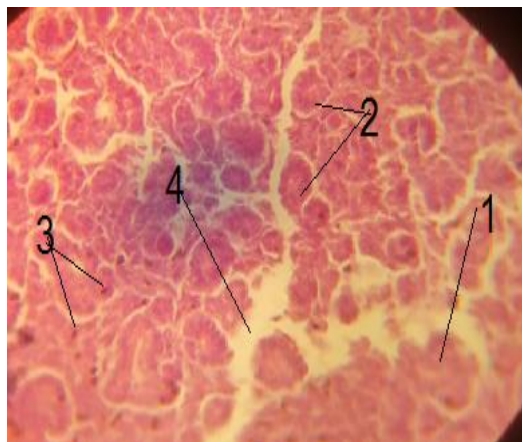

Figure (29) A cross-section in the kidney of a rat fetus from the group treated with mebeverine drug at a concentration of 0.96 mg/kg during a 20-day pregnancy in which it is observed :- (1) Bowman's capsule wall damage (2) Damage of renal glomerulus (3) Well damage & Hemorrhage into renal tubule (4) Necrosis in renal tissue (5) Inflammatory cell infiltration (Hematoxylin & Eosin-400x stain).

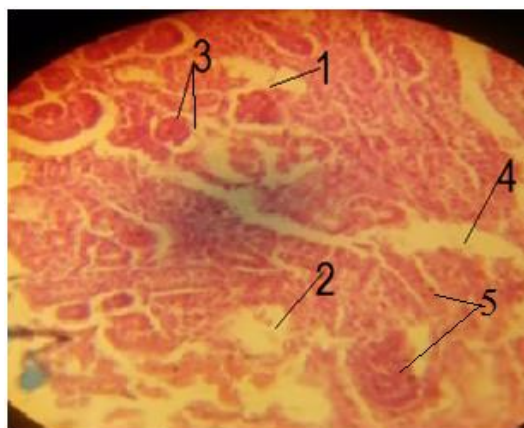


Figure (30) A cross-section in the kidney of a rat fetus from the group treated with mebeverine drug at a concentration of 0.96 mg/kg during a 20-day pregnancy in which it is observed :- (1) Necrosis in renal glomerulus (2) Bowman's capsule wall damage (3) Damage of renal tubule wall (4) Hemorrhage into renal tubule (5) Enlargement of renal tubule (6) Inflammatory cell infiltration (Hematoxylin & Eosin-400x stain).

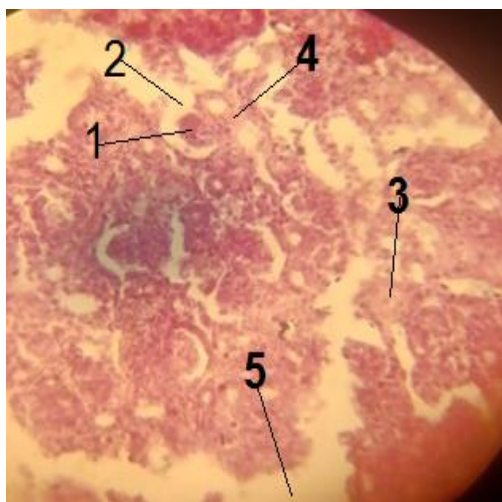

Figure (31) A cross-section in the kidney of a rat fetus from the group treated with mebeverine drug at a concentration of 0.96 mg/kg during a 20-day pregnancy in which it is observed:- (1)Shrinkage of renal glomerulus(2) Bowman's capsule well damage (3) Enlargment of the renal tubule (4) Hemorrhage into the renal tubule (5)Necrosis in renal tissue (Hemotoxylin & Eosin-400x stain).

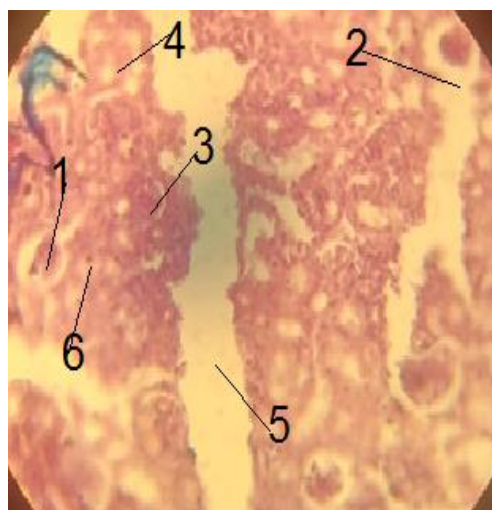


Figure (32) A cross-section in the kidney of a rat fetus from the group treated with mebeverine drug at a concentration of 0.96 mg/kg during a 20-day pregnancy in which it is observed :- (1)Necrosis &shrinkage of renal glomerulus(2) Bowman's capsule well damage (3) Hemorrhage into the renal tubule(4) Separation of the inner lining of the renal tubule (5)Necrosis in renal tissue (6) Inflammatory cell infiltration (Hemotoxylin & Eosin-400x stain).

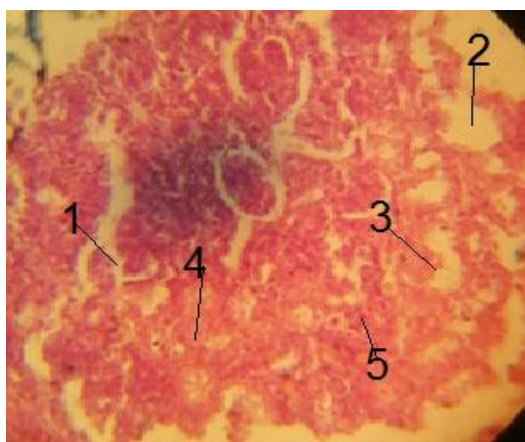

Figure (33) A cross-section in the kidney of a rat fetus from the group treated with mebeverine drug at a concentration of 0.96 mg/kg during a 20-day pregnancy in which it is observed :- (1)Necrosis &shrinkage of renal glomerulus(2) Damage of renal glomerulus (3) Separation of the inner lining of the renal tubule (4) Hemorrhage into renal tissue (5) Inflammatory cell infiltration (Hemotoxylin & Eosin-400x stain).

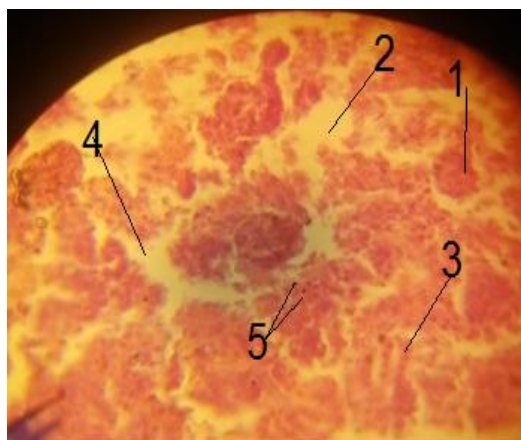


Figure (34) A cross-section in the kidney of a rat fetus from the group treated with mebeverine drug at a concentration of 0.96 mg/kg during a 20-day pregnancy in which it is observed :- (1)Shrinkage of renal glomerulus(2) Damage of renal glomerulus (3) Separation of the inner lining of the renal tubule (4)Necrosis in renal tissue (5) Inflammatory cell infiltration (Hemotoxylin & Eosin-400x stain).



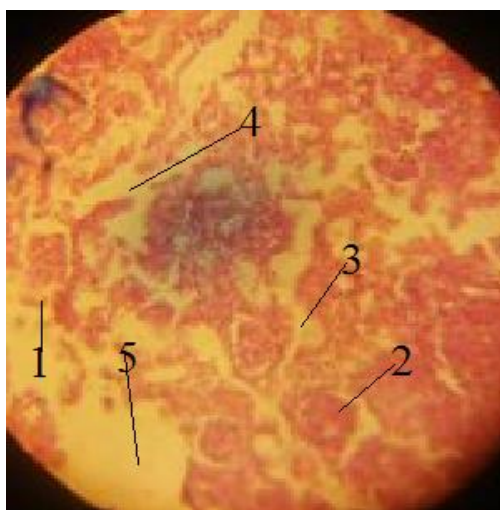


Figure (35) A cross-section in the kidney of a rat fetus from the group treated with mebeverine drug at a concentration of 0.96 mg/kg during a 20-day pregnancy in which it is observed :- (1) Bowman's capsule well damage (2) Hemorrhage into renal glomerulus (3) Damage of renal tubule (4) Necrosis in renal tissue (5) Damage of renal tissue (Hemotoxylin & Eosin-400x stain).

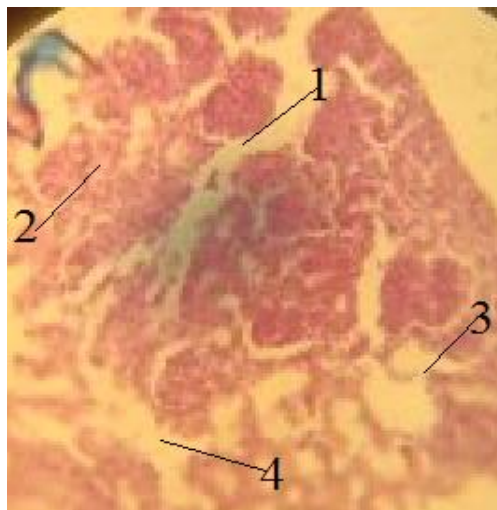


Figure (36) A cross-section in the kidney of a rat fetus from the group treated with mebeverine drug at a concentration of 0.96 mg/kg during a 20-day pregnancy in which it is observed :- (1) Bowman's capsule well damage (2) Hemorrhage into renal tissue (3) Renal tubule well damage (4) Necrosis in renal tissue (Hemotoxylin & Eosin-400x stain).

## References

1. Champer ,C.H . and Scialli ,A.R.(2014) Teratogenesis and Environmental Exposur ,in : Creasy and ResniksMaternal-Fetal medicine by Resnik, R.; Greene, M. F .;Lams ,J.D.; Lockwood , Ch .J.; Moore Th. R., seven edition . Elsevier Saunders ,Philadelphia .
2. Darvish-Damavandi, M.; Nikfar ,S. and Abdollahi, M. A.(2010). Systematic review of efficacy and tolerability of mebeverine in irritable bowel syndrome. World .J .Gastroenterol. , 16: 547-553.
3. Ensslin, H.K. ; Maurer, H.H. .; Gouzoulis, E. ; Hermle, L. and Kovar. K.A. (1996). Metabolism of racemic 3,4-methylenedioxyethylamphetamine in humans, isolation, identification, quantification, and synthesis of renal metabolites. Drug Metab. Dispos., 24:813-820.
4. Evans, P.R. ; Bak, Y.T. and Kellow. J.E. (1996).Mebeverine alters small bowel motility in irritable bowel syndrome. Aliment. PharmacolTher., 10: 787-793.
5. Annahazi, A.; Roka, R.;Rosztoczy, A. and Wittmann, T.( 2014). Role of antispasmodics in the treatment of irritable bowel syndrome. World.J.o Gastroenterology., 20 (20): 6031-6043.
6. Inauen, W.; Halter, F.( 1994). Clinical Efficacy, Safety and Tolerance of Mebeverine Slow Release (200 mg) vsMebeverine Tablets in Patients with Irritable Bowel Syndrome. Drug Investig., 8: 234-240.

7. Al-Dossary, B.N.; Al-gohary, O.M.N. and Al-Kahwaas, M.M., (2006). In vitro and in vivo availability of mebevirine hydrochloride suppositories. *Sci. Pharm.*, 74: 31-51.
8. Kristinsson, J. .; Snorraddottir, I. and M. Johannsson. (1994). The metabolism of mebevirine in man: identification of renal metabolites by gas chromatography/mass spectrometry. *Pharmacol. Toxicol.*, 74:174-180 .
9. Abdel-Hamid ,S.M.; Abdel-Hady, S.E.; El-Shamy, A.H. and El-Dessouky ,H.F.( 2007). A novel formulation for mebevirine hydrochloride. *Drug Dev Ind Pharm.*, 33: 1078-1089.
10. Hatami, K.; Kazemi-Motlagh, A.H.; Ajdarkosh, H.; Zargarani, A.; Karimi, M.; Shamshiri, A.R.; Ghadir, M.R. (2020). Comparing the Efficacy of Cumin Sofouf With Mebevirine on Irritable Bowel Syndrome Severity and Quality of Life: A Double-blind Randomized Clinical Trial. *Crescent. J. Med. Biol. Sci.*, 7:186–194.
11. Capurso -Everitt, H.; Moss-Morris, R.; Sibelli, A.; Tapp, L.; Coleman, N.; Yardley, L.; Smith, P.W.F. and Little, P. (2013). Management of irritable bowel syndrome in primary care: The results of an exploratory randomised controlled trial of mebevirine, methylcellulose, placebo and a self-management website. *BMC. Gastroenterol.*, 13: 68.
12. Rahman, M.Z.; Ahmed, D.S.; Mahmuduzzaman, M.; Chowdhury, M.S.; Barua, R.; Ishaque, S.M. (2014). Comparative efficacy and safety of trimebutine versus mebevirine in the treatment of irritable bowel syndrome. *Mymensingh .Med. J.*, 23: 105–113.
13. Baloglu, E.; Karavana, S.Y.; Hyusein, I.Y. and Kose ,T.( 2010). Design and formulation of mebevirineHCl semisolid formulations for intraorally administration. *AAPS Pharm.Sci.Tech.*, 11: 181-188.
14. Daniluk ,J.; Malecka-Wojcieszko ,E.; Skrzydlo-Radomanska ,B. and Rydzewska ,G.(2022). The Efficacy of Mebevirine in the Treatment of Irritable Bowel Syndrome—A Systematic Review. *J,Clin.Med.*, 11, 1044. <https://doi.org/10.3390/jcm11041044>.
15. Gilbody, J.S.; Fletcher, C.P.; Hughes, I.W.; Kidman, S.P. (2000). Comparison of two different formulations of mebevirine hydrochloride in irritable bowel syndrome. *Int. J. Clin. Pract.*, 54:461–464.
16. Marson, C.; Schneider, S.; Meys, F. and Wennig, R.(2000). Structural elucidation of an uncommon phenylethylamine analogue in urine responsible for discordant amphetamine immunoassay results. *J. Anal. Toxicol.*, 24:17-21.
17. Felgate, H.E.; Felgate, P.D. ; James, R.A. Sims, D.N. and Vozzo. D.C. (1998). Recent paramethoxyamphetamine deaths. *J. Anal. Toxicol.*, 22: 169-172.
18. Kraemer, T.; Bickeboeller-Friedrich, J. and Maurer. H.H. (2000). On the metabolism of the amphetamine-derived antispasmodic drug Mebevirine-GC-MS studies on rat liver microsomes and on human urine. *Drug.Metab. Dispos.*, 28:339-347 .

19. Elliott ,S. and Burgess ,V.( 2006). Investigative implications of the instability and metabolism of mebeverine. *J. Anal .Toxicol.*,30: 91-97.
20. Fox,T.;Barthold ,S.; Davisson , M .;New Comer, C.; Qumby ,F. and Smith A.(2006). *The mouse and biomedical research : Normative . Biol .Husbandry .Med . Edition . , Elsevier .*
21. Humason,G.L.(1972).*Animal tissue technique*.W.H.Freemand company ,San Francisco.
22. Schaffstein,W.; Panijel, M. and Luettecke, K. (1990).Comparative safety and efficacy of trimebutine versus mebeverine in the treatment of irritable bowel syndrome. A multicenter double-blind study.*Curr.Res.Exp.*,47:136-145.
23. Antari, N. W. S. ., Damayanti, I. A. M. ., & Wulansari, N. T. . (2021). The effectiveness testing of l-carnitine on the quality of spermatozoa and testosterone hormone in white rats (*Rattus norvegicus*) feeding with high fat. *International Journal of Health & Medical Sciences*, 4(1), 102-109. <https://doi.org/10.21744/ijhms.v4n1.1525>
24. Plmieri, C.and Conger, R. (2002).Teratogenic Potential of the newer antiepilepticdrugs. *CNS drugs.*, 16(11): 755-764.
25. Abdulhady,S.S. and Ibrahim, K. M H.(2017). Preparation and evaluation of mebeverine hydrochloride asmucoadhesivebuccal tablet for local anesthesia. *Tropical .J. Pharm, Res.*, 16 (8): 1805-1812.
26. Suryasa, I. W., Rodríguez-Gámez, M., & Koldoris, T. (2021). Get vaccinated when it is your turn and follow the local guidelines. *International Journal of Health Sciences*, 5(3), x-xv. <https://doi.org/10.53730/ijhs.v5n3.2938>
27. Kraemer ,T.; Wennig,R. and Maurer,H.H.(2001). The Antispasmodic Drug Mebeverine Leads to Positive Amphetamine Results by Fluorescence Polarization Immunoassay (FPIA) -Studies on the Toxicological Analysis of Urine by FPIA and GC-MS. *J. Anal.Toxic.*, 25: 332-338.
28. Al-Naemi, R.S.; Ab. Dullah, Q.H. and Ibrahim, S.A. (2012). Impactof oxidative stress on pregnancy outcome in albino rats. *Iraqi.J. Veter. Sci.*, 26(2):93-99.