

## ***Fagraea racemosa* leaf extract inhibits oxidative stress-induced liver damage in Wistar rats**

Eva Rachmi, Yudanti Riastiti

Laboratory of Anatomy and Histology, Faculty of Medicine, Universitas Mulawarman

### **Abstrak**

**Latar belakang:** Kemampuan hati mengatasi stres oksidatif dapat ditingkatkan dengan konsumsi antioksidan eksogen yang berasal dari alam. Penelitian ini ditujukan untuk mempelajari kemampuan hepatoprotektif dari ekstrak metanol daun *Fagraea racemosa*, dengan menggunakan  $\text{CCl}_4$  sebagai model sumber radikal bebas.

**Metode:** Tiga kelompok perlakuan tikus Wistar (enam ekor per kelompok), masing-masing diberi dosis ekstrak berturut-turut 50, 100, 200 mg/kg bb per oral, sekali sehari selama 30 hari.  $\text{CCl}_4$  diinjeksikan intraperitoneal kepada ketiga kelompok, dua kali per minggu (1,5 ml/kg bb). Sebagai pembanding, digunakan dua kelompok kontrol, yaitu kontrol normal dan kontrol  $\text{CCl}_4$ . Pada hari ke-30, tikus dibunuh dan hati diwarnai dengan hematoxilin-eosin. Perubahan histopatologi ditentukan berdasar derajat steatosis, degenerasi hidropik, dan inflamasi. Data dianalisis dengan Anova dan uji post hoc LSD ( $p \leq 0.05$ ) menggunakan SPSS versi 13.0

**Hasil:** Hasil menunjukkan perbaikan derajat degenerasi hidropik dan inflamasi ( $p \leq 0.05$ ) pada ketiga kelompok perlakuan bila dibanding dengan kelompok kontrol  $\text{CCl}_4$ . Tetapi, derajat steatosis meningkat pada kelompok perlakuan dosis 50 dan 100 mg/kg bb, dan kemudian menurun secara bermakna pada perlakuan 200 mg/kg bb.

**Kesimpulan :** Ekstrak methanol daun *Fagraea racemosa* mampu melindungi hati dari radikal bebas yang dihasilkan dari  $\text{CCl}_4$ . Hasil ini mengindikasikan bahwa *Fagraea racemosa* menjanjikan untuk dikembangkan sebagai suplemen antioksidan. (*Health Science Indones 2011;2:46-51*)

**Kata kunci:** ekstrak methanol, *Fagraea racemosa*, hepatoprotektif

### **Abstract**

**Background:** The ability of the liver in dealing with oxidative stress can be enhanced by consumption of exogenous antioxidants derived from nature. This study aimed to explore the hepatoprotective ability of *Fagraea racemosa* leaves methanolic extract against  $\text{CCl}_4$  exposure as a model of free radicals source.

**Methods:** Three different doses (50, 100, 200 mg/kg bw) were administered orally to three treatment groups of Wistar rats (six Wistar rats each), respectively, once per day for 30 days.  $\text{CCl}_4$  injected intraperitoneally to those three groups, twice a week (1,5 ml/kg bw). Two control groups were provided that were one normal control group and one  $\text{CCl}_4$  control group. On the 30<sup>th</sup> day, the rats were killed and its liver examined with Haematoxyllin eosin staining. Histopathological changes were graded based on the degree of steatosis, hydropic degeneration, and inflammation. Data were analyzed with ANOVA and LSD post hoc ( $p \leq 0.05$ ) using SPSS version 13.0

**Results:** The results showed improvement between the three treatment groups and the  $\text{CCl}_4$  control group about the degree of hydropic degeneration and inflammation ( $P \leq 0.05$ ). However, there were significant increased of steatosis 50 and 100 mg/kg bw treatment groups, before its significantly decrease at 200 mg/kg bw treatment group (2.5 g/kg).

**Conclusions:** *Fagraea racemosa* leaves methanolic extract could protect liver from free radicals generated by  $\text{CCl}_4$ . The result indicated that *Fagraea racemosa* has promising quality to be explored as antioxidant supplement. (*Health Science Indones 2011;2:46-51*)

**Key words:** methanolic extract, *Fagraea racemosa*, hepatoprotective

Submitted on 22 February, Reviewed on 4 March, Accepted on 1 April

Liver as the main organ of metabolism and detoxification have greater risk of oxidative stress than others. Various sources of free radicals in the liver produced by mitochondria in the oxidation phosphorylation process, inflammatory process, or xenobiotics metabolism (drugs and chemical substances).<sup>1</sup> In the state of excessive free radicals, endogenous antioxidants are not able to cope with oxidative stress, thus needs exogenous antioxidants from the diet.<sup>2</sup>

Borneo forest stores thousands of medicinal plants that have not been optimally utilized as an alternative medicine because of scientific evidence about the benefits and safety is still lacking.<sup>3</sup> One of the interesting plants studied is *Fagraea racemosa* Jack ex Wall (*F. racemosa*). Borneo forest is overgrown by 42 *Fragaea* species, especially in secondary forest with a lot of sunlight. *F. racemosa* can be grown in different soil types both marshy and dry, at an altitude of 0000-2000 m asl.<sup>4</sup> Some tribes use it as medicine. Dayak tribe use stems bark and root for heat-lowering medications and pain relievers. A community around Mentoko-Bontang forest in using this plant shoots as ulcer treatment. Banjar tribe use the leaves for muscles relaxant on stroke patients.<sup>5</sup>

Phytochemical and pharmacological studies on *F. racemosa* have not been much done. Biological activity tests of these extracts showed the ability of analgesics and relaxation of arteries through norepinephrin antagonism.<sup>6</sup> Another study by Purwatiningsih on chloroform and methanol extracts from roots, root barks, stems, stem barks, and leaves of *F. racemosa* by measuring DPPH reduction (2,2-diphenyl-1-picrylhydrazil), shows highest antioxidant ability of leaf extracts (74%) compared to other parts of the plant extracts. Toxicity tests of methanol leaves extracts on shrimp larvae showed lowest toxicity compared to other parts of the plant extracts.<sup>7</sup>

Antioxidant ability of *F. racemosa* leaf extracts in vitro need to be tested in vivo using liver as target organ and carbon tetrachloride ( $\text{CCl}_4$ ) as free radical generator model.  $\text{CCl}_4$  is activated in endoplasmik reticulum by hepatic cytochrome P450 to form trichloromethyl free radicals

( $\text{CCl}_3$  and / or  $\text{CCl}_3\text{OO}^\cdot$ ).<sup>8,9</sup> Covalent bond between trichloromethyl with cell protein is the first step of the chain reactions that cause lipid peroxidation and ultimately cause cell necrosis followed by inflammation process.<sup>10</sup> In addition to acute toxicity which causes tissue damage,  $\text{CCl}_4$  also caused apoptosis when administered at low or moderate doses.<sup>11</sup> Damage on cell membran induce hydropic degeneration on hepatocyte. Lipid peroxidation induce the damage to mitochondria, decreased ATP production, and damage to the sodium pump, thereby increasing the intracellular osmotic pressure.<sup>12</sup> Effective antioxidant capacity of *F. racemosa* leaves extract in vivo will inhibit development of liver damage which indicated by milder necrosis, inflammation, dan hydropic degeneration.

This study aimed to explore the hepatoprotective ability of *F. racemosa* leaves methanolic extract against  $\text{CCl}_4$  exposure as a model of free radicals source.

## METHODS

An experimental study was conducted on female Wistar rats (average age 2 months, body weight 150-200 g) during January–May 2008.

Leaves of *F. racemosa* was collected from forest around Balikpapan town, part of East Kalimantan during February 2008, The taxonomic identification of plant materials was determined by an ethnobotany expert from Wanariset, Balikpapan. The *F. racemosa* leaves were dried in shade at room temperature and then ground to a fine powder with mechanic grinder. Then the powdered plant materials soaked with methanol 80% (PA from Merck) overnight, which is repeated several times until the solvent was clear. After the filtration of the solvent, the organic phases were independently concentrated under vacuum evaporator at 80° C.

The process produced pasta extract that stored at 4°C until used. The whole process of extraction took place at Forestry Laboratory Universitas Mulawarman, and the rest of the process carried out at Pharmacology Laboratory of Universitas Brawijaya.

Wistar rats were obtained from Biology Laboratory of Universitas Brawijaya, which were acclimatized for 14 days in a 12 h light/dark cycle at a constant room temperature with free access to standard pellet food and tap water. All experiments were carried out according to the guidelines for the care and use of experimental animals.<sup>13</sup> The protocol was approved by Pharmacology Laboratory of Universitas Brawijaya

The animals were randomly divided into 5 groups of six Wistar rats each. Group I was maintained as normal control received distilled aqua 5 ml/kg bw orally. All the animals of group II to V received CCl<sub>4</sub> (Merck, diluted 1:1 with corn oil) at dose of 1.5 ml/kg intraperitoneally for twice a week. Group II animals were maintained as CCl<sub>4</sub> control without any extract treatment. Group III, IV and V animals were treated with methanolic extract 50, 100 and 200 mg/kg body weight, respectively by oral route. The methanolic extract was solved in destiled aqua (1:1) and administered from the first day of experiment. Administration of CCl<sub>4</sub> was started at the fifth (5<sup>th</sup>) day. During the period of drug treatment the rats were maintained under normal diet and water ad libitum.

The animals of all the groups were sacrificed by ketamine anesthesia (1 mg/kg BW on 30<sup>th</sup> day).<sup>14</sup> Livers were removed and preserved in 10% formalin solution for histopathological studies.

Liver tissues collected were used for the preparation of histopathological slides by using microtome and were suitably stained and observed under microscope for architectural changes. Liver tissue was processed by the paraffin slice technique and sections were stained with hematoxylin and eosin according to the commonly used van Gieson's method.

The stained slices of liver tissue were subjected to the evaluation of steatosis, hydropic degeneration, and inflammation. Steatosis (fatty degeneration) was evaluated based on the number of cells containing fat droplets (foam cell) per 500 cells in one lobule, at 400x magnification. Hydropic degeneration was determined by the number of cells contained

hydropic vacuole per 500 cells in one lobule, 400 x magnifications. Both were modification from steatohepatitis grading by Brunt.<sup>15</sup> The level of inflammation was evaluated based on the number of lobules infiltrated by dense leukocytes using 100 x magnification, which was modification of Knodell criteria.<sup>16</sup> Calculations for every slide performed with 3 replicates in different areas, using the same magnification.

The mean  $\pm$  S.E.M. was calculated for each parameter. Total variations, present in a set of data were estimated by one way analysis of variance (ANOVA), followed by Least Significance Different (LSD) test. SPSS version 13 was used as statistical software.

## RESULTS

During the study, no experimental animals were died. The average increase in animal's body weight was between 10-20 grams per week. Weight gain was followed by adjusting the dose of extract and CCl<sub>4</sub>.

The liver of rats in first group had normal architecture, cords of hepatocyte well preserved, cytoplasm not vacuolated, sinusoid well demarcated, no fatty change, no fatty degeneration and no area of infiltration by inflammatory cells (Figure 1a). Figure 1b demonstrated that CCl<sub>4</sub> (compared to normal control group) induces fat droplet, hydropic vacuolation of cytoplasm, distended hepatocytes, compression of sinusoids, and nuclear pyknosis.

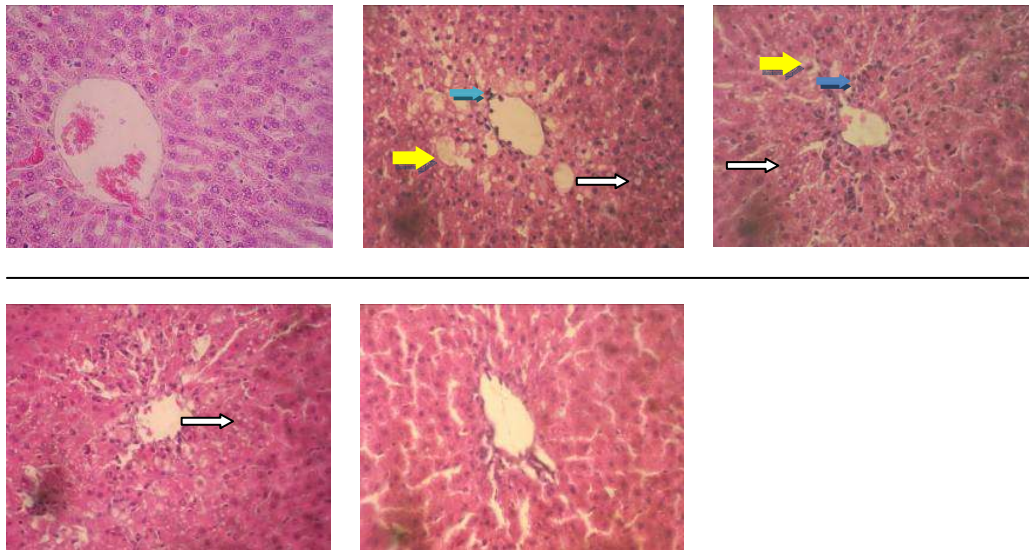
Administration of methanolic *F. racemosa* leaves extract to the test groups (Fig. 1c, 1d and 1e) generally showed improvement when compared with CCl<sub>4</sub> treated control group. The biggest extract dose in these experiment (200 ml/kg) showed minimal damage after induced by CCl<sub>4</sub>.

At the end of the 30<sup>th</sup> day treatment, liver tissue of CCl<sub>4</sub> treated control group showed significant increase in the level of hydropic degeneration, steatosis and inflammation compare to normal control. Pretreatment with *F. racemosa* extract at 50 and 100 mg/kgBW showed marked

decreased of hydropic degeneration and inflammation as compared to the CCl<sub>4</sub> treated group ( $p<0.05$ ). The maximum protection was shown by methanolic extract at the dose of 200 mg/kg bw (Table 1).

*F. racemosa* extract treatment groups at dose 50 and 100 mg/kgBW induced higher steatosis (35% and 23%, respectively) than CCl<sub>4</sub> treated control group, even though hydropic degene-

ration and inflammation degree decreased. But at the dose 200 mg/kgBW, *F. racemosa* extract reduced steatosis matched with the decrease of hydropic degeneration and inflammation. Dose 200 mg/kg bw was also proven to reduce hydropic degeneration and inflammation optimally almost in the level of normal control group, only steatosis level remained significantly different from the normal control group ( $p<0.05$ ).



**Figure 1. Histological image of liver**

(A) normal control group; (B) CCl<sub>4</sub> control group; Next picture are (C) 50 mg/kgBW; (D) 100 mg/kgBW, and 200 mg/kgBW (E) *F. racemosa* extract treated groups

White arrow: steatotic cell, Yellow arrow: hydropic degenerate cell, Blue arrow: inflammatory cell

Table 1. Interplay between treatment of methanolic extract *F. racemosa* leaves with liver histological change

Groups	Hydropic degeneration (cells/field of view)	Steatosis (cells/field of view)	Dense inflammation (lobule/field of view)
I (Normal)	0	0	0
II (CCl <sub>4</sub> )	46.75±6.5*	19.5±1.7321*	6±2*
III (CCl <sub>4</sub> + <i>F. racemosa</i> 50 mg/kg bw)	12.5±2.0817*,†	26.3±1.2583*,†	1.75±0.5*,†
IV (CCl <sub>4</sub> + <i>F. racemosa</i> 100 mg/kg bw)	6.75±0.9574†,‡	24±0.8165*,†,‡	0*,†
V (CCl <sub>4</sub> + <i>F. racemosa</i> 200 mg/kg bw)	1.5±0.5773†,‡,§	9.3±0.5*,†,‡,§	0*,†

LSD statistical analytics ( $p<0,05$ ) which significantly different result from:

\*group I; †group II; ‡group III; §group IV

## DISCUSSION

Wistar rats were selected as experimental animals because it widely recognized as the most important model for human diseases and disorders. They comprise the majority of all experimental mammals and tend to be the model of choice used for research into many diseases/disorders.<sup>17</sup> Rat variations were limited by selected the same gender, and also more or less the same age and body weight.

*F. racemosa* extract administration five days prior to treatment was intended to reach optimal and stable *F. racemosa* extract's blood level given CCl<sub>4</sub> (on the fifth day of the study). This method will clarify the preventive effects of *F. racemosa* extracts. The research was only tried out 3 doses so the effects of extracts of *F. racemosa* at higher doses were not analyzed.

Exposure to CCl<sub>4</sub> in group II showed clear intracellular vacuoles which might contain lipids. These vacuoles appear clear because of the embedding process (before haematoxylin-eosin staining) used solvents that dissolve lipids. Accumulation of intracellular lipids occurs because the reactive metabolites of CCl<sub>4</sub> (CCl<sub>3</sub><sup>•</sup>, CCl<sub>3</sub>O<sub>2</sub><sup>•</sup>) caused lipid peroxidation of rough endoplasmic reticulum (RER) membrane that resulted on released poliribosom attached to it, separated into single ribosomes. Structured damage of poliribosom disrupts the production apoprotein which make lipid cannot be transported out of hepatocytes. In the early stages of exposure, lipids accumulate in the smooth endoplasmic reticulum (SER), which appear as small vacuoles in the cytoplasm. If the process continues, the vacuole will enlarge and pushed the nucleus to the periphery.<sup>18</sup>

Histologic change in the form of liver cells swelling with clear cytoplasm (hydropic degeneration) at the transition area between healthy and necrotic area, also occurs in CCl<sub>4</sub> exposure.<sup>19</sup> Hydropic degeneration caused by increased membrane permeability due to lipid peroxidation, resulting in electrolyte imbalance and drive intercellular fluid into intracellular.<sup>20</sup> Importation of water causes the cells to swell three times normal size, and depressed nucleus at the center of the cell and become pyknotic. In addition, inflammatory cells mainly

lymphocytes and neutrophil infiltrate perisentral and periportal. Research by Venukumar in rats exposed to CCl<sub>4</sub> for 13 weeks, causes changes such as steatosis, necrosis sentrilobular, hydropic degeneration (ballooning), and fibrosis.<sup>21</sup>

The degree of steatosis was significantly increased in treatment groups of *F. racemosa* leaf extract dose 50 and 100 mg/kg bw, eventhough hydropic degeneration and inflammation decreased. The degree of steatosis seen increases may be caused by inhibition of hydropic degeneration so that the cells contained lipid droplet can be seen clearly without covered by hydropic vacuoles in it. These result was because the *F. racemosa* leaf extract can catch metabolite trichloromethyl so it's not damaging the plasma membrane that prevent hydropic degeneration, but still could damaging endoplasmik reticulum membrane immediately after formed from CCl<sub>4</sub> biotrans- formation process that induce steatosis. Its indicate that at dose 50 and 100 mg/kg bw, *F. racemosa* leaf extract only sufficient to block free radical that emerge at cytoplasm.

At dose of 200 mg/ kg bw, there was inhibition of lipid peroxidation in both plasma membrane and poliribosom, showed by fewer foam cells and hydropic degeneration. A clearer marker of antioxidant potential of *F. racemosa* leaf extracts was 100 % inhibition of dense inflammation cells formation at doses of 50 and 100 mg/kg bw compared to CCl<sub>4</sub> control group. The absence of dense inflammation cells could be interpreted as the absence of necrosis.

In conclusion, methanolic extract of *F. racemosa* leaf can inhibit liver damage induced by CCl<sub>4</sub>. Mechanism of liver damage caused by CCl<sub>4</sub> is through the formation of free radicals, which allegedly scavenge by methanolic extract of *F. racemosa* leaf working as scavenger of free radicals.

## Acknowledgement

The authors WOULD like to thank to Pharmacology laboratory of Universitas Brawijaya for supporting this study.

## REFERENCES

- Halliwell B, Gutteridge J. Free radical in biology and medicine, 3th ed. Oxford: New York; 1998.
- Gey KF. Vitamins E plus C and interacting conutrients required for optimal health. A critical and constructive review of epidemiology and supplementation data regarding cardiovascular disease and cancer. *Biofactors*. 1987;1-2:113-74.
- Hargono D. The development of policy, guidance, and control of Traditional Medicine. Presented at the Scientific Meeting of Plant Medicine II, 28 September 1994. Jakarta, Indonesian.
- Keßler PJA, Sidiyasa K. Trees of the Balikpapan-Samarinda area, East Kalimantan, Indonesia: a manual to 280 selected species. Wageningen: The Tropenbos Foundation; 1994. Indonesian.
- Kulip JA. Preliminary survey of traditional medicinal plants in the west coast and interior of Sabah. 2000. [cited 2008 July 03]. Available from <http://www.borneofocus.com/vaic/R&D/articles.html>
- Okuyama E, Suzumura K, Yamazaki M. Pharmacological Active components of *Todo-pon Puok* (*Fagraea racemosa*), a Medicinal Plant from Borneo, *ChemPharmBull*. 1995; 43:2200-4.
- Purwatiningsih S. Studi Activity and chemical content of *Fagraea racemosa* Jack ex Wall: Laboratory experimental research [thesis]. Surabaya. Universitas Airlangga. 2003. Indonesian.
- Jeong HG, You HJ, Park SJ. Hepatoprotective effects of 18 $\beta$ -Glycyrrhetic acid on Carbon tetrachloride-induced liver injury: inhibition of Cytochrome P450 2E1 expression. *Pharmacological Research*. 2002;46:221-7.
- Ulicna O, Greksak SJ, Vancova O. Hepatoprotective effect of Rooibos tea (*Aspalathus linearis*) on CCl<sub>4</sub>-induced liver damage in rats. *Physiol. Res*. 2003;52:461-6. Andrews LS, Snyder R, Casarett et al. *Toxicology: the basic science of poison*, 4<sup>th</sup> ed. New York; Pergamon Press: 1991.
- Shi J, Aisaki K, Ikawa Y, Wake K. Evidence of hepatocyte apoptosis in rat liver after the administration of Carbon tetrachloride, *American J Pathology*. 1998. 153;2:514-25.
- Cabana EM. Cellular degeneration and infiltration. College of Veterinary Science and Medicine. 2003. Nueva Ecija, Philippines. [Cited 2008 December 12]. Available from <http://www.mozcom.com/~emcdvm/path01.html>
- CPCSEA Guidelines for laboratory animal facility. *Indian J Pharmacology*. 2003;35:257-74.
- Minister of Agriculture Prevention of Cruelty to Animal. Code of practice for the housing and care of laboratory mice, rats, guinea pigs and rabbit. Victorian Government Gazette, 16 December 2004. Department of Primary Industries, The State of Victoria.
- Brunt EM. Nonalcoholic steatohepatitis: Definition and pathology. *Semin Liv Dis*. 2001;21:3-16.
- Knodell RG, Ishak KG, Black WC. Formulation and application of a numerical scoring system for assessing histological activity in asymptomatic chronic active hepatitis. *Hepatology*. 1981;1:431-5.
- Hedrich HJ, Bullock GR. The laboratory mouse : The handbook of experimental animals. San Diego (Ca). Academic Press. 2004.
- Schiff Alpers DH, Sabesin SM, White HM. Fatty liver: biochemical and clinical aspects. In: Schiff L, Schiff ER, editors. *Diseases of the liver*. Philadelphia: JB Lippincott; 1993. p. 825-5.
- Lauria P, Sharma VN, Vanjani S, et al.. The Effect of *Luffa Echinata* in Liver Injury, *Indian J Pharmacology*. 1976;8:129-33.
- Cotran RS, Kumar V, Collins T. Robbins Pathologic basis of disease. Philadelphia: WB Saunders. 2000.
- Venukumar MR, Latha MS. Hepatoprotective effect of the methanolic extract of *Curculigo orchoides* in CCl<sub>4</sub> -treated male rats, *Indian Journal of Pharmacology*. 2002;34:269-75.