

Original Article

# COVID-19 in Combination with HLH in a Child with Severe Aplastic Anemia

Alireza Jenabzadeh<sup>1</sup>, Mohammad Naghibi<sup>2</sup>, and Farzan Safi Dahaj<sup>3\*</sup>

<sup>1</sup>Assistant Professor, Hematology and Oncology Research Center, Shahid Sadoughi University of Medical Sciences, Yazd, Iran

<sup>2</sup>Pediatric Resident, School of Medicine, Shahid Sadoughi University of Medical Sciences, Yazd, Iran

<sup>3</sup>Student Research Committee, Shahid Sadoughi University of Medical Sciences, Yazd, Iran

**ORCID:**

Alireza Jenabzadeh: <https://orcid.org/0000-0001-8831-9611>

Mohammad Naghibi: <https://orcid.org/0000-0002-8534-7438>

## Abstract

Since December 2019, the coronavirus (COVID-19) has spread all over the world. This disease may present differently in immune-compromised persons. Some of the virus's impacts have yet to be identified. In this case report, we report a three-year-and-three-month-old child with aplastic anemia who was concurrently infected with COVID-19 and HLH (hemophagocytic lymphohistiocytosis). She was referred to our center for further investigation of aplastic anemia with concurrent fever. Through examination due to splenomegaly, more evaluations were done. During admission, the PCR test for COVID-19 became positive, however, because of the fulfillment of the HLH criteria, she was diagnosed with this disease development. She was treated for HLH with IVIG and Dexamethasone while getting COVID-19 treatment. Following medicines and follow-up, her WBC and Hb count started to rise, aside from the PLT count. She continues to receive PLTs because of her thrombocytopenia till a suitable donor for BMT (Bone Marrow Transplant) is found. This case scenario highlights the COVID-19 concurrent complications for paying attention to underlying disease for better diagnosis and management.

Corresponding Author:  
Farzan Safi Dahaj; email:  
[safi.farzan@yahoo.com](mailto:safi.farzan@yahoo.com)

Received 16 November 2021  
Accepted 28 February 2022  
Published 31 March 2022

Production and Hosting by  
Knowledge E

© Alireza Jenabzadeh et al. This article is distributed under the terms of the Creative Commons Attribution License, which permits unrestricted use and redistribution provided that the original author and source are credited.

Editor-in-Chief:  
Prof. Mohammad A. M. Ibnouf

**Keywords:** COVID-19, pediatrics, pancytopenia, aplastic anemia

## 1. Introduction

The coronavirus disease 2019 (COVID-19), caused by Coronavirus-2 (SARS-CoV-2), has been spreading around the world since December 2019. It was declared a pandemic by the WHO in March 2020 [1].

COVID-19 affects every patient in different ways. Children are less likely to be associated with an increased risk of serious disease than adults. Of note, the mortality rate for this population is estimated to be <1% [2]. In addition, infected individuals with COVID-19 appear to have a reduced risk of immune deficiency than those with other underlying diseases. It also had better outcomes compared to other comorbidities [1, 3, 4].

## OPEN ACCESS

Studies have reported fulfillment of secondary hemophagocytic lymphohistiocytosis (sHLH) diagnostic criteria in some individuals with COVID-19. As a result, COVID-19 might cause sHLH [1, 4]. Patients with this condition have a sudden onset of fever, cytopenia, coagulopathy, increased transaminase levels, hyperferritinemia, and multi-organ dysfunction. The mainstays of treatment include chemotherapy, glucocorticoids, and intravenous immunoglobulin (IVIG) [1, 2, 4, 5].

Except for the studies by Adel and Magdy [1] and Mostafavi *et al.* [4], there has been no case of HLH coexisting with severe aplastic anemia in a child infected with COVID-19. In this case report, we report a three-year-and-three-month-old child with aplastic anemia who was concurrently infected with COVID-19 and HLH.

## 2. Case Report

### 2.1. History and examination

A three-year-and-three-month-old girl presented to the hospital with a fever. Her medical records from a month earlier at a different facility showed signs of weakness and lethargy. It should be noted that once the doctors discovered pancytopenia, they did an aspiration and a bone marrow biopsy. The pathological findings of a bone marrow test done a month earlier revealed that the child had aplastic anemia. The child had a fever when she came to our center, and the spleen was touched below the ribs during the examination. The child had pancytopenia (WBCs: 700 cells/ $\mu$ l, 5% neutrophils, and 95% lymphocytes [ANC: 35, ALC: 665 cells/ $\mu$ l], Hb: 10.2 gr/dl, and PLTs: 39,000 cells/ $\mu$ l). A consultation with endocrinology, infectious disease, and immunology services was done to examine the possible causes of aplastic anemia. Among the infectious causes tested for, viral agents such as EBV, CMV, HBV, HCV, HIV, HAV, VZV, parvovirus B19, Mumps, Rubella, and Influenza were requested; however, only parvovirus B19 IgM and IgG were positive, which were also excluded when the PCR results were provided. This indicates that parvovirus B19 was not detected. Furthermore, blood culture was sent using the BACTEC method, which was reported to be negative, and the chromosomal fragility test with suspicion of Fanconi anemia (FA) was also sent, which was also reported to be negative (fragility test was not increased).

The patient developed a fever on the first day of admission and tested positive for COVID-19. We found no signs of lung disease throughout the examinations, and she did not have tachypnea, asthma, or respiratory distress. Chest X-ray revealed a normal lung field and a normal mediastinum (Figure 1). Given that spleen enlargement should not

occur in aplastic anemia, if such enlargement is found, the reasons for splenomegaly should be explored. We further investigated the reasons for the spleen enlargement, and eventually, based on the HLH criteria, we arrived at the following diagnosis: the kid had a fever, bicytopenia, splenomegaly, ferritin >500 (6382 ng/ml), fasting triglyceride >265 mg/dl, and malignancy signs in a chest X-ray, abdomen ultrasound, and bone marrow aspiration and biopsy. It should be noted, however, that fibrinogen was found to be normal (586 mg/dl).

Because the child was also diagnosed with aplastic anemia, injecting Etoposide was deemed inappropriate for her. Dexamethasone (10 mg/m<sup>2</sup>; two weeks) and IVIG (0.5 gr/kg/day; four doses) were also used to treat HLH. Of course, the doctors requested Interleukin-6 for the patient, so that if the child's condition is suitable and there is a justification for the use of Tocilizumab based on the IL-6 level, this medicine can be used to treat both HLH and COVID-19. However, because its level was 1.0 pg/ml and the IL-6 level was normal (normal range: 7 pg/mL), we did not utilize this medication. At the same time, a consultation with the pediatric infectious disease service was done for the treatment of COVID-19, and based on the results, the interferon  $\beta$ -1a and Lopinavir/Ritonavir were continued for five days. After the COVID-19 treatment time elapsed and given the child's overall good health, she was discharged, but she remained under medical care for bone marrow condition and the requirement to get packed cells and platelets. The child's WBC began to increase approximately three months after the diagnosis of aplastic anemia (two months after the first visit to this facility), and the WBC returned to normal after three and a half months (trends of laboratory findings in this patient is shown in Table 1).

Almost simultaneously with the increase in WBC, the child's Hb increased, so that the last time she received packed cells was about three-and-a-half months after the onset of aplastic anemia (or, to put it another way, two-and-a-half months after her first visit to this center), but the number of platelets continued to decrease. Platelets were given to the child two or three times each week. The child's chance to receive platelets was limited by a platelet count of fewer than 10,000 or uncontrolled hemorrhage. Infectious, endocrine, rheumatology, and immunology consultations were done immediately after diagnosis to determine the underlying causes of HLH, but no diagnosis was made. Given that the child had received platelets for about six months, HLA typing was performed for the child and her family to undergo bone marrow transplantation. There was, however, no full-match donor. On the other hand, because chronic aplastic anemia necessitates bone marrow transplantation, genetic HLH tests were expensive for the family and didn't make a significant difference in therapy, therefore we didn't examine

TABLE 1: Laboratory findings related to the patient.

Index/Day	14 days before admission	Admission Day 0	Day 1	Day 2	Day 3	Day 4	Day 6	Day discharge 9	34 days after discharge	50 days after discharge	147 days after discharge
WBC (reference 3700–10000_103 cells/_L)	3300	700	1100	1600	–	–	1200	600	1200	2100	7600
Neutrophil, %	35	5	–	–	–	–	–	–	–	28.7	72.2
Lymphocyte, %	65	95	–	–	–	–	88.6	–	–	52.8	22.7
Hemoglobin (reference 10.5–13.5 g/dL)	9.9	10.2	9.4	8	–	–	9.1	9	9.8	7	10.9
Platelet count (reference 150.0–450.0_103 cells/_L)	13000	39000	5000	16000	–	–	14000	40000	19000	17000	63000
Retic, %	–	–	–	0.2	–	–	–	–	–	–	–
Fibrinogen (reference 200–400 mg/dL)	–	–	–	–	586	412	–	–	429	–	–
Triglycerides (normal fasting < 265 mg/dL)	–	–	–	–	–	353	443	–	285	–	–
Ferritin (reference 7–140 ng/mL)	–	–	–	–	6382	>1500	–	–	–	–	–
C-reactive protein	–	–	2+	1+	–	–	–	–	2+	2+	2+
ESR 1st h (reference <15/1st h)	–	–	–	98	–	–	–	–	–	104	–
Urea, mg/dLa	–	–	35	–	–	–	–	–	–	–	26
Creatinin, mg/dLa	–	–	0.5	–	–	–	–	–	–	–	0.4
RT-PCR for SARS-CoV-2	–	–	Pos	–	–	–	–	Neg	–	–	–

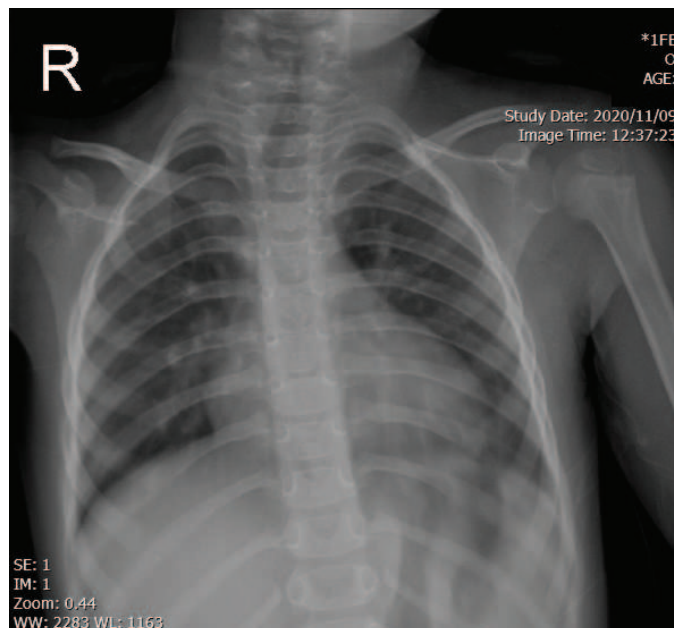
**SARS-CoV-2: severe acute respiratory syndrome coronavirus 2.**

the underlying HLH genes (if the HLH had a genetic basis, we would recommend bone marrow transplantation).

At the time of writing this paper, the child was under medical care for the need to receive platelets, and our next step was to find a suitable donor for bone marrow transplantation; if no suitable donor was found, we will consider medicinal therapies.

### 3. Discussion

Children of any age can become infected with COVID-19. According to the Centers for Disease Control and Prevention (CDC), around 12–14% of confirmed coronavirus infections are children under the age of 18. It is also worth noting that the mortality rate for this group is believed to be <1%. Moreover, children are less prone than adults to be impacted by the major disease [2]. In Egypt, Adel and Magdy reported confirmed



**Figure 1:** Chest radiograph of the three-year-and-three-month-old child with aplastic anemia (day 1 of hospitalization).

COVID-19 with sHLH in a 71-day-old infant whose symptoms worsened in about a week and who died because of vasoplegic shock development [1]. Mostafavi *et al.* reported an 18-month-old boy who developed COVID-19-induced sHLH and successfully recovered from sHLH and COVID-19 in Isfahan, Iran [4]. This report also explains the case of a three-year-and-three-month-old child who had COVID-19 and HLH simultaneously, and recovered from the disease, except for thrombocytopenia.

The reason for the reduced severity of COVID-19 in children is unknown. One possible explanation for this condition is that children have a poorer immune response to coronavirus [6–8]. Among other factors, we may note the various expressions of angiotensin-converting enzyme receptor, which is one of the coronavirus's potentially harmful mechanisms in children's respiratory systems [9]. Furthermore, lowering the likelihood of children's exposure or limiting the frequency of their tests are reasons for this problem. Other explanations include viral involvement in the respiratory system, which has lowered COVID-19 virus accumulation in their respiratory system [10]. Similar to the Egyptian child with COVID-19 and HLH, in this study, the reported case had no symptoms of respiratory tract involvement or hypoxemia while there was mild respiratory tract involvement and hypoxemia reported by Mostafavi *et al.* However, symptoms in the Egyptian case got worse and led to patient's death, while the case from Isfahan recovered from hypoxemia and invasive ventilation [1, 4]. Our case also developed non-respiratory-involved COVID-19 with disturbances in hematologic indexes.

Although immune system insufficiency has been considered as an underlying cause of COVID-19 in some of these reports, the link between immune-deficiency patients and severe COVID-19 cases has yet to be reported [11]. It appears that the probability of immunological insufficiency in patients infected with COVID-19 is lower than in those with other underlying illnesses. It also had better outcomes compared to other comorbidities [2, 6–9].

In limited research on children with COVID-19, the severity of the disease was observed to be low when immunosuppressive medications were administered to kidney transplant and inflammatory bowel disease patients [12, 13]. In a study of 187 children aged two to four years with cancer in New York, only 20 tests were found to be positive, and 1 of them required hospitalization. The study also revealed that as compared to the general population, this group is less prone to COVID-19 infection and its adverse effects [11]. In Filocamo *et al.*'s study on children suffering from COVID-19 and receiving immunosuppressive medications for rheumatology illness, it was discovered that this group is not at a greater risk of severe COVID-19 respiratory complications or life-threatening consequences [14].

In this case report, a child referred to the health facility with aplastic anemia was diagnosed with HLH and COVID-19. Among the reasons (Drug, sHLH, infection with viruses [EBV, CMV, HBV, HCV, HIV, HAV, VZV, parvovirus B19, Mumps, Rubella, and Influenza], and malignancy) for aplastic anemia, because of the splenomegaly and the increase in liver transaminases, triglycerides, and ferritin, we suspected the HLH. While the treatment for HLH is chemotherapy with etoposide and glucocorticoids and IVIG, in this case, due to the aplastic anemia, Dexamethasone and IVIG were used, besides interferon  $\beta$ -1a and Lopinavir/Ritonavir as the national protocol for COVID-19 treatment. Except for the hydroxychloroquine, the same treatment regimens were used for COVID-19 and HLH treatment in our and Mostafavi *et al.*'s patients. Neither ours nor Mostafavi *et al.*'s study used Tocilizumab because of the normal level of IL-6 [4].

## 4. Conclusion

The symptoms of COVID-19 in our patient were very mild due to the low number of WBCs and, as a result, released cytokines. Children may experience nonspecific COVID-19 symptoms, so keeping an open mind is important. We suggest that further extensive research in the field of COVID-19 and HLH be performed in light of the literature.

## Acknowledgements

Nil.

## Ethical Considerations

This study was approved by Yazd Shahid Sadoughi Medical Science University ethics commission (Code: IR.SSU.MEDICINE.REC.1400.180). Also, written informed consent to publish the information was obtained from the patient's legal guardians.

## Competing Interests

Nil.

## Availability of Data and Material

The authors confirm that all relevant data are included in the article and/or its supplementary information files.

## Funding

None.

## References

- [1] Adel, M. and Magdy, A. (2021). SARS-CoV-2 infection in an infant with non-respiratory manifestations: A case report. *Egyptian Pediatric Association Gazette*, vol. 69, no. 1, p. 3.
- [2] Deville, J. G., Song, E., and Ouellette, C. P. (2021). *COVID-19: Clinical manifestations and diagnosis in children*. UpToDate.
- [3] Akçabelen, Y., Yozgat, A. K., Ozkaya-Parlakay, A., et al. (2020). *COVID-19 in a child with severe aplastic anemia*. Authorea Preprints.
- [4] Mostafavi, S. N., Sadeghizadeh, A., Babaei, S., et al. (2020). Successful recovery of a child with COVID-19-induced secondary hemophagocytic lymphohistiocytosis. *Archives of Pediatric Infectious Diseases*, vol. 10, no. 1, p. e111434.

- [5] Arceci, R. J. (2016). *Histiocytosis syndromes. Lanzkowsky's manual of pediatric hematology and oncology* (pp. 407–428). Elsevier.
- [6] Brodin, P. (2020). Why is COVID-19 so mild in children? *Acta Paediatrica*, vol. 109, no. 6, pp. 1082–1083.
- [7] Cyranoski, D. (2020). Why children avoid the worst coronavirus complications might lie in their arteries. *Nature*, vol. 582, no. 7812, pp. 324–325.
- [8] Zimmermann, P. and Curtis, N. (2021). Why is COVID-19 less severe in children? A review of the proposed mechanisms underlying the age-related difference in severity of SARS-CoV-2 infections. *Archives of Disease in Childhood*, vol. 106, no. 5, pp. 429–439.
- [9] Bunyavanich, S., Do, A., and Vicencio, A. (2020). Nasal gene expression of angiotensin-converting enzyme 2 in children and adults. *JAMA*, vol. 323, no. 23, pp. 2427–2429.
- [10] Hyde, Z. (2021). Difference in SARS-CoV-2 attack rate between children and adults may reflect bias. *Clinical Infectious Diseases*, vol. 74, no. 1, pp. 152–155.
- [11] Boulad, F., Kamboj, M., Bouvier, N., et al. (2020). COVID-19 in children with cancer in New York City. *JAMA Oncology*, vol. 6, no. 9, pp. 1459–1460.
- [12] Marlais, M., Wlodkowski, T., Vivarelli, M., et al. (2020). The severity of COVID-19 in children on immunosuppressive medication. *The Lancet Child & Adolescent Health*, vol. 4, no. 7, pp. e17–e18.
- [13] Turner, D., Huang, Y., Martín-de-Carpi, J., et al. (2020). Corona virus disease 2019 and paediatric inflammatory bowel diseases: Global experience and provisional guidance (March 2020) from the Paediatric IBD Porto Group of European Society of Paediatric Gastroenterology, Hepatology, and Nutrition. *Journal of Pediatric Gastroenterology and Nutrition*, vol. 70, no. 6, pp. 727–733.
- [14] Filocamo, G., Minoia, F., Carbogno, S., et al. (2021). Absence of severe complications from SARS-CoV-2 infection in children with rheumatic diseases treated with biologic drugs. *Journal of Rheumatology*, vol. 48, no. 8, pp. 1343–1344.