

Original Article

# Histopathological Features of Whipple Pancreaticoduodenectomy in Sudan: A Single-center Experience

Salwa O. Mekki<sup>1</sup>, Azza A. Zulfu<sup>2,\*</sup>, Abderrhaim Dabora<sup>3</sup>, Waleed Elhaj<sup>4</sup>, Salah Osman<sup>5</sup>, Musaab Ahmed<sup>6,7</sup>, Mohamed H. Ahmed<sup>8</sup>

<sup>1</sup>Department of Pathology, Faculty of Medicine, Al Neelain University, Khartoum, Sudan

<sup>2</sup>Department of Pathology, Faculty of Medicine, Omdurman Islamic University, Omdurman, Sudan

<sup>3</sup>Ibn Sina University Hospital, Khartoum, Sudan

<sup>4</sup>Soba University Hospital, Khartoum, Sudan

<sup>5</sup>Khartoum Oncology Hospital (RICK), Khartoum, Sudan

<sup>6</sup>College of Medicine, Ajman University, Ajman, United Arab Emirates

<sup>7</sup>Center of Medical and Bio-allied Health Sciences Research, Ajman University, Ajman, United Arab Emirates

<sup>8</sup>Department of Medicine and HIV Metabolic Clinic, Milton Keynes University Hospital NHS Foundation Trust, Milton Keynes MK5 6LD, United Kingdom.

**ORCID:**

Mohamed H. Ahmed: <https://orcid.org/0000-0001-8045-6996>

Musaab Ahmed: <https://orcid.org/0000-0002-2300-9919>

Corresponding Author: Azza A. Zulfu; email: azzazulfu@gmail.com

Received 13 August 2021

Accepted 02 March 2022

Published 31 March 2022

Production and Hosting by Knowledge E

© Salwa O. Mekki et al.. This article is distributed under the terms of the [Creative Commons Attribution License](#), which permits unrestricted use and redistribution provided that the original author and source are credited.

Editor-in-Chief:

Prof. Mohammad A. M. Ibnouf

## Abstract

**Background:** Periapillary tumors (PATs) are rare and Whipple pancreaticoduodenectomy is the commonest surgical approach for its management. The aim of this study was to analyze the histopathological features of Whipple-resected periampullary tumors in Sudanese patients.

**Methods:** This retrospective descriptive study included 62 cases of Whipple resection seen in a center in Khartoum, Sudan from January 2016 to June 2021. The specimens were assessed for nine features of the tumor: site of the tumor (whether within the periampullary region), size of the tumor, histological type of the tumor, grade, perineural invasion, lymph vascular invasion, surgical margin status, lymph node metastasis status, and the pathological stage (pTNM).

**Results:** In total, 62 cases, 40 (64.5%) males and 22 (35.5%) females, were included. Age ranged from 20 to 90 years with a mean age of 56.08 years ( $\pm 12.98$  SD). Of the 62 cases, 58 were malignant (93.5%), while 4 cases were benign (6.5%). The pancreas was the commonest site for malignant tumors (53.4%), followed by the ampulla (24.1%), duodenum (15.5%), and distal common bile duct tumors (DCBD) (7%). The maximum tumor size was 8 cm, and the number of lymph nodes resected ranged from 3 to 33. Pancreatic ductal adenocarcinomas (PDACs) showed the highest percentage of perineural (62.1%) and lymphovascular (55.2%) invasions, and a positive margin was seen in four cases. The most common tumor stage was pT3pN1pMx.

**Conclusion:** PATs in the Sudanese population showed histological diversity regarding subtyping, grading, and staging. Further studies involving molecular prognostic features will support improving patient management.

## OPEN ACCESS

**Keywords:** periampullary tumors, Whipple pancreaticoduodenectomy, resection, histological features, Sudan

## 1. Introduction

Periampullary carcinomas are described as tumors arising within 2 cm of the major papilla in the duodenum. These tumors are of four different types: ampullary carcinoma (AMP; ampulla of Vater), biliary carcinomas (intrapancreatic distal bile duct), pancreatic (head–uncinate process), and duodenal (mainly from the second part) [1–3]. Although periampullary tumors (PATs) have different origins, due to being confined within a limited and complex anatomic region, they have a common operative approach (pancreaticoduodenectomy Whipple procedure) [1]. Pancreaticoduodenectomy is one of the most challenging and complicated surgical procedures [1]. Despite being named after Whipple, the recent surgical procedure has evolved through many milestones achieved by a number of pioneer surgeons, mainly William Stewart Halsted (1852–1922), Walther Carl Eduard Kausch (1867–1928), and Allen Old father Whipple (1881–1963) [4, 5]. Whipple is considered to be the father of pancreaticoduodenectomy. He presented his first report on a two-stage pancreaticoduodenectomy of three patients in 1935 at the American Surgical Association meeting in Boston [4, 6]. One year later, he performed a successful one-stage operation [4]. Whipple performed 37 pancreaticoduodenectomies in his career of which 30 were for periampullary carcinoma and 7 for chronic pancreatitis [4]. Some investigators consider pancreatic ductal adenocarcinoma (PDAC) as the commonest histopathological diagnosis in Whipple specimens, followed by AMP, distal common bile ducts tumors (DCBD), and duodenal tumors [5, 6].

Pancreatic cancer is the seventh highest cause of cancer death worldwide [7]. It is a lethal disease with an overall survival rate of six months [8]. PDAC is the commonest histological type of pancreatic cancer [7], comprising 90% of all pancreatic malignancies [9]. Most PDACs occur in the pancreatic head (60–70%) [9]. Pancreatic neuroendocrine tumors (PNETs) are a subgroup of gastroenteropancreatic neuroendocrine tumors (GEP–NETs) [10]. PNETs are rare pancreatic tumors accounting for <3% of primary pancreatic tumors [9]. They have far better prognosis compared to PDACs [10].

AMP is considered as the second most common type of periampullary cancer [11]. It has three histological subtypes: pancreaticobiliary, intestinal, or mixed [12]. However, there is some controversy regarding the prognosis of histological subtyping: while some authors suggest histological subtyping to be of no prognostic value [11–13], others consider pure intestinal type to be of a better prognosis compared to pure pancreaticobiliary type [14–16]. Nevertheless, CK20/CK7 immunohistochemistry is considered to be useful in differentiating intestinal type versus pancreaticobiliary type [17].

True duodenal carcinomas (DC) are rare entities with little available literature [18]. While Buchbjerg *et al.* considered that distinguishing carcinomas of duodenal origin from other periampullary carcinomas to be of prognostic importance [19], Onkendi *et al.* concluded that extra-ampullary and periampullary duodenal adenocarcinomas have similar survival after resection [18].

DCBD are rare and poorly characterized tumors due to difficulties in determining tumor origin and differences in the definition of the terminology [20]. Classically, extra-hepatic tumors of biliary epithelial origin are divided into proximal, middle, and distal. While Whipple resection is used for distal tumors, proximal and middle tumors are approached through hepatic resection [21].

Moreover, with respect to post-surgical survival and prognosis, the best prognosis is that of DC, followed by DCBD, AMP, and PDAC [5]. Compared to PDAC, AMPs are considered to be of better prognosis [11, 12, 22]. However, some investigators suggest AMP to be of the best prognosis amongst periampullary tumors [23]. Additionally, DCBD carcinomas are known for being of better prognosis compared to PDAC, but worse than AMP [20]. As a general rule, PATs originating from the pancreas have significantly worse long-term survival compared to PATs of non-pancreatic origin [13].

The aim of this study was to analyze the histopathological features of Whipple pancreaticoduodenectomy surgical specimens received over six years at one histopathology diagnostic center in Khartoum, Sudan.

## 2. Materials and Methods

This descriptive study was conducted at Ibn Elheitham Histopathology Center. Whipple pancreaticoduodenectomy specimens were received from three centers in Khartoum (Soba University Hospital, Fedail Hospital, and Al Faisal Hospital). Whipple specimens reported from January 2016 to June 2021 were retrospectively reviewed. Clinical data were retrieved from patients records, and histopathology archived reports, conventional hematoxylin & eosin (H&E)- and immunohistochemistry (IHC)-stained sections were all re-examined. Histopathological entities were updated to the most recent WHO Classification [2020]. Malignant tumors were staged according to the TNM Staging per the AJCC 8<sup>th</sup> edition 2018. Histopathological features analyzed included: histopathology diagnostic entity (whether benign or malignant); for malignant tumors, the site of the tumor within the periampullary region, type of the tumor, size of the tumor, grade, perineural invasion, lymphovascular invasion, margin status, lymph node involvement,

and pTNM stage were all recorded and analyzed. The study was conducted according to the institutional ethical committee guidelines.

### 3. Results

The study included 62 cases, 40 (64.5%) males and 22 (35.5%) females, with a male-to-female ratio of 1.8:1. Patients' age ranged from 20 to 90 years with a mean age of 56.08 years ( $\pm 12.98$  SD). While the commonest presenting symptom was obstructive jaundice (78%), other less common symptoms were right hypochondrial pain and weight loss.

Histopathological features included the following parameters: *Malignant versus Benign Histopathological entities*. Of the 62 cases included in the study, 58 were malignant (93.5%), while 4 were benign (6.5%). The four benign entities were all within the pancreas, including one case of IgG autoimmune pancreatitis and three cases of chronic pancreatitis.

#### 3.1. Histopathological features of malignant entities

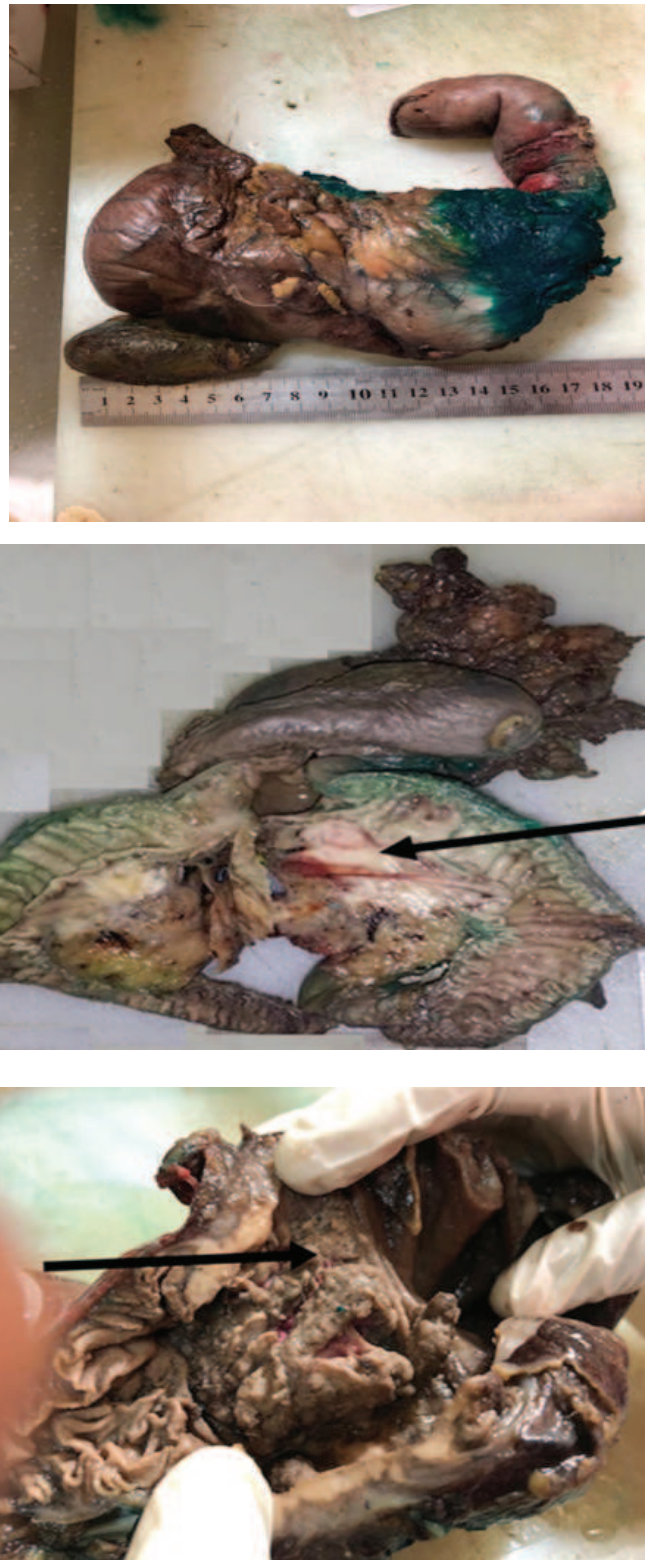We have included nine features of reporting malignancy: site of the tumor within the periampullary region, size of the tumor, histological type of the tumor, grade, perineural invasion, lymphovascular invasion, surgical margin status, lymph node metastasis status, and the pathological stage (pTNM) (Table 1).

The commonest site in the 58 cases of malignant tumors was the pancreas in 31 cases (53.4%), followed by ampulla in 14 cases (24.1%), duodenum in 9 cases (15.5%), and DCBD in 4 cases (7%). PDAC of the head of the pancreas were diagnosed in 29/31 malignant pancreatic tumors (93.5%). PNETs was reported in two cases (6.5%).

Pancreas was the commonest site for malignant tumors in this series, diagnosed in 31 (53.4%) of the 58 malignant cases, with a predominance of PDAC in 29 cases (93.5%) and two cases (6.5%) of PNETs. PDAC was the commonest histological sub-type of pancreatic malignancy (93.5%), all 29 cases in this series were of intermediate grade (moderately differentiated/ G2), with an average tumor size of 2.5 cm, within a range of 2–4 cm. While perineural invasion was seen in 18 cases (62.1%), lymphovascular invasion was seen in 16 cases (55.2%). Surgical margin was involved in four cases (13.8%). Seventeen cases (58.6%) showed nodal metastasis with a range of 3–30 LNs nodal harvest. The commonest tumor stage was pT3 in 18 cases, pT2 in 8 cases, and pT4 in 4 cases. PNETs were reported in 2 (6.5%) out of the 31 pancreatic malignant tumors, both were of intermediate grade with an average tumor size of 7 cm. Perineural

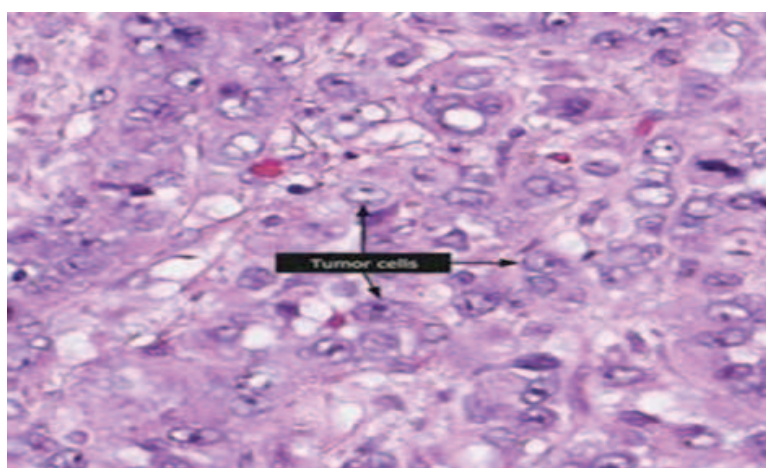
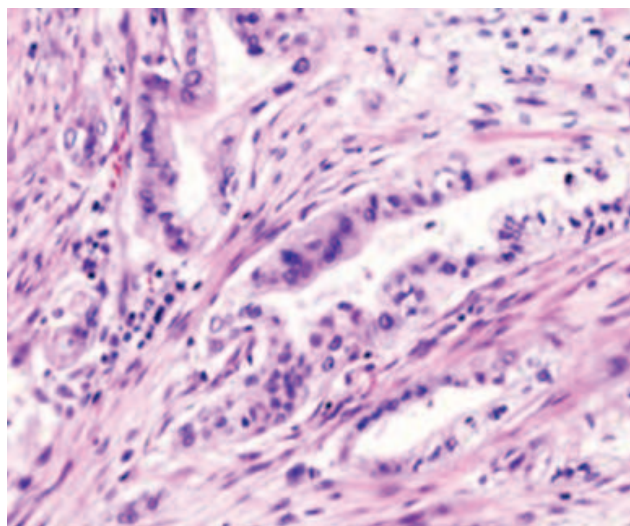
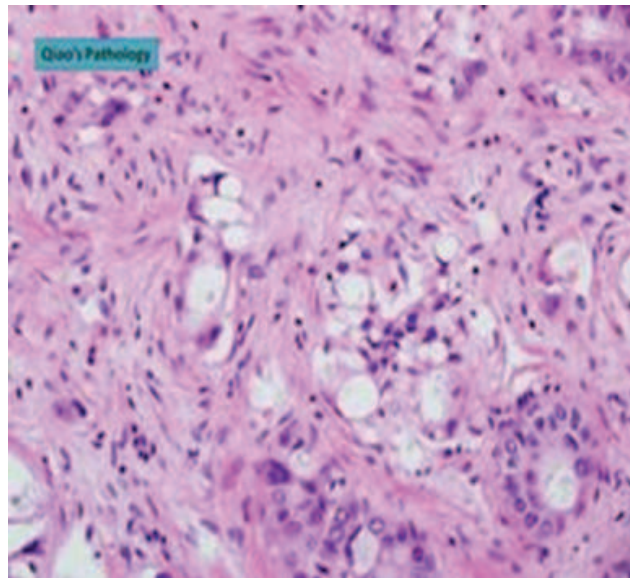
invasion was not seen in PNETs in these cases. Lymphovascular invasion was not seen. Surgical resection margin was free in both PNETs cases. Twelve and ten lymph nodes were isolated from the two cases. No lymph node metastases were seen in either of the two PNETs cases. Both cases were pTNM: pT2pN0pMx. Immunohistochemical staining for chromogranin NSE, synaptophysin, and Ki67 were used to verify and grade NETs.

Ampullary tumors were the second most common tumor in this series (24.1%). While all tumors were adenocarcinomas, eight cases were classified histologically as pancreaticobiliary predominant, three as intestinal predominant, and other three as mixed. All tumors were of intermediate grade (moderately differentiated adenocarcinoma/G2) with an average tumor size of 1.2 cm within a range of 1–2.2 cm. Perineural invasion was seen in two cases. Lymphovascular invasion was seen in three cases. Only one case of AMP showed involved surgical margin. Tumor stage: eight cases pT3, six cases pT2. A median of 11 LNs were isolated with a range of 3–30 LNs. About 50% of ampullary tumors showed metastatic nodal deposit, the commonest p TNM was pT3N1M. We reported nine cases of duodenal PATs, of which four cases were categorized as pure intestinal type adenocarcinoma, three as non-intestinal type (gastric and pancreaticobiliary), and two were of mixed features. All tumors were of intermediate grade (G2) with an average tumor size of 2 cm (range 1.3–5cm). The commonest tumor stage was pT3 seen in six cases, two cases of pT2, and one case of pT4. While perineural invasion was seen in two cases, lymphovascular invasion was seen in three cases. All duodenal tumors reported were of free surgical margins. The median number of isolated lymph nodes was 10, with a range of 6–33 LNs. Seven cases showed LN metastasis with a median of three LNs involved. The commonest pathological stage (p TNM) was pT3pN1pMx. DCBD tumors were the least common tumors reported in this series representing only 7%. All four reported cases were G2-moderately differentiated adenocarcinoma of the pancreaticobiliary type. The average size of the tumor was 1.5 cm (range: 1–3 cm). All four cases were stage pT2. LNs metastasis was not seen in examined LNs for any case. Perineural invasion was seen in two cases, while lymphovascular invasion was seen in one case. Surgical margin was not reported to be involved in any of our cases. Isolated lymph nodes ranged from 5 to 9 with a median of 6 LNs. Pathological stage (pTNM) was pT2No in all four cases.

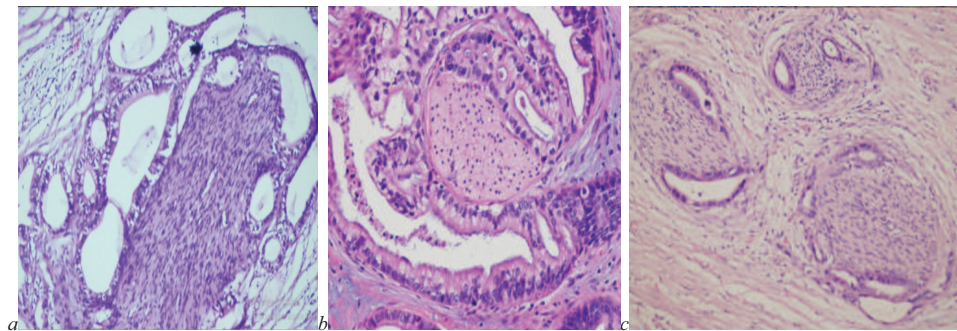


**Figure 1:** Whipple specimens: (a) outer surface; (b) cut section showing tumor at the head of pancreas; and (c) head of pancreas tumor involving both the ampulla and the duodenum.

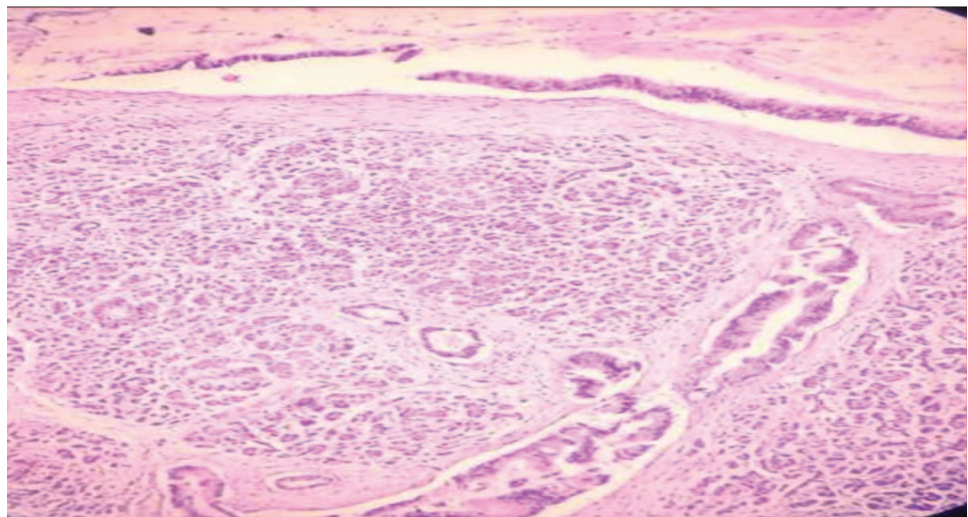




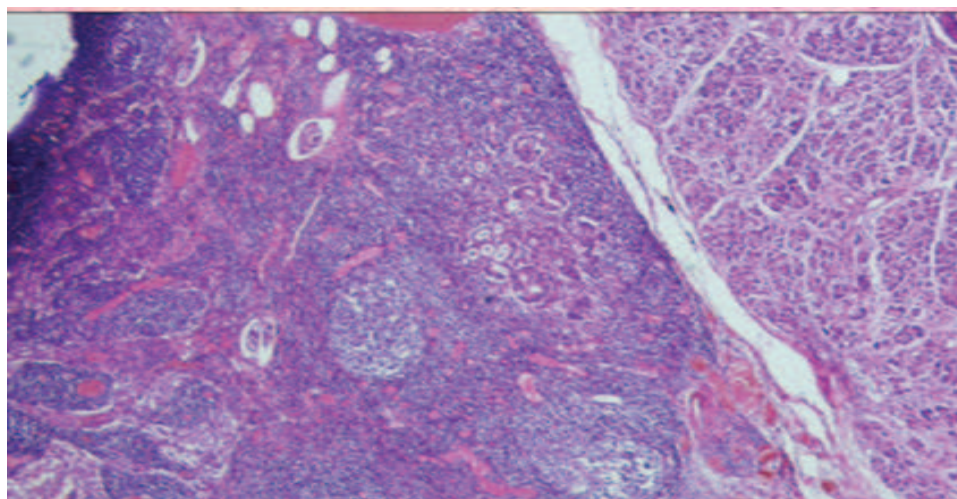
**Figure 2:** Periampullary carcinoma H&E stain  $\times 40$ : (a) well-differentiated; (b) moderately differentiated; and (c) poorly differentiated.



**Figure 3:** Peri-neural invasion in periampullary tumors H&E stain  $\times 40$ .

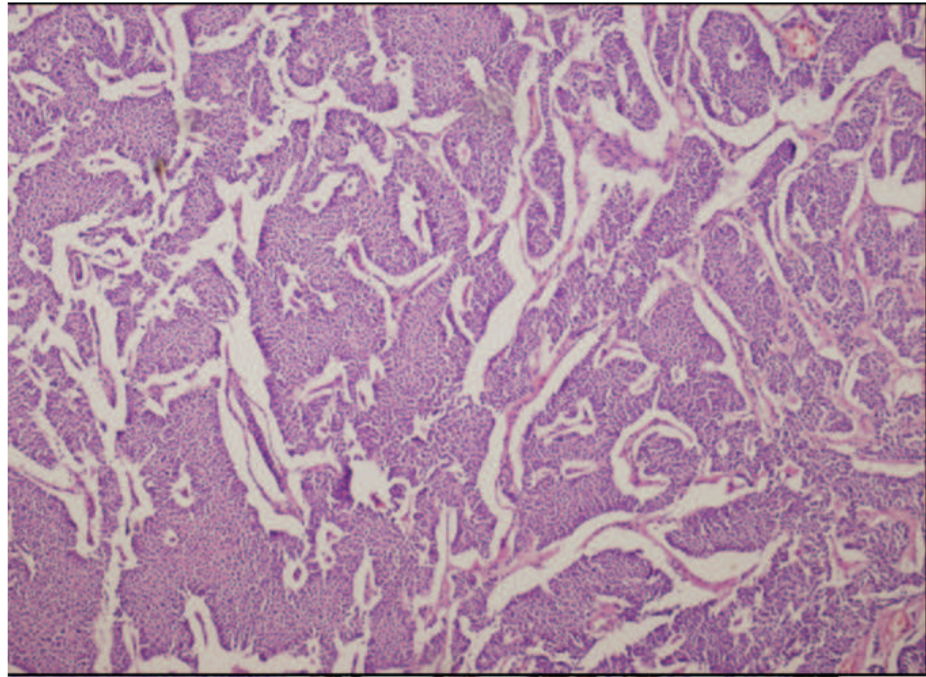


**Figure 4:** Vascular invasion in carcinoma of pancreas H&E stain  $\times 40$ .

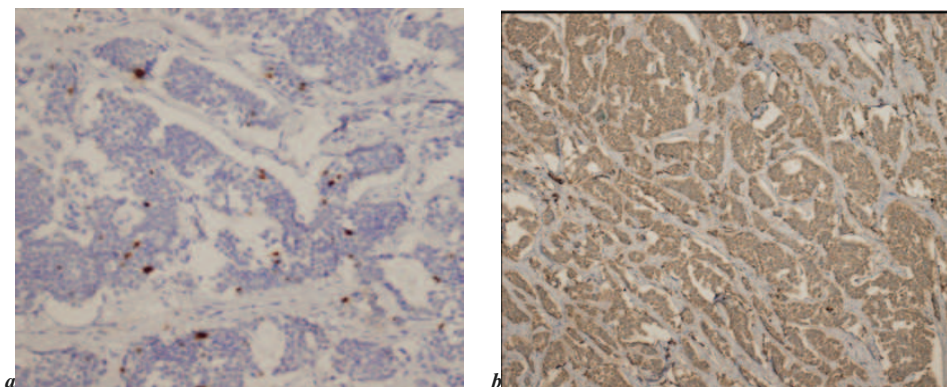


**Figure 5:** Metastatic adenocarcinoma to regional lymph nodes H&E stain  $\times 20$ .





**Figure 6:** Well-differentiated pancreatic neuroendocrine tumor (G1), H&E stain x40.



**Figure 7:** Immunohistochemical staining (IHC) of pancreatic neuroendocrine tumor: (a) IHC staining for Ki67 x40 and (b) IHC for chromogranin x40.

#### 4. Discussion

To the best of our knowledge, this is the first retrospective study on the histopathological features of Whipple pancreaticoduodenectomies in Sudan. Despite the fact that handling and reporting pancreatico–duodenectomy surgical specimens is a tedious task for histopathologists, this stage represents a crucial point in delivering the best care for these patients by providing accurate histopathology reporting [24–26]. Interestingly, Whipple found 7 cases of chronic pancreatitis and 30 cases with malignancy [4]. While Yeo *et al.* reported 32% of the cases without cancer and 68% with periampullary cancer [5]. Our study showed 93.3% malignant entities and 6.5% benign conditions. Similar

TABLE 1: Histopathological features of malignant tumors.

Histologic feature and tumor subtype	Pancreatic tumors (PDAC + NETs) N = 31 (53.4%) (PDAC + NETs) N = 31 (53.4%)	AMP N = 14 (24.1%) (pancreaticobiliary predominant, N = 3 intestinal predominant, N = 3 mixed)	DC N = 9 (15.5%) (N = 4 cases pure intestinal, N = 3 cases non-intestinal, N = 2 cases mixed features)	DCBDC N = 4 (7%)	
	PDAC	PNETs			
Average tumor size	2.5 cm	7 cm	1.2 cm	2 cm	1.5 cm
Range	2–4 cm	6–8 cm	1–2.2 cm	1.5–5 cm	1–3 cm
Grade	G2/moderately differentiated	G2	G2 (100%)	G2 (100%)	G2 (100%)
Stage	pT3 N = 18	pT2 = 2	pT3 N = 8 cases	pT3 N = 6	All 4 cases were T2
	pT2 N = 8		pT2 N = 6 cases	pT2 N = 2	
	pT4 N = 4			pT4 N = 1	
Cases with Involved LNs	3–33 LNs	10–12 LNs	Average LNs isolated = 11 LNs	Average LNs No = 10 Range: 6–33	LNs not seen in LNs examined for any case
Cases with Uninvolved LNs	17 cases (58.6%)	No LNs involvement	Range = 3–30 LNs. 50% of AMP showed LNs involvement	LN involvement Present 7 cases	
LV invasion – Present/Absent	16 cases (55.2%)	No lympho-vascular invasion	Present in 3 cases	Present in 3 cases	LV invasion 25%
Perineural invasion	18 cases (62.1%)	No perineural invasion	Present in 2 cases	Present in 2 cases	Perineural invasion 50%
Resection surgical margin	Involved in 4 cases	No LNs involvement	Margin involved in one case	All cases showed free surgical resection margin	Free margin in all 4 cases (100)
pTNM staging		Both cases pT2pN0pMx	Commonest pT3pN1pMx	Commonest pT3pN1pMx	All cases (100%) were pT2N0

PDAC: pancreatic ductal adenocarcinoma; PNETs: pancreatic neuroendocrine tumors; AMP: ampullary carcinoma; DC: duodenal carcinomas; DCBDC: distal common bile duct tumors pT3pN1pMx = staging of the cancer.

results were obtained in other countries. For instance, in Nepal, Dhakhwa and Kafle reported 88.57% malignant tumors and 11.43% benign lesions [2]. Foroughi *et al.* in Iran (2012) reported 86.3% malignant tumors compared to 13.7% benign lesions [3].

In this series, pancreatic tumors (53.4%) (mainly PDAC) was the commonest histopathological diagnosis in Whipple specimens, followed by ampullary tumors (24.1%), duodenal tumors (15.5%), and distal bile ducts tumors (7%) in the same order. Similar observations were noted by Yeo *et al.* and Fernández-del Castillo *et al.* [5, 6]. However, Dhakhwa and Kafle reported *periampullary* mixed carcinoma as the predominant tumor

(34.28%), followed by periampullary duodenal (20%), ampullary (14.28%), pancreatic adenocarcinoma (11.42%), and distal cholangiocarcinoma (5.71%) (2). Foroughi *et al.* reported AMP as the commonest type (61.4%) followed by pancreatic carcinomas (27.3%) and cholangiocarcinomas of distal bile ducts (11.4%) [3].

Similar to our histologic analytic approach, many previous studies have analyzed the nine histological features of PATs: site of the tumor within the periampullary region, tumor size, histological type, grade, perineural invasion, lymphovascular invasion, surgical margin, lymph node metastasis, pathological stage (pTNM), as well as results of follow-up survival duration [2, 3, 11, 14, 18, 20, 27].

While some researchers studied these features collectively [2, 3], others preferred to analyze each type of periampullary tumor separately [11, 14, 18, 20, 23, 27]. Investigators preferring the collective analysis may have good reason as their series (similar to ours) had a small number of cases and studying each type separately may yield statistically unreliable results (due to the small sample size). Periampullary tumors are a heterogeneous group of entities with different histogenesis and different prognoses, so analyzing each entity separately and comparing histological features would have been of good diagnostic and prognostic value. So, we chose the latter approach in our analysis despite the small number of our cases.

PDAC was the commonest malignancy in this study, all cases were moderately differentiated compared to a majority of 63% of moderately differentiated tumors reported by Yeo *et al.* [5]. The average tumor size in our series was 2.5 cm within a range of 2–4 cm; these findings were less than those reported by Yeo *et al.* [5] – a mean tumor size of  $3.2 \pm 1.6$  cm and median of 3 cm, however, our findings were similar to Gonzalez *et al.*'s [20] who reported a median tumor size of 2.5 cm. Surgical margin was involved in 13.8% of our cases; which is much less than the 29% reported by Yeo *et al.* [5] and 41% by Gonzales *et al.* [20]. Lymph node metastasis was seen in 58.6% of our cases compared to 70% reported by Yeo *et al.* [5] and 75% reported by Gonzales *et al.* [20].

Although the patients in this series were selected for Whipple surgery through the standard selection criteria used worldwide, these cases reported better free margin status and less nodal metastasis. Contributory factors behind these advantages of our PDAC cases need to be explored.

Neuroendocrine tumors of the pancreas (PNETs) were rare entities [10]. We reported only 2 cases of PNETs compared to 29 cases of PDAC, both cases were G2 compared to Shiba *et al.* who reported G1 in 12%, G2 in 54%, and G3 in 32% [28].

Furthermore, AMP is the second most common periampullary carcinoma and is considered to be of better prognosis, less metastasis, less vascular invasion, and of smaller tumor size compared to PDAC [11, 21–23].

Our cases described 14 cases of AMP carcinomas. The average tumor size was 1.2 cm within a range of 1–2.2 cm; the tumor size in our cases was smaller than in Klein *et al.* who reported 63% of the cases to be >2 cm and 37% <2 cm in size [23]. The tumor size in our study were similar to Yeo *et al.*'s who reported a mean tumor size of  $2.3 \pm 1.4$  cm and a median of 2 cm [5]. However, while we reported a single case with 7.2% of involved surgical margin, Klein *et al.* reported 8% [23] and Yeo *et al.* reported 3% of surgical margin involvement. About 57% of our cases were pT3 and 42% were pT2. These findings were close to Klein *et al.* who reported pT2 in 37% of the cases and pT3 in 38%. We reported no cases of pT1 or pT4 while Klein *et al.* reported pT1 in 10% and pT4 in 14% [23]. We reported 50% of ampullary tumors with metastatic nodal deposits which is almost the same as Klein *et al.* who reported LNs metastasis in 48% [12], but less than Yeo *et al.* who reported nodal deposits in 44% [5].

AMP adenocarcinoma is well-known for having three histological subtypes: pancreaticobiliary, intestinal, and mixed [22]. There is some controversy regarding the prognostic value of histological subtyping of AMPs. Reid *et al.* in their analysis of 232 cases of AMP showed intestinal type to have a better prognosis compared to pancreaticobiliary and mixed subtypes, however, they concluded that these differences are of no statistical significance [14]. Westgaard *et al.* in their analysis of periampullary tumors including 61 cases of AMP carcinoma suggested that histological subtypes of AMP have no prognostic differences [13]. Similarly, Morris-Stiff *et al.* also suggested that histological subtype is of no prognostic differences [11]. On the other hand,

as our cases were fewer in number compared to these studies, analysis based on histological subtyping does not seem to be of statistical significance.

Our data showed DCs to have an average tumor size of 2 cm (range 1.3–5 cm), while Yeo *et al.* [5] reported a mean tumor size of 4.8–2.8 cm and a median of 4.8 cm. Poultsides *et al.* [27] reported 14/122 (11.5%) of their cases to be <2 m and 91/122 (74.5%) >2 cm. All our DC cases were moderately differentiated, while both Yeo *et al.* [5] and Poultsides *et al.* [27] reported a majority of moderately differentiated tumors of 70% and 60%, respectively. While most of our DC cases were stage T3 in 6/9 (66.7%), Poultside *et al.* [27] reported most of their cases to be T3 and T4 80/122 (65.6%).

All our cases were of free surgical margin, while Yeo *et al.* reported 4% and Poultsides *et al.* [15] reported 8% of involved surgical margin. We had 2/9 (22%) perineural invasion



and 3/9 (33%) lymphovascular invasion compared to 39% vascular invasion and 37% perineural invasion in Poultsides *et al.* cases [27].

We reported 7/9 (77.8%) cases featuring lymph nodes metastasis compared to 62% reported by Yeo *et al.* [5].

Of note, DCBD reported in our series had an average tumor size of 1.5 cm within a range of 1–3 cm, compared to a median tumor size of 2.5 cm reported by Gonzales *et al.* [20]. We reported no LNs metastasis, these findings were far less in number compared to Yeo *et al.* [5] who reported 57% and Gonzales *et al.* [20] who reported 39% LNs metastasis. We reported no surgical margin involvement while Yeo *et al.* reported 9% nodal deposits and Gonzales *et al.* reported 23% margin involvement. The absence of lymph node metastasis and negative margin status may be explained by the fewer number of DCBD tumors reported in our series.

## Limitations

The current study was not without limitations. Our cases were small in number compared to other similar studies. Limited panels of immunohistochemistry were used for verification of some cases. Implementation of molecular studies would have provided further verification about tumor histogenesis. We were able to collect data for patients' survival follow-ups post-surgery for only 20 patients (34.5%) and only for one year; follow-up for more cases and for longer durations would have given more information about post-surgery survival. The follow-up showed the following:

1. Pancreatic head carcinoma (HOP): Follow-up of eight patients for one year post surgery: Five of them died within six months, the other three were still alive. These findings were compatible with the literature finding pancreatic adenocarcinoma to be of the worst prognosis [7, 8].
2. PNETs: Both reported cases were alive at one-year follow-up after surgery. PNETs are well-known for being of better prognosis than PACs [10].
3. AMP: Four patients were followed-up for one year. One patient died within six months, while the others were alive; these findings may be in keeping with data reporting AMP to be of the best prognosis among periampullary tumors [23].
4. DC: Two patients of DC were followed for one year. Both of them were alive.
5. pTNM for alive patients: pT3N0Mx and pT2N0Mx. Distal CBD: All four cases were pT2N0Mx: one patient died within six months of follow-up; others were alive up to

the one-year follow-up. Available studies suggest DCBDs to be of better prognosis compared to PACs but worse than ampullary [20].

Anyhow, our cases were few and all of them presented with less tumor stage and no LNs metastasis; this may reflect that all patients were alive at one-year follow-up except for one case.

## 5. Conclusion

Histological features of Whipple resected PATs in Sudanese patients showed diversity regarding subtyping, grading, and staging . Larger case series of PATs with long-term follow-up is required to clarify the vital role of histopathology in PATs management in Sudanese patients. Furthermore, studies involving molecular prognostic features will also contribute to improving patient management.

## Acknowledgements

The authors are grateful to their families for their support.

## Ethical Considerations

## Competing Interests

None.

## Funding

None.

## References

- [1] Sarmiento, J. M., Nagorney, D. M., Sarr, M. G., et al. (2001). Periapillary cancers: are there differences? *Surgical Clinics of North America*, vol. 81, no. 3, pp. 543–555.
- [2] Dhakhwa, R. and Kafle, N. (2016). Histopathologic analysis of pancreaticoduodenectomy specimen. *Journal of Nepal Medical Association*, vol. 55, no. 204, pp. 79–85.

- [3] Foroughi, F., Mohsenifar, Z., Ahmadvand, A. R., et al. (2012). Pathologic findings of Whipple pancreaticoduodenectomy: a 5-year review on 51 cases at Taleghani general hospital. *Gastroenterology and Hepatology from Bed to Bench*, vol. 5, no. 4, pp. 179–182.
- [4] Are, C., Dhir, M., and Ravipati, L. (2011). History of pancreaticoduodenectomy: early misconceptions, initial milestones and the pioneers. *HPB: The Official Journal of the International Hepato Pancreato Biliary Association*, vol. 13, no. 6, pp. 377–384.
- [5] Yeo, C. J., Cameron, J. L., Sohn, T. A., et al. (1997). Six hundred fifty consecutive pancreaticoduodenectomies in the 1990s: pathology, complications, and outcomes. *Annals of Surgery*, vol. 226, no. 3, p. 248.
- [6] Fernández-del Castillo, C., Morales-Oyarvide, V., McGrath, D., et al. (2012). Evolution of the Whipple procedure at the Massachusetts General Hospital. *Surgery*, vol. 152, no. 3, pp. S56–S63.
- [7] Luchini, C., Capelli, P., and Scarpa, A. (2016). Pancreatic ductal adenocarcinoma and its variants. *Surgical Pathology Clinics*, vol. 9, no. 4, pp. 547–560.
- [8] Collisson, E. A., Sadanandam, A., Olson, P., et al. (2011). Subtypes of pancreatic ductal adenocarcinoma and their differing responses to therapy. *Nature Medicine*, vol. 17, no. 4, pp. 500–503.
- [9] McGuigan, A., Kelly, P., Turkington, R. C., et al. (2018). Pancreatic cancer: a review of clinical diagnosis, epidemiology, treatment and outcomes. *World Journal of Gastroenterology*, vol. 24, no. 43, p. 4846.
- [10] Ehehalt, F., Saeger, H. D., Schmidt, C. M., et al. (2009). Neuroendocrine tumors of the pancreas. *The Oncologist*, vol. 14, no. 5, pp. 456–467.
- [11] Morris-Stiff, G., Alabraba, E., Tan, Y. M., et al. (2009). Assessment of survival advantage in ampullary carcinoma in relation to tumour biology and morphology. *European Journal of Surgical Oncology*, vol. 35, no. 7, pp. 746–750.
- [12] Sommerville, C. A., Limongelli, P., Pai, M., et al. (2009). Survival analysis after pancreatic resection for ampullary and pancreatic head carcinoma: an analysis of clinicopathological factors. *Journal of Surgical Oncology*, vol. 100, no. 8, pp. 651–656.
- [13] Westgaard, A., Pomianowska, E., Clausen, O. P., et al. (2013). Intestinal-type and pancreatobiliary-type adenocarcinomas: how does ampullary carcinoma differ from other periampullary malignancies? *Annals of Surgical Oncology*, vol. 20, no. 2, pp. 430–439.
- [14] Reid, M. D., Balci, S., Ohike, N., et al. (2016). Ampullary carcinoma is often of mixed or hybrid histologic type: an analysis of reproducibility and clinical relevance of

- classification as pancreatobiliary versus intestinal in 232 cases. *Modern Pathology*, vol. 29, no. 12, pp. 1575–1585.
- [15] Zimmermann, C., Wolk, S., Aust, D. E., et al. (2019). The pathohistological subtype strongly predicts survival in patients with ampullary carcinoma. *Scientific Reports*, vol. 9, no. 1, pp. 1–8.
- [16] Kim, W. S., Choi, D. W., Choi, S. H., et al. (2012). Clinical significance of pathologic subtype in curatively resected ampulla of vater cancer. *Journal of Surgical Oncology*, vol. 105, no. 3, pp. 266–272.
- [17] Morini, S., Perrone, G., Borzomati, D., et al. (2013). Carcinoma of the ampulla of Vater: morphological and immunophenotypical classification predicts overall survival. *Pancreas*, vol. 42, no. 1, pp. 60–66.
- [18] Onkendi, E. O., Boostrom, S. Y., Sarr, M. G., et al. (2012). 15-year experience with surgical treatment of duodenal carcinoma: a comparison of periampullary and extra-ampullary duodenal carcinomas. *Journal of Gastrointestinal Surgery*, vol. 16, no. 4, pp. 682–691.
- [19] Buchbjerg, T., Fristrup, C., and Mortensen, M. B. (2015). The incidence and prognosis of true duodenal carcinomas. *Surgical Oncology*, vol. 24, no. 2, pp. 110–116.
- [20] Gonzalez, R. S., Bagci, P., Basturk, O., et al. (2016). Intrapancreatic distal common bile duct carcinoma: analysis, staging considerations, and comparison with pancreatic ductal and ampullary adenocarcinomas. *Modern Pathology*, vol. 29, no. 11, pp. 1358–1369.
- [21] Yoshida, T., Matsumoto, T., Sasaki, A., et al. (2002). Prognostic factors after pancreatoduodenectomy with extended lymphadenectomy for distal bile duct cancer. *Archives of Surgery*, vol. 137, no. 1, pp. 69–73.
- [22] O’Connell, J. B., Maggard, M. A., Manunga, J., et al. (2008). Survival after resection of ampullary carcinoma: a national population-based study. *Annals of Surgical Oncology*, vol. 15, no. 7, pp. 1820–1827.
- [23] Klein, F., Jacob, D., Bahra, M., et al. (2014). Prognostic factors for long-term survival in patients with ampullary carcinoma: the results of a 15-year observation period after pancreaticoduodenectomy. *HPB Surgery*, vol. 2014, article 970234.
- [24] Adsay, N. V., Basturk, O., Saka, B., et al. (2014). Whipple made simple for surgical pathologists: orientation, dissection, and sampling of pancreaticoduodenectomy specimens for a more practical and accurate evaluation of pancreatic, distal common bile duct, and ampullary tumors. *The American Journal of Surgical Pathology*, vol. 38, no. 4, p. 480.



- [25] Campbell, F., Cairns, A., Duthie, F, et al. (2019). *Dataset for histopathological reporting of carcinomas of the pancreas, ampulla of Vater and common bile duct* (Document No. G091). London: The Royal College of Pathologists. <https://www.rcpath.org/uploads/assets/34910231-c106-4629-a2de9e9ae6f87ac1/G091-Dataset-for-histopathological-reporting-of-carcinomas-of-the-pancreas-ampulla-of-Vater-and-common-bile-duct.pdf>
- [26] del Carmen Gómez-Mateo, M., Sabater-Ortí, L., and Ferrández-Izquierdo, A. (2014). Pathology handling of pancreatoduodenectomy specimens: approaches and controversies. *World Journal of Gastrointestinal Oncology*, vol. 6, no. 9, p. 351.
- [27] Poultsides, G. A., Huang, L. C., Cameron, J. L., et al. (2012). Duodenal adenocarcinoma: clinicopathologic analysis and implications for treatment. *Annals of Surgical Oncology*, vol. 19, no. 6, pp. 1928–1935.
- [28] Shiba, S., Morizane, C., Hiraoka, N., et al. (2016). Pancreatic neuroendocrine tumors: a single-center 20-year experience with 100 patients. *Pancreatology*, vol. 16, no. 1, pp. 99–105.