

Hashimoto's Thyroiditis Presenting as Bilateral Ovarian Masses in an Adolescent

Paapa Dasari¹, Nitin M², Chitra Thiyagarajan³

¹Dept of OBGY, JIPMER Puducherry, India. Email: dasaripapa@gmail.com

²Dept of OBGY, JIPMER Puducherry, India. Email: nithinmdc@gmail.com

³Dept of OBGY, JIPMER Puducherry, India. Email: drchitra@yahoo.com

Article Info

Article history:

Received: 20 April 2021

Revised: 23 May 2021

Accepted: 25 May 2021

Keywords:

Adolescent, Bilateral Ovarian Cysts, Hypothyroidism, Hashimoto's Thyroiditis.

Paper Type :

Case Report

Corresponding Author:

Papa Dasari

Email: dasaripapa@gmail.com

ORCID: [0000-0003-1022-2750](https://orcid.org/0000-0003-1022-2750)

Mobile: 9442566883

Abstract

Hypothyroidism can cause significant reproductive morbidity and its association with ovarian cyst formation is rare and when it occurs in children, it is referred to as Van Wyk and Grumbach syndrome. An 18-year-old girl was referred to our emergency services with suspicion of torsion ovarian cyst with USG findings as she had pain abdomen and vomiting of 3 days duration. She was provisionally prepared for laparoscopic surgery but on reevaluation by USG bilateral thecaleutein cysts measuring 7x6.8x3.5 cms (right) and 10x6.8 x3.2 cms (left) were diagnosed. Her TSH level was 483 mIU/L. On probing she revealed past history of diagnosis of hypothyroidism and discontinuation of thyroxin therapy after taking for 6 months. Her anti TPO antibodies were >1300 IU/mL. USG thyroid revealed features suggestive of Hashimoto's thyroiditis. She was counselled and started on thyroxin therapy with a dose of 4µg/kg and after 2 months of follow up the ovarian cysts have regressed and ovaries appeared normal on USG.

1. Introduction

Adnexal masses are rare in adolescents and paediatric age group and the incidence of malignancy is reported to be 10% approximately (Wyk & Grumbach, 1960). USG is the first modality for evaluation to differentiate benign from malignant (Aggrwala & Gupta, 2018). A Tumour marker are helpful in coming to a conclusion regarding the nature of the masses. The causes of bilateral ovarian enlargements include PCOS, Tuberculosis, Endometriosis and Germ cell tumours in the adolescents and young adults. It is of utmost importance for the clinician to understand the differential diagnosis and facilitate correct management surgical and non-surgical. Fertility preservation is the standard of care in adolescents and the guidelines need to be strictly adhered to when managing adolescents with ovarian masses.

Hypothyroidism is a cause of significant reproductive morbidity resulting in anovulation, infertility, menorrhagia and pregnancy loss. Its association with ovarian cyst formation was reported as Van Wyk and Grumbach syndrome in juvenile primary hypothyroidism (Shu et al., 2011). Very few cases of ovarian hyper stimulation due to hypothyroidism have been reported in literature. Unawareness of the association can result in un-necessary surgical procedures resulting in decreased reproductive potential. Hence this case is reported.

2. Case

An 18 years old adolescent unmarried girl presented to our emergency services with pain abdomen and vomiting of 3 days duration. Pain abdomen was intermittent moderate in severity and was more on right side than on left side of lower abdomen. She had 3 episodes of projectile vomiting which was non-bilious and had food particles. There was no history of burning micturition and her bowel movements are normal. The pain and vomiting are not related to menstruation. She was hospitalised elsewhere for less than 24 hours and referred to us with suspicion of ovarian torsion.

She attained menarche at 14 years of age and her cycles were irregular occurring once in 45-60 days and bleeding lasts for 5 -6 days and she changes 7 pads per day and associated with spasmodic dysmenorrhea. Her last menstrual period was 2 months ago. Her past history is that she was diagnosed to be suffering from hypothyroidism 6 months back (TSH-186 mIU/L) when she approached physician for swelling in the neck region and swelling of legs. She was advised tab. Eltroxin which she consumed irregularly and discontinued for the past 2 months and is on acupuncture. No history of any other medications. Studying in Degree course and academically good and her sleep and appetite are normal. There is no family history of thyroid dysfunction, heart disease, diabetes, tuberculosis or malignancies.

On examination, her mentation is normal. She weighed 49kg and her height was 155 cms, BMI 20.3 kg/m². She was afebrile, had mild palor and hydration was normal. Her pulse was 90/min BP was 110/90 mmHg and there was mild thyroid enlargement and no lymphadenopathy. Breast were well developed and Cardiovascular and Respiratory examination was normal. Abdomen was soft and there was no organomegaly or free fluid and mild tenderness was present in right iliac fossa. External genitalia were normal and there was no discharge or bleeding at introitus. Per speculum and per vaginal examination was not done. TAS in the ED (emergency department) revealed bilateral ovarian masses and she was investigated to rule out malignancy. Tumour markers- Beta HCG-0.3 mIU/ml; Alpha fetoprotein-25ng/ml; CA 125 -25.5 IU/ml. CEA- 1.7 ng/ml; LDH-480 U/L; CT scan was advised. COVID19- RT-PCR was Negative; Her investigations at (admission)5.7.2020; Hb-6.2 gms%; WBC-8,440/mm³ N-60% L-27% ; Platelets -3.68 lakhs/mm³ Random blood sugar 87 mg% Urea 12mg/dl; Creatinine -0.57mg/dl ; Serum Electrolytes- Na-135 meq/L ; K+4.6 meq/L; Total Bilirubin-0.19 mg/dl; AST/ALT=28/18; Serum Albumin -4.9gm/dl. She was provisionally prepared for laparoscopic surgery.

Review TAS (Trans abdominal Scan) by senior consultant prior to decision for surgery diagnosed bilateral theca leutein cysts because of the characteristic USG features (Fig -1); right ovary measured 7x6.8x3.5 cms; Left measured 10x6.8 x3.2 cms. Doppler flow

present in both ovarian pedicles. Uterus measured 8.7 x 3.2 cms and endometrial thickness was 10 mm. Liver, Gall bladder and both kidneys were normal. A provisional clinical diagnosis of bilateral theca lutein cysts was made. After the scan findings, history of recent pregnancy was elicited which the patient and her mother denied. Hormonal profile including TFT was advised.

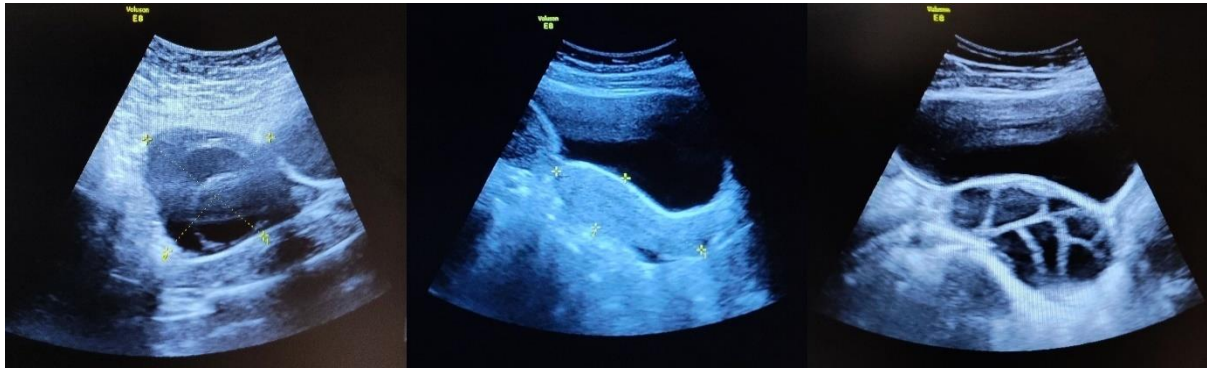

Figure 1: shows normal uterus in the centre and enlarged cystic ovaries on either side

She received one unit of packed cell transfusion for anaemia and analgesics for pain relief. Her investigations on 7.7.2020: **TSH - was 483**; T3 1.94; T4 0.32; **Anti-TPO antibodies- >1300**; GTT- 102/206/151.; Hormonal Profile –LH: 0 FSH -5.3 IU/L ; S. Prolactin- 38.9 ng/ml S. Testosterone -0.1 ng/dl; Serum Cortisol 8.6 nmol/L; Serum Ferritin- 14.6 ng/ml; Vit B12 -298 ng/dl; Estradiol : 40 pg/dl; USG Thyroid: Few benign appearing nodes largest 5mm : Hypoechoic thyroid suggestive of Hashimoto's thyroiditis.

CT findings (9.7.2020) were consistent with bilateral theca lutein cysts: Bilateral ovaries have multiple large cysts within –right ovary 7.4x5.5x3.7 and left ovary 5.9x9.4x5.7 without enhancing solid lesions. (Fig 2). No enlarged lymphnodes and there was minimal ascites in pelvis. Thyroid gland appeared normal in size with mild heterogenous enhancement. Endocrinologist opinion was obtained and a final diagnosis of Hashimoto's thyroiditis was confirmed. FNAC of thyroid was deferred.

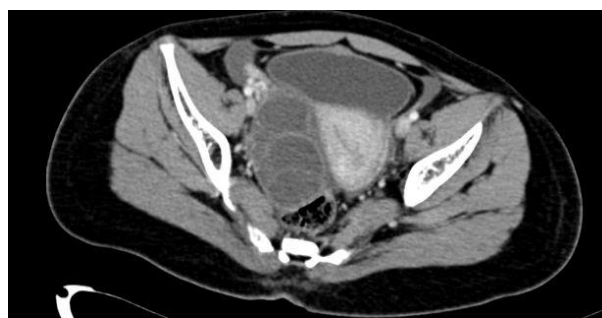

Figure 2: CT picture shows bilateral theca lutein cysts

Thyroxin replacement was started with 4 µg/kg body weight and she was counselled for compliance to therapy and assured that the masses would disappear on therapy and surgery is not needed. She was asked to continue oral iron therapy for anaemia. Follow-up after 2 months (September first week) her TFT was T3 252.39; T4 20.76; **TSH-0. 218**. She was on 200 mcg of thyroxin per day. TAS showed left ovary 5.04 x2.69 x 3.7 cms and right

ovary 5.17x2.5x4.41 cms. (Fig 3) The dose of thyroxin was reduced to 175 mcg /day. She was asked to review after 4 weeks with hormonal profile and further follow-up.

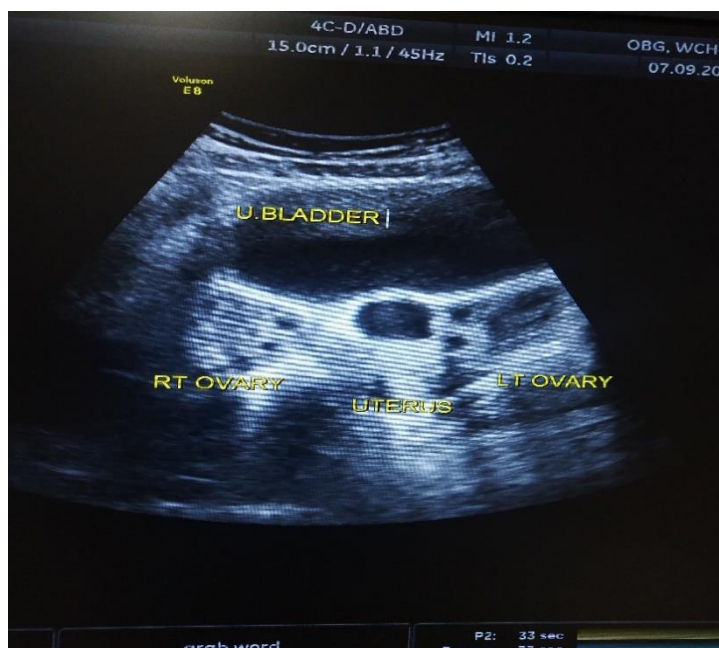


Figure 3: Follow-up TAS showing normalised Ovaries

3. Results and Discussion

Autoimmune Thyroiditis is a chronic disease in which the body develops antibodies to its own thyroid cells resulting in their destruction. This usually results in hypothyroidism and the most common cause is Hashimoto's Thyroiditis. Autoimmune thyroiditis is rare in children and most commonly reported in adolescents and young adults with goitre.

The characteristics of adnexal masses vary on ultra sound and it is possible to come to conclusion depending on the USG appearance regarding the etiology in most of the cases. Bilateral theca lutein cysts due to hyperstimulation by hCG occur in vesicular mole more commonly than in normal pregnancy though spontaneous ovarian hyperstimulation is possible. As the characteristics of these adnexal masses of the present girl on USG were resembling those of theca lutein cysts (ovarian hyperstimulation), history of pregnancy or Vesicular mole was elicited and however the biochemical marker(hCG) for these conditions was negative in this girl. There is lack of awareness among the Gynaecologists regarding the association of hypothyroidism with ovarian cysts and hence even though this girl gave history of hypothyroidism the association was not thought of and further investigations like CT scan were undertaken. These cysts can undergo torsion and present as acute abdomen in children. Unawareness has led to failure of investigating for thyroid dysfunction and bilateral salphingo-oophorectomy in a 11-year old girl (Dharmshaktu et al., 2013). The clinical features they reported were haemorrhagic ascites and bilateral haemorrhagic ovaries with gangrene. Recurrent Ovarian cysts after left oophorectomy and right cystectomy at age 19, and 22 respectively in a woman aged 23 was reported. Extensive investigations including FHR receptor polymorphism was undertaken and primary hypothyroidism was arrived at (Chattopadhyay et al., 2013).

The symptoms of hypothyroidism like, cold intolerance, dry skin, mental disturbances were absent in this girl and the only symptom was menorrhagia which resulted in anaemia. The presenting clinical feature was chronic pain abdomen for 2 months which was also reported by Dharmshktua and colleagues (Yamashita Y et al., 2001). This was a 21-year-old young lady with 8x8x6 cms cyst in POD with classical symptoms of hypothyroidism like dry skin and hoarseness of voice and hence pre-operatively clinical diagnosis was possible and thyroid function tests were done and laparotomy was deferred. Features of pre-cocious puberty and galactorrhea are reported in hypothyroidism (Shu et al., 2011; Taher et al., 2004).

The USG features of the present case closely resembled that of ovarian hyperstimulation seen in controlled ovarian stimulation prior to oocyte retrieval and hence hormonal profile was done and FSH was only 5.8 and LH was undetectable and however prolactin was high revealing the association of hypothyroidism with hyperprolactinaemia. Hyperprolactinaemia is also reported in other reports of hypothyroidism with Ovarian cysts(Chattopadhyay et al, 2013; Kubota et al., 2008; Kasum, 2010).

Tumour markers were done soon after admission as it was suspected to be malignant because of bilaterality. CA 125 levels were marginally elevated on the present case (29 IU/ml) which is similar to the case report of Shu et al. (Chattopadhyay A et al, 2013). Taher BM (Kasum, 2010) and Kubota K (Ramesan et al., 2016) found elevated levels of CA 125, 93 IU/mL and 72 IU/mL respectively. Tumour markers were normal in the case reported by Sandeep Aggrawal (Dharmshaktu et al., 2013). TSH level were 486 mIU/L in this adolescent girl and high levels as high as 1840 mIU/L were reported by Kubota K. The levels of TPO- abs were in the range of 100IU/L and 108IU/L in the cases of Kubota K and Shu et al respectively and in the present case it was more than 1300IU/L.

The incidence of ovarian cysts associated with hypothyroidism after 12 years and with a TSH level of ≥ 6 mIU/L was 33% and the USG characteristics were reported as simple, complex and multicystic. The association was significantly more in women with primary hypothyroidism. Three different antibodies are reported Viz: Thyroid peroxidase antibodies (TPO Ab), Thyroglobulin antibodies (TG Ab) and Thyroid stimulating hormone receptor antibodies. Kubota reported high levels of TG abs and Shu et al elevated levels of 83. LDH is also found to be elevated in this case and those of Kubota and Shu et al. Serum hCG is not elevated but there is ovarian hyper-stimulation and various mechanisms were proposed for this finding. Usually, ovarian hyper stimulation results due to stimulation of follicular stimulating hormone receptors (FSHR) by FSH exogenous or endogenous. Hormones structurally similar to FSH like hCG and TSH can also cause this condition. The high TSH is the reason for OHSS like features on USG in this adolescent.

Regression of a large ovarian cyst associated with hypothyroidism occurred in 4 to 6 month's period with thyroxin therapy⁴. Euthyroid status was achieved in 2 months and regression of Ovarian cysts occurred in 7 months in the case reported by Shuabd colleagues³. Periodic testing of Thyroid hormone profile is necessary as persistent normal TSH may denote resolution of autoimmune thyroiditis (Kaplowitz BP, 2012).

Acknowledgements

Ms. Kayathri Karthikeyan, Project assistant for editing the figures.

Conflict of Interest

None.

Funding:

None.

References

- Agarwala, S., & Gupta, A. (2018). Primary Hypothyroidism Presenting as Bilateral Ovarian Torsion. *Indian pediatrics*, 55(1), 77.
- Chattopadhyay, A., Kumar, V., & Marulaiah, M. (2003). Polycystic ovaries, precocious puberty and acquired hypothyroidism: the Van Wyk and Grumbach syndrome. *Journal of pediatric surgery*, 38(9), 1390-1392.
- Dharmshaktu, P., Kutiyal, A., & Dhanwal, D. (2013). Vanishing large ovarian cyst with thyroxine therapy. *Endocrinology, diabetes & metabolism case reports*, 2013(1).
- Kaplowitz, P. B. (2012). Case report: rapid spontaneous recovery from severe hypothyroidism in 2 teenage girls. *International journal of pediatric endocrinology*, 9(1), 1-3.
- Kasum, M. (2010). New insights in mechanisms for development of ovarian hyperstimulation syndrome. *Collegium antropologicum*, 34(3), 1139-1143.
- Kubota, K., Itho, M., Kishi, H., Igarashi, S., & Minegishi, T. (2008). Primary hypothyroidism presenting as multiple ovarian cysts in an adult woman: a case report. *Gynecological Endocrinology*, 24(10), 586-589.
- Ramesan C, Unnikrishnan E, Firozbabu K (2016). Incidence of Ovarian Cyst in hypothyroidism. An institutional study. *J Evid Based med Health*. 3 (78), 4236-4241.
- Shu, J., Xing, L., Zhang, L., Fang, S., & Huang, H. (2011). Ignored adult primary hypothyroidism presenting chiefly with persistent ovarian cysts: a need for increased awareness. *Reproductive Biology and Endocrinology*, 9(1), 1-7.
- Taher, B. M., Ghariabeh, R. A., Jarrah, N. S., Hadidy, A. M., Radaideh, A. M., & Ajlouni, K. M. (2004). Spontaneous ovarian hyperstimulation syndrome caused by hypothyroidism in an adult. *European Journal of Obstetrics & Gynecology and Reproductive Biology*, 112(1), 107-109.
- Van Wyk, J. J., & Grumbach, M. M. (1960). Syndrome of precocious menstruation and galactorrhea in juvenile hypothyroidism: an example of hormonal overlap in pituitary feedback. *The Journal of Pediatrics*, 57(3), 416-435.
- Yamashita, Y., Kawamura, T., Fujikawa, R., Mochizuki, H., Okubo, M., & Arita, K. (2001). Regression of both pituitary and ovarian cysts after administration of thyroid hormone in a case of primary hypothyroidism. *Internal medicine*, 40(8), 751-755.