

Case Report

Giant Cell Tumor of The Ribs: A Case Report

I Putu Gede Pradnyadewa Pradana¹ , Mouli Edward¹ 

¹Department of Orthopedic and Traumatology, Faculty of Medicine, Airlangga University/Dr. Soetomo General Hospital
Surabaya-Indonesia

Correspondence should be addressed to I Putu Gede Pradnyadewa Pradana, Faculty of Medicine, Universitas Airlangga, Jl. Mayjen Prof. Dr. Moestopo No. 6-8, Surabaya 60286, Indonesia. e-mail: i.putu.gede.pradnyadewa-2015@fk.unair.ac.id

ABSTRACT

Background: Giant Cell Tumor (GCT) is a benign tumor but can be malignant and spread to other organs. Common site of GCT develops in long bone, especially in the knee. A lesion that develops in flat bone is considered rare. This case report aims to recognize GCT of bone and its predilection and help improve diagnostics and manage this case to provide better results.

Case Report: A seven-year-old female came with complaints of lump and intermittent pain in left-back. The lump is gradually getting more prominent. The pain is localized in the back mid-area, worsen with any touch around the area. On examination, there is deformity and mass on the posterolateral side at the 9th rib level around 3 cm in diameter. There was tenderness on palpation and limited range of motion (ROM). The cytological and radiological finding suggests GCT of bone. The patient had resection surgery of the lesion. The histopathologic results on the operative specimens confirmed the diagnosis of GCT.

Discussion: An unusual location of GCT lesions needs to be a concern because they can be underdiagnosed not to receive optimal therapy. Inadequate therapy can increase the incidence of recurrence and malignancy changes. In this case, the patient had resection surgery. Postoperatively, the patient is in good condition with no sign of local recurrence.

Conclusion: GCT should be included in the differential diagnosis of rib-originated tumors. Tumor lesions in unusual places other than long bones and occurs on the immature patient should be particular concern and confirmed diagnosis.

Keywords: Giant cell tumor; Ribs; Resection

INTRODUCTION

A giant cell tumor (GCT) in the bone is a bone tumor that generally occurs in long bones in young adults. A giant cell tumor is a benign tumor but can be malignant, aggressive, and spread to other organs.¹ Although rarely deadly, tumors in the benign bones can cause disorders around the tumor that can complicate the condition, especially in the joints.²⁻⁴

Bone GCT generally occurs in young adults aged 20 to 40 years, with a rare incidence in children and older people over 65.⁵ The incidence rate in women is greater than that of men. The most common GCT lesion develops in long bones (80–90%), with most cases occurring on the knee.^{6,7} GCT of the ribs is extremely rare.⁸ GCT lesion can occur with associated diseases, such as Paget's disease, that could develop in facial bones, pelvic, and spine

Predilection of long bones that occurs mainly in the epiphyseal region long bones, but in children can grow in the diaphyseal area.^{6,7}

The preferred therapy for giant cell tumors of the bones is operative treatment. In this case, non-operative therapies could be an alternative, such as using biphosphonate and antibody monochrome denosumab. The resection degree depends on the tumor's location and area, its biological aggressiveness, and the lesion de novo or relapse case. Most patients, especially those with Enneking stage 1 and 2 tumors, can be treated with intralesional curettage with a high chance of healing with good functional results. A variety of adjuvant therapies (including phenols, polymethyl methacrylate, liquid nitrogen, and argon beam lasers) can be used in conjunction with curettage. It may reduce recurrence risk compared to curettage only. Extensive resection can be used for biologically and extensively aggressive wounds, especially those that recur or arise on expendable bones. Reconstruction can be done by polymethyl methacrylate, bone grafting, allograft, or prosthesis, depending on the defect's location and degree.^{2,9,10}

Further learning and understanding in the etiology and pathophysiology of giant cell tumors are indispensable to improve the quality of the treatment of giant cell tumors.¹⁰ This case report aims to understand better and recognize the giant cell tumor of the bone and its predilection, like long bones such as the femur, radius, tibia, and other lesser-known locations such as ribs. This case report also aims to help improve the diagnostics and manage this case to provide better results.

CASE REPORT

A seven-year-old female came with complaints of lump and intermittent pain in the left back (Figure 1). The lump is gradually getting more prominent, and the pain is localized in the back mid-area, worsen with any touch around the area. There was no history of trauma and was not associated with fever, weight loss, or any other constitutional symptoms: no significant history and family history.

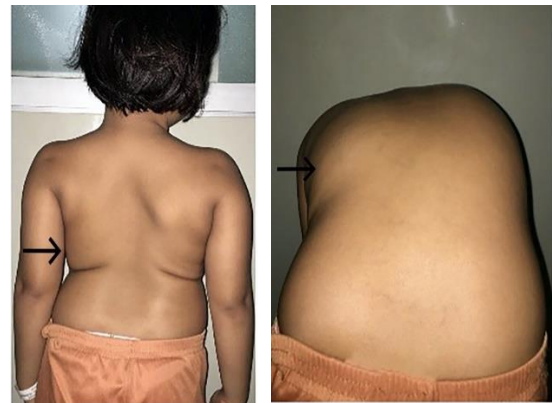

Figure 1. Clinical photo before surgery. Left: backside, right: bending forward.

Deformity and mass on the posterolateral side at the level of the 9th rib around 3 cm in diameter found on the examination, the same color as the surrounding area found in the inspection. There was tenderness on palpation and limited ROM, especially in deep inhalation. Hump was found when the patient bent forward.

X-rays revealed a lytic ballooning lesion on the diaphyseal area in the level of the 9th rib with a narrow transitional zone and cortical thinning with no cortical break and periosteal reaction (Figure 2). There is no sign of metastatic activity found on the lungs.



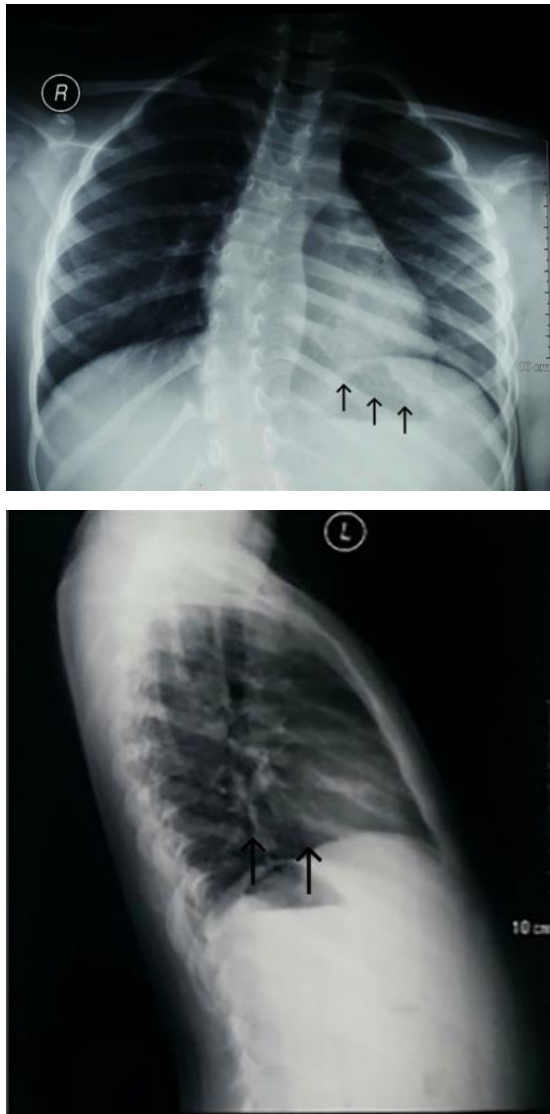


Figure 2. Plain thorax radiography showed a lytic ballooning lesion on the 9th left rib.

Thoracolumbar x-ray showed there is a 10° levoscoliotic alignment on the thoracolumbar region (Figure 3). The pedicle showed no rotation and the soft tissue was normal. CT-Scan of Thorax was performed to measure the exact lesion size and also evaluate soft tissue involvement (Figure 4). This image suggested a lytic lesion with cortical destruction and swelling in the surrounding soft tissues.

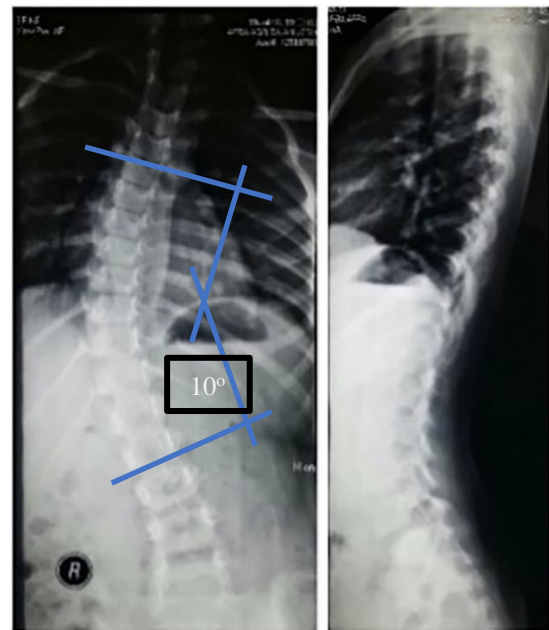


Figure 3. The thoracolumbar x-ray showed levoscoliotic alignment.

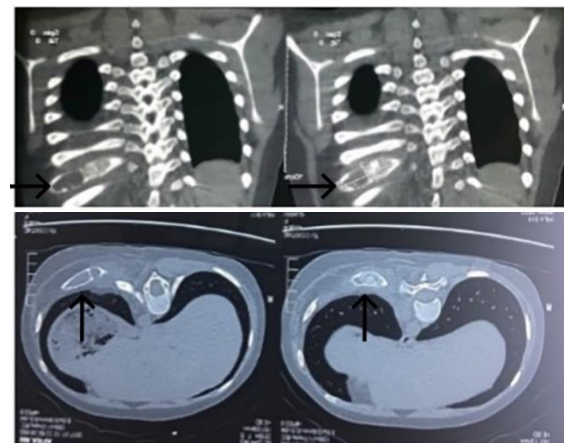


Figure 4. CT scan thorax showed a lytic lesion with soft tissue involvement.

Fine needle aspiration biopsy (FNAB) exam found spreads of the multinucleated giant cell with core number >10, cells with oval to round nucleus that suggesting a Giant Cell Tumor of the Bone (Figure 5). Laboratory investigations were within normal limits and planned for tumor resection. An incision at the 9th intercostal space incise layer by layer until the ninth rib is visualized (Figure 6).

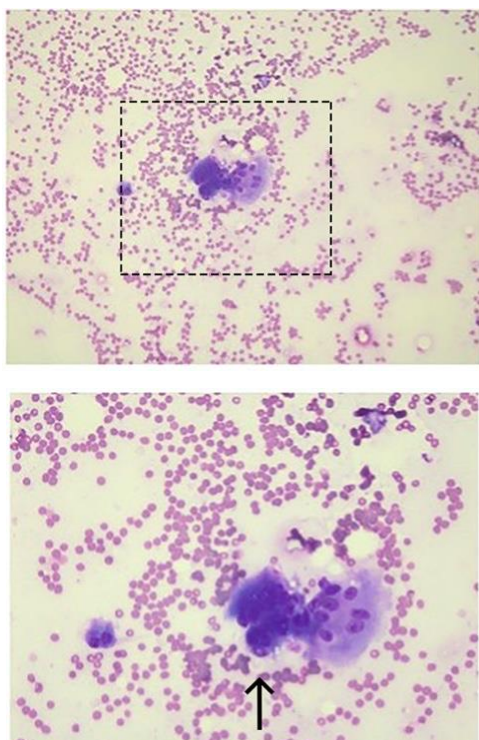


Figure 5. FNAB cytologic

The surgery found and resected bone mass with abnormal shape, ballooning-like at the ninth rib level on the posterior side, around 9cm x 1.5cm. The specimen was then imprint examined with a frozen section during the surgery (Figure 7). The frozen section was cells with oval to round nucleus, multinucleated giant cell with core number >10. Marginal excision was done due to Malignant lesion could be excluded at that time.

The specimen was sent to histopathology for further examination. Histopathology found trabeculae of mature bones and fibrous connective tissues with infiltration of inflammatory lymphocyte, histiocyte, plasma cell, and erythrocyte and hemosiderophages spread (Figure 8).

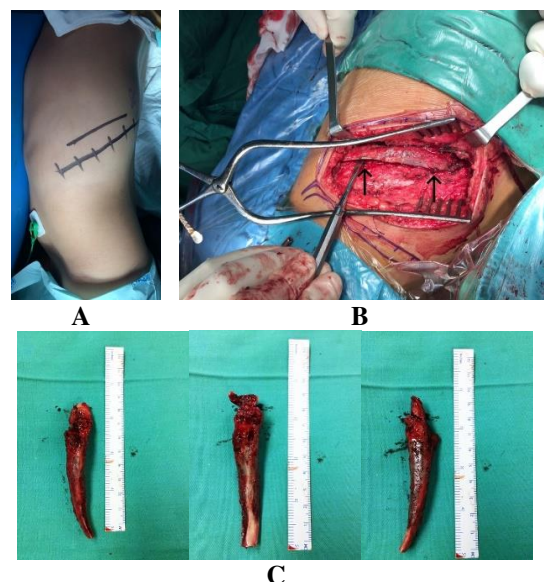


Figure 6. Surgical incision (A), Durante operation (B), Resected tumor tissues (C)

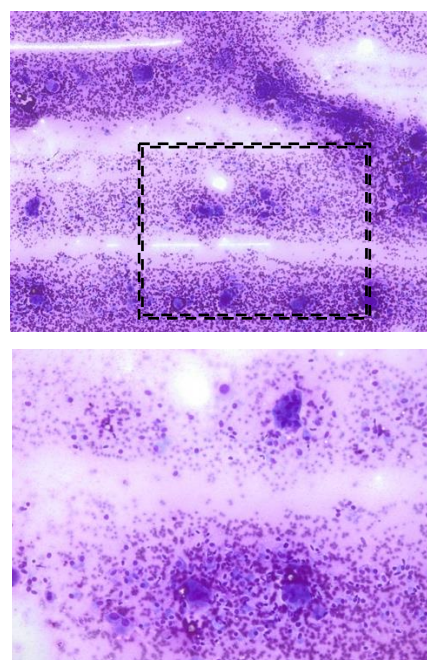
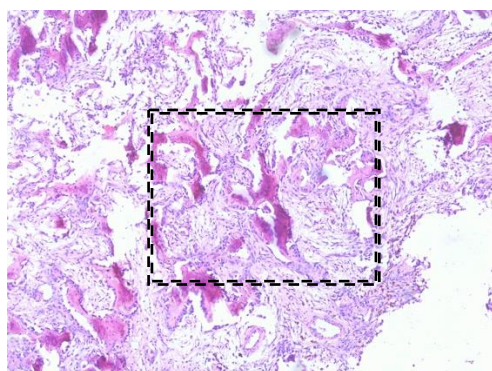
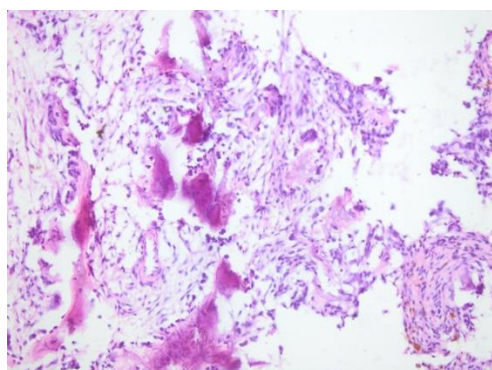


Figure 7. The imprint of frozen section durante operation

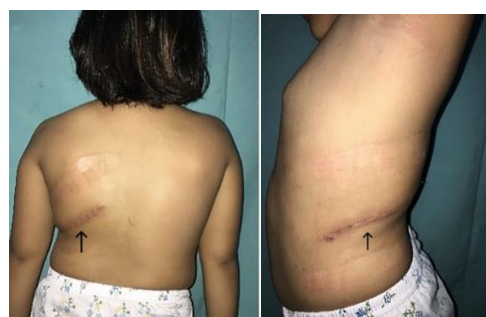

A

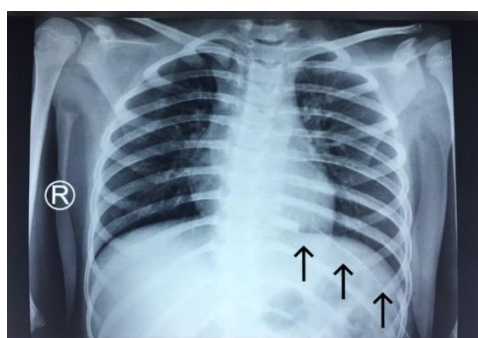


B

Figure 8. Histopathology of the tumor tissue (A), trabeculae of mature bones and fibrous connective tissues (B)



A



B

Figure 9. Post-operative clinical (A), Post-operative thorax x-ray PA (B)

This result supports a benign bone lesion that suggests osteofibrous dysplasia.

The patient was discharged after five days post-operative. The patient had no complaint about her operation wound (Figure 9). The operative scar was good. The patient came back to the outpatient clinic a week later with a better feeling on her back. A month later, the patient could not come to the outpatient clinic due to her home's remote location.

DISCUSSION

A giant cell tumor is a benign tumor but can be malignant, aggressive, and spread to other organs.¹ GCT has a relatively high recurrence rate, and metastases occur in 1% to 9% of patients.¹¹ Giant cell tumor of the bone generally occurs in long bones in young adults, but while the occurrence is rare, it also could happen in another location.^{1,12} Previous research found primary predilection of giant cell tumor is as follows: distal femur, 100 patients (36%); proximal tibia, 93 patients (33%); distal radius, 30 patients (11%); and others location, 57 patients (20%).¹⁰ Several studies stated that their research found 26 cases of GCT in the ribs of the 1870 total cases of GCT. The most common location is in the posterior arc of the rib. There is a tiny occurrence in the anterior arc.^{13,14}

In this case, the patient was a 7-year-old girl who complained of pain in her left back for two years. GCT mainly affects young adults between the ages and 40 years, with some research found a slight tendency toward women



over men.¹ When happening in a skeletally immature patient like in this case, the diagnosis could be challenging. Radiographic findings in the epiphyseal or metaphyseal regions of long bones with open physis might be confused as chondroblastomas due to similar lytic lesion appearance in both cases.¹⁵ CT and MRI findings are not specific and frequently requires open biopsy or core needle biopsy for definitive diagnosis.^{7,16}

The main concern of GCT is its high recurrence rate.¹¹ Treatment of GCT usually operative treatment with curettage or resection as the therapy of choice.⁶ In this case, the patient had a resection surgery on the lesion compliment with a frozen section examination during the surgery. Several studies had suggested a decreased risk of local recurrence and improved recurrence-free survival rate from 84% to 100% compared to intralesional curettage.^{7,17} However, some precautions need to be considered because some studies suggest that resection is associated with higher surgical complications and functional impairment.¹ Non-operative therapies, such as using biphosphonate and antibody monochrome denosumab could be an alternative in some cases with special considerations.¹⁸

There was a discrepancy between the histopathology and the frozen section examination during the operation. From a previous study, the primary causes of inconclusive cytologic diagnosis were hypocellular smears and nonrepresentative biopsy.¹⁹ GCT lesions on the ribs are sometimes difficult to distinguish from its differential

diagnoses, such as osteofibrous lesions, aneurysmal bone cysts, or brown tumors. The histopathological results can be biased because the specimens on the ribs often contain a lot of blood, and the presence of destruction in the soft tissue can produce bias on the examination. However, the clinical finding of a ballooning lesion in the operating durante may serve as a reference for GCT of the rib. These factors could attribute to the result discrepancy and demand for further investigation in the future.^{14,20}

The patient is in good condition with no sign of local recurrence. However, several difficulties were found in the process of diagnosis and treatment. It could be due to several factors, such as unusual location, skeletally immature patient, the surgery, and inadequate pathology examination. More studies need to be done to support and clarify this study result and further improve knowledge about GCT.

CONCLUSION

Our case's remarkable feature is the unusual location of the lesion of GCT at the rib and the occurrence in the skeletally immature patient. Tumor lesions in unusual places other than long bones should be of particular concern and confirmed diagnosis. The understanding of GCT is still improving. While more study is needed, this study result could help understand the diagnosis and treatment of GCT better.

REFERENCES

1. Anshul Sobti DN, Pranshu AM, Sanjay



- AM, Manish AM. Giant Cell Tumor of Bone - An Overview. Arch Bone Jt Surg. 2016;4(1):2-9.
2. Lyon B. Giant cell tumors of bone. Second Edition. Bone Cancer. Elsevier Inc.; 2015. p.437-446.
3. Cowan RW, Singh G. Giant cell tumor of bone : A basic science perspective. Bone. 2013;52(1):238-46.
4. Chakarun CF, Forrster DM, Gottsegen CF, Patel DB, White EA, Matcuk GR. Giant Cell Tumor of Bone: Review, Mimics, and New Developments in Treatment. Radiographics. 2013;33:197-211.
5. Neonakis E, Antoniou G, Triantafyllopoulos. Malignant giant cell tumor of bone. Journal of Research and Practice on the Musculoskeletal System. 2019;3(3):83-86.
6. Raskin KA, Schwab JH, Mankin HJ, Springfield DS. Giant Cell Tumor of Bone. J Am Acad Orthop Surg. 2013;21(1):118-26.
7. Chakarun CJ, Forrester DM, Gottsegen CJ, Patel DB, White EA. Giant cell tumor of bone: Review, mimics, and new developments in treatment. Radiographics. 2013;33(1):197-211.
8. Semionov A, Kosiuk J. Giant Cell Tumor of a Rib Following Denosumab Treatment. Radiol Case Rep. 2018;13(5):1018-1020.
9. Park HL, Yoo I.R, Lee Y, Park SY, Jung CK. Giant Cell Tumor of the Rib: Two Cases of F-18 FDG PET/CT Findings. Nucl Med Mol Imaging. 2017; 51:182-185.
10. Amanatullah DF, Clark TR, Lopez MJ, Borys D, Tamurian RM. Giant Cell Tumor of Bone. Orthopedics. 2014;37(2).
11. Zhang XP, Lu XC, Wang LL, Wei JQ, Yan J, Shao XN et al. Giant cell tumors of bone in patients aged 18 years old or younger: imaging features and tumor characteristics. 2021;2021(14):8389-8397.
12. Orosz Z, Athanasou NA. Giant Cell-Containing Tumors of Bone. Surg Pathol Clin. 2017;10(3):553-573.
13. Gupta V, Mittal R. Giant cell tumor of rib - Rare location on the anterior aspect. Arch Orthop Trauma Surg. 2000;120(3-4):231-2.
14. Heo W, Kang DK, Min HK, Jun HJ, Hwang YH. Giant cell tumor arising from anterior arc of the rib. Korean J Thorac Cardiovasc Surg. 2013;46(5):377-9.
15. Erickson JK, Rosenthal DI, Zaleske DJ, Gebhardt MC, Cates JM. Primary treatment of chondroblastoma with percutaneous radio-frequency heat ablation: Report of three cases. Radiology. 2001;221(2):463-8.
16. Heijden L, Dijkstra PDS, Sande MAJ, Kroep JR, Nout RA, Rijswijk CSP, et al. The Clinical Approach Toward Giant Cell Tumor of Bone. Oncologist. 2014;19(5):550-61.
17. Lausten GS, Jensen PK, Schiødt T, Lund B. Local recurrences in giant cell tumour of bone. Int Orthop. 1996;20(3):172-6.
18. Singh AS, Chawla NS, Chawla SP. Giant-cell tumor of bone: Treatment options and role of denosumab. Biol Targets Ther. 2015;9:69-74.
19. Bhaker P, Mohan H, Handa U, Kumar S. Role of intraoperative pathology consultation in skeletal tumors and tumor-like lesions. Sarcoma. 2014;2014:10-5.
20. Briccoli A, Malaguti C, Iannetti C, Rocca M, Bertoni F. Giant cell tumor of the rib. Skeletal Radiol. 2003;32(2):107-10.

