

Case Report

Osteochondroma Fracture In Young Athlete: A Case Report

Ilham Abdullah Irsyam¹, Andriandi Andriandi¹, Nehemia Meliala²

¹Department of Orthopaedic and Traumatology, Faculty of Medicine, Universitas Sumatera Utara

²Faculty of Medicine, Universitas Sumatera Utara
 Medan – Indonesia

Correspondence should be addressed to Ilham Abdullah Irsyam, Department of Orthopaedic and Traumatology, Faculty of Medicine, Universitas Sumatera Utara, Jl. Dr. Mansyur No. 5, Medan 20155, Indonesia. e-mail: ilham.irsyam@usu.ac.id

ABSTRACT

Background: Osteochondroma is a benign bone tumor that most cases are asymptomatic. The symptoms may occur as a complication of osteochondroma, which is rarely happened. Surgical intervention is needed to treat the complications.

Case: A 20-year old male football athlete presented with pain on his left thigh's lump after he fell during his training. Mass and tenderness on the medial side of the left distal femur were found. Plain X-Ray showed an irregular mass on the left distal femur's surface with a fracture through the stalk of pedunculated osteochondroma. The patient underwent total excision of the osteochondroma.

Discussion: The fracture of the osteochondroma often occurs in teenagers because they are more active physically. It happens due to direct or indirect injury. The treatment of this fracture is controversial between observation or surgical excision. In this case report, the patient could demonstrate full weight-bearing right after the surgery.

Conclusion: Fracture as a complication in osteochondroma often happens to teenagers, and surgery proved to give a good outcome in this case.

Keywords: Osteochondroma; Osteochondroma fracture; Complications; Teenagers

INTRODUCTION

Osteochondroma is the most common primary bone tumor that arises from a defect in the perichondral ring (Ranvier).^{1,2} Osteochondroma usually occurs in long bones, especially around the distal femur's metaphyses, the proximal tibia, or humerus.³⁻⁵ The incidence rate of osteochondroma is 35% of benign tumors and 8% of all bone tumors, although this is considered underestimated because most cases are asymptomatic. Most cases occur in children or adolescents between 10-15 years old.⁴

The clinical feature is usually asymptomatic or painless, slow-growing mass

on the involved bone. However, symptoms may occur due to complications such as fracture, bony deformity, and mechanical joint problems. The symptoms can also appear like the effect of neurological or vascular compression, necrosis, exostosis bursa, or malignant degeneration. Stalk fracture of pedunculated osteochondroma is rare.⁶⁻⁸ Radiographic findings of an osteochondroma is a stalk or a flat protuberance emerging from the surface of the bone. The tumor margin is usually well-defined.⁶

Surgical removal is indicated if the tumor causes pain or functional impairment. Functional impairment is usually caused by

complications such as neurovascular compression and limitation of joint movement. Another indication for surgical removal is related to fracture on the base of the osteochondroma.^{9,10}

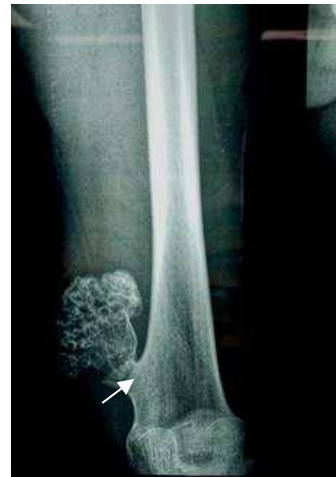CASE REPORT

A 20-year-old male football athlete came to the outpatient orthopedics clinic with a chief complaint of pain on his left thigh's lump. The patient started to feel the pain when he fell during his training. He constantly felt the pain and could not attend his training for 14 days.

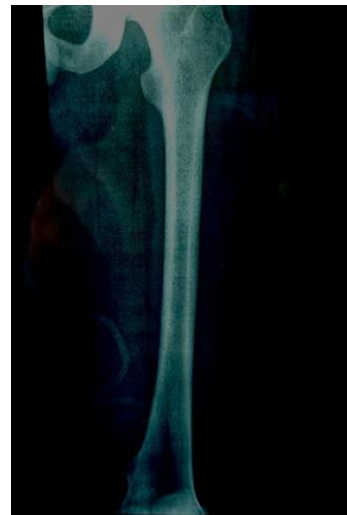The patient was aware of the lump since he was eight years old. The patient also noticed that the lump was slowly getting bigger. Familial history with the same condition was not found. The patient never had this complaint checked before. On physical examination, we found mass and tenderness on the left distal femur's medial side, and limitation of knee movement due to pain, with other status is within normal limit.

There is an irregular mass on the surface of the left distal femur on plain radiograph with a fracture through the stalk of pedunculated osteochondroma (Figure 1).

Total excision with an anteromedial approach of the osteochondroma was performed. The results of the histopathological biopsy confirmed the diagnosis. Grossly, the mass was irregular, greyish, and hard in consistency. In microscopic view, the tissue consists of bone matrix and cartilage matrix with fibrous connective tissue. The bone matrix is a cell with an oval nucleus and clear cytoplasm.



A



B

Figure 1. Antero-posterior plain radiograph of the femur sinistra before excision of osteochondroma (A), Antero-posterior plain radiograph of femur sinistra after excision of osteochondroma (B)

The cartilage matrix consists of chondrocyte and chondroblast with a round nucleus and clear cytoplasm (Figure 2). The patient was able to walk without any help immediately after the operation, and he was able to come back to his soccer training four months after the surgery.

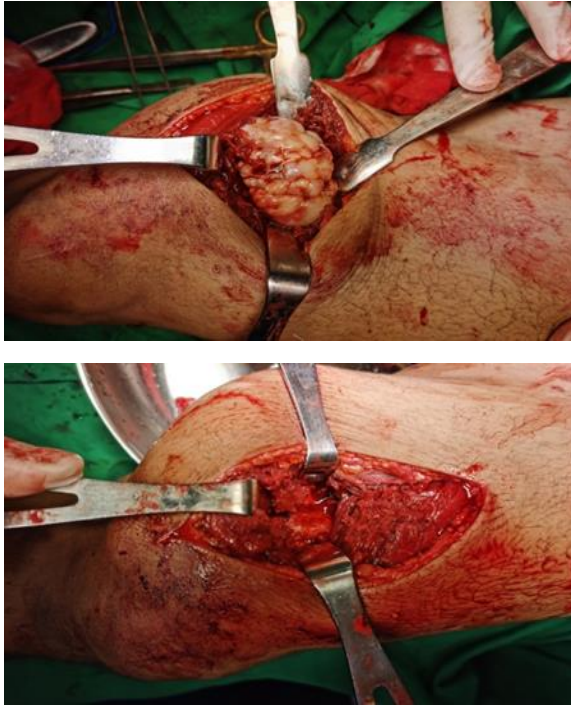


Figure 2. Total excision of osteochondroma

DISCUSSION

Fractures of the osteochondroma usually occur during physical exercise, especially in teenagers who are more active physically. The injury may be direct or indirect contact sports trauma and muscle or tendon injury. Direct injury is usually the reason for osteochondroma fracture. Local pain and swelling usually appear as the symptoms of bone fracture.^{7,11,12}

The fracture is more common around the knee (distal femur and proximal tibia) because the knee joint is more susceptible to injury.^{12,13} In our case, the patient felt pain right after his knee injury during a football game. Since the injury, the patient could not attend his football training.

The treatment of this fracture is controversial. Some studies suggest observation, and others prefer surgical excision.^{7,11} In studies that suggest non-operative, the patient was observed and was

given nonsteroidal anti-inflammatory (NSAID) to reduce pain and the use of an elastic bandage. The patient's activity is limited as well. During the observation period, the patient would be evaluated by radiology examination.^{14,15} We chose to do surgical excision with an anteromedial approach in this case, following a suggestion from other studies that suggest surgery.^{16,17} We did not find any references explaining post-operative care for surgical excision of this kind of case. In our case, the patient did not have any specific post-operative rehabilitation instruction. However, the patient demonstrated full weight-bearing activity right after surgery and was able to do his daily activity after the pain relieved and gradually begun his exercise regime. Surgical removal is indicated if the tumor causes pain, functional impairment, compression, or limitation of joints movement or fracture on the base of osteochondroma. If surgical removal is to be done, the tumor has to be excised completely to avoid recurrences.^{6,7,12}

The patient who has been surgically treated was able to start some sport activity earlier than the patient treated non-operatively.^{7,12,17} Patients who undergo the surgical treatment will be back doing their sports activities in four weeks, faster than patients without surgical treatment, eight weeks. Whether they undergo surgical treatment or not, all of the patients will be asymptomatic in three months.¹² Surgical is necessary due to disturbance of the athlete performance, and after the surgery, he was able to train fully in 4 months with limited rehabilitation resources in his training center.

CONCLUSION

Fracture of osteochondroma is more common in teenagers due to direct or indirect injury. The surgical intervention is indicated if any complications interfere with the patient's activity. In this case, the successful surgical removal of the osteochondroma improves the patient's quality of life.

REFERENCES

1. Alqarni A. Femoral neck osteochondroma in an athlete: A case report and literature review. *Saudi J Sport Med.* 2014;14(2):158.
2. Hill CE, Boyce L, Van Der Ploeg ID. Spontaneous resolution of a solitary osteochondroma of the distal femur: A case report and review of the literature. *J Pediatr Orthop Part B.* 2014;23(1):73–5.
3. Tong K, Liu H, Wang X, Zhong Z, Cao S, Zhong C, et al. Osteochondroma: Review of 431 patients from one medical institution in South China. *J Bone Oncol.* 2017;8(1838):23–9.
4. Gaumer GR, Weinberg DS, Collier CD, Getty PJ, Liu RW. An Osteological Study on the Prevalence of Osteochondromas. *Iowa Orthop J.* 2017;37:147–50.
5. Luo Z, Ye C, Sang H-X. Osteosarcoma in the coracoid process that mimicked an osteochondroma: A case report. *Medicine (Baltimore).* 2017 Nov;96(46):e8608–e8608.
6. Kitsoulis P, Galani V, Stefanaki K, Paraskevas G, Karatzias G, Agnantis NJ, et al. Osteochondromas: review of the clinical, radiological and pathological features. *In Vivo (Brooklyn).* 2008;22(5):633–46.
7. Kose O, Ertas A, Celiktas M, Kisin B. Fracture of an osteochondroma treated successfully with total excision: Two case reports. *Cases J.* 2009;2(8):1–3.
8. Gholamrezanezhad A, Basques K, Kosmas C. Peering beneath the surface: Juxtacortical tumors of bone (part I). *Clin Imaging.* 2018;51:1–11.
9. de Souza AMG, Bispo Júnior RZ. Osteochondroma: ignore or investigate? *Rev Bras Ortop (English Ed.* 2014;49(6):555–64.
10. Whitaker JM, Craig GC, Winship S. Osteochondroma of the Cuboid: A Case Report. *J Foot Ankle Surg.* 2017;56(6):1269–75.
11. Sferopoulos NK. Complicated Fracture and Resorption of an Osteochondroma. *Br J Med Med Res.* 2013;4(8):1719–28.
12. Carpintero P, León F, Zafra M, Montero M, Berral FJ. Fractures of Osteochondroma during Physical Exercise. *Am J Sports Med.* 2003;31(6):1003–6.
13. Mishra P, Gupta A. Non-Traumatic Fracture Of Pedunculated Osteochondroma. A case report and brief review of literature. *J Orthop Case Reports.* 2013;3(4):48–48.
14. Senel A. Non Traumatic Fracture of Pedunculated Osteochondroma : Conservative Management of a Rare Case. *J Clin Diagnostic Res.* 2017;11(9):RD0:10–1.
15. Errani C, Vanel D, Donati D, Picci P, Faldini C. Spontaneous healing of an osteochondroma fracture Case report. *Diagn Interv Imaging.* 2015;96(3):283–5.
16. Kumar A, Patel J, Rawat S. Osteochondroma of Distal Femur. *Int. J. Adv. Res.* 5(5):138–42.
17. Sakamoto A, Okamoto T, Matsuda S. Insufficiency fracture at an osteochondroma bridging the proximal fibula and the tibia: Case report. *J Orthop.* 2018;15(2):384–7.