

How to Cite:

Abdelaal, E. S. E., Elgoushy, A. M., & Akl, M. N. (2022). Evaluation the results of antiglide plating of vertical medial malleolus fractures. *International Journal of Health Sciences*, 6(S4), 3170–3185. <https://doi.org/10.53730/ijhs.v6nS4.9468>

Evaluation the results of antiglide plating of vertical medial malleolus fractures

Elsayed Salah Elsayed Abdelaal

Orthopedic Surgery department, Faculty of Medicine, Al-Azhar University, Egypt
Corresponding author email: Drsayed666@icloud.com

Ali Mohamed Elgoushy

Orthopedic Surgery department, Faculty of Medicine, Al-Azhar University, Egypt

Mohamed Nasr Akl

Orthopedic Surgery department, Faculty of Medicine, Al-Azhar University, Egypt

Abstract---Background; Vertical shear fractures of the medial malleolus occur through supination–adduction loading of the talus onto the articular surface of the medial malleolus, Aim and objectives; to assess the radiological and functional outcomes of open reduction and internal fixation with antiglide plate of vertical shear medial malleolus fracture, Subjects and methods; This prospective case series study was carried out at the Orthopedics Departments of Al-Azhar University and Health Insurance Hospitals. The study included 22 patients with antiglide plating of vertical medial malleolus fracture. The duration of the study ranged from 6-12 months, Result; Number of patients with Antiglide plate for medial malleolus Management in the study population was 9 (40.91%). Number of patients with Antiglide plate for medial malleolus & Semitubular Plate of lateral malleolus Management in the study population was 13 (59%), Conclusion; Surgical management of vertical shear of medial malleolus fracture gave excellent anatomical reduction and rigid fixation to restore articular congruity, help to facilitate early mobilization and hence to achieve optimal ankle function. The antiglide plate fixation is readily available and cost significantly less than a precountoured anatomic specific type of fixation.

Keywords---antiglide plating, malleolus, supination, vertical.

Introduction

Vertical shear fractures of the medial malleolus occur through supination–adduction loading of the talus onto the articular surface of the medial malleolus

.^{1, 2} Vertical shear fractures of the medial malleolus are less common than transverse fractures. There are a wide variety of techniques available for fixation of these fractures, including various cortical screws, cancellous screws, tension bands, and antiglide plates.³ Fixation of these fractures must be sufficient to maintain stable reduction of the ankle joint articular surface allowing early range of motion, maintaining congruency of the ankle joint, and decreasing the risk of future post-traumatic arthritis to maximize functional outcome.⁴

These fractures are often treated successfully with buttress or antiglide plates and screws with neutralization plates. Studies have shown that both neutralization and antiglide plates and screws placed perpendicular to the fracture line are stable fixation methods. Neutralization has been shown to offer more rigidity than that of 2 parallel screws placed perpendicular to the fracture line. However, another study demonstrated the converse.⁵ The study aimed to assess the radiological and functional outcomes of open reduction and internal fixation with antiglide plate of vertical shear medial malleolus fracture.

Patients and Methods

Twenty two 22 adult patients with vertical shear medial malleolus fracture were included in this study. Informed consent was taken from all patients as regards performance of the study. The included study population were adult patients with acute vertical shear medial malleolus fracture who were admitted to Orthopedic Departments at insures and military Hospitals, treated by internal fixation with Antiglide plate and screws during 1st week.

Inclusion criteria: Age above 18 years and Closed / Open Gustilo Type I, II.

Exclusion criteria: Open fracture type III, patients medically unfit for surgery and timing of surgery: During 1st week after injury.

Methods

For all included patients, the following were done: Detailed clinical history, detailed clinical examination, plain X-ray ankle joint and tibi AP, lateral and mortise views and 4. Routine Laboratory investigation

Methods of initial examination

All patients were examined both clinically and radiological on admission to the hospital as follow: Full history was taken from all patients: The day of operation in our study are different according to clinical evaluation which is:- (12) Patients were done operation at same day of admission, and (10) Patients operations were done after (5) day of admission due to swelling and Ecchymosis. Local assessment of the fracture site: Pain: All patients represented with pain on the injured ankle and tenderness. Movement: All patients were with limited movement around injured ankle. All patients were non weight bearing on injured ankle. Edema: All patients represented by edema on the injured ankle. Local assessment of associated injuries including skin condition and other fractures: Fourteen (14) patients had isolated vertical shear medial malleolus fracture and Eight (8) patients associated with lateral malleolus fracture injuries. Skin condition over

the fracture site was intact in all patients. Radiological examination: 3 plain X-rays views were obtained for each case (antero-posterior - lateral - anteroposterior with the limb internally rotated 20 degrees "mortise view") on the ankle joint.

Methods of treatment

Patient preparation: Prophylactic antibiotics: 3rd generation cephalosporins (2 grams before the operation and 2 grams every 24 hours for 5 successive days then shift to oral antibiotics after operation done). Anaesthesia: All patients were operated under spinal anesthesia, the patient was put in supine position, and Pneumatic tourniquet was applied to the proximal thigh after noting the time. The affected limb was draped from the knee joint to the nail tip and then painted betadine solution the foot was covered with a glove.

Operative Procedure

Patient positioning: Twenty two 22 adult patients were operated upon in supine position. All cases were operated upon by open technique with complete exposure of the fracture. The pneumatic tourniquet was applied to the affected limb for all patients then preparation and draping the affected limb.

Approaches to the Medial Malleolus

1. Landmarks and Incision: Under aseptic technique, Start the incision 2cm distal to the anterior tip of the medial malleolus. Curve the incision towards the anterior edge of the medial malleolus and in the direction of the middle of the distal tibia.
2. Surgical dissection: Expose the anterior part of the fracture site, free the periosteum from the edges of the medial malleolus to the distal tibial joint surface and inspect the joint. Remove the periosteum posteriorly only sufficiently to control reduction (Figure 1).

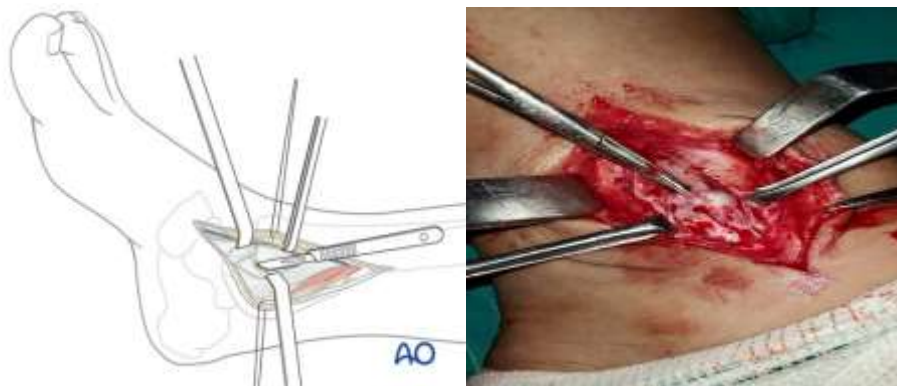


Fig (1): Medial Malleolus Surgical Incision and Exposure of the fracture site

Reduction

Cleaning the fracture site: Remove any small, loose fragments which may prevent anatomic reduction and free the periosteum from the bone edges. If the articular

surface has been impacted, this must carefully disimpacted before the medial fragment is reduced.

Anatomical reduction: In the presence of an impacted medial corner fragment, gently open the main vertical fracture plane by retraction of the medial malleolus medially (opening the book). The impacted “corner” fragment, usually identifiable by its articular cartilage, after irrigation if necessary, can then be seen. Disimpact and carefully tease back the fragment into its anatomical position. Then close the book by careful reduction of the medial malleolus (Figure 2).

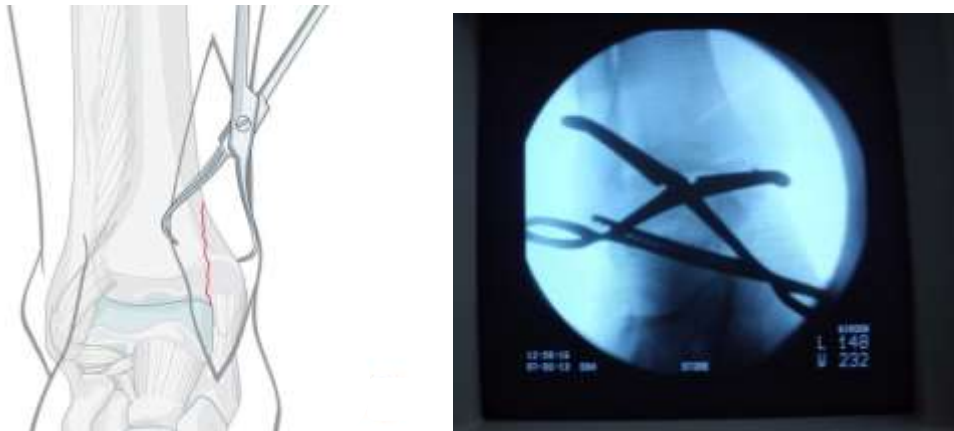


Figure (2): Medial Malleolus fracture Reduction

Reduce the fracture anatomically with the help of small pointed reduction forceps. Take care with the soft tissues. Do not strip the periosteum more than necessary.

Fixation

Application of plate: Once the fracture is identified and cleared of interposed periosteum in usual fashion, the anatomic reduction is confirmed on anteroposterior and lateral fluoroscopic images, the small T plate is contoured to the center of medial aspect of the medial malleolus. The screw hole just proximal to the fracture site is filled first by 3.5mm cortical screws to prevent further proximal displacement of the fracture, then filled the distal hole to the fracture site by 4.0mm cancellous screws. After filling all holes of plate by cortical and cancellous screws, confirm the position of plate and reduction by antero-posterior and lateral fluoroscopic images. It is essential to ensure that no screws violate the ankle joint (Figure 3).

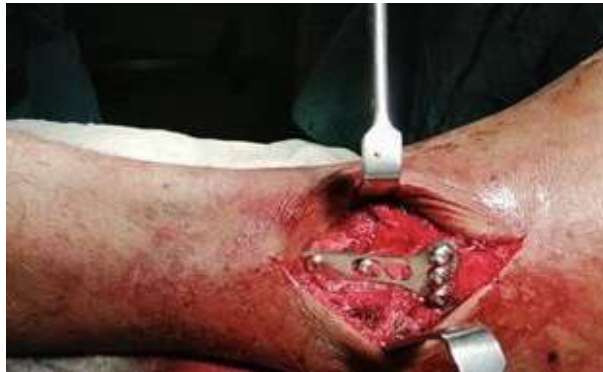

Figure 3: Medial malleolus fixation by small T-antiglide plate. Fixation of lateral malleolus with semitubular plate (figure 4, 5, 6, 7)

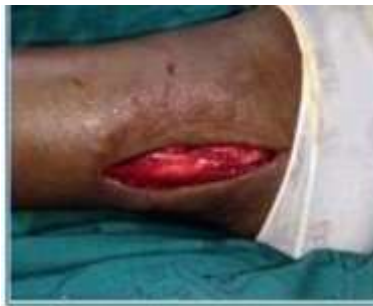

Fig 4: Lateral skin incision for lateral malleolus

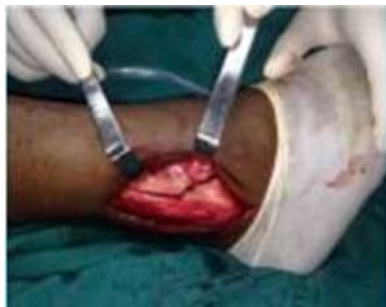

Fig 5: Exposure of fracture in lateral malleolus

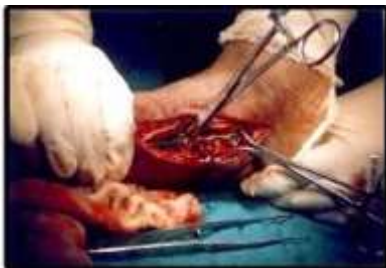

Figure 6: Fracture reduced and semitubular plate in situ

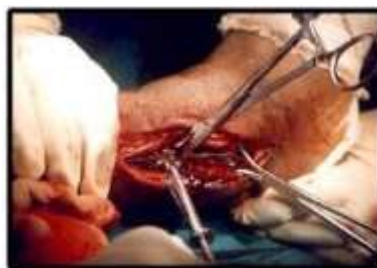

Figure 7: Fixation of semitubular plate with 3.5mm cortical screw

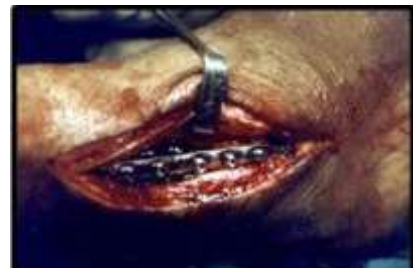

Figure 8: lateral malleolus fixed with semitubular plate

After irrigation of the surgical site by normal saline the Periosteum layer and subcutaneous and skin layer is closed with suture. In case with lateral malleolus we should be start close lateral site incision then close medial site incision (Figure 9). Dressing and sterile 4x4 gauze dressing are placed over the wound. Standard short leg plaster splint is applied for immediate postoperative comfort. (Figure 10)

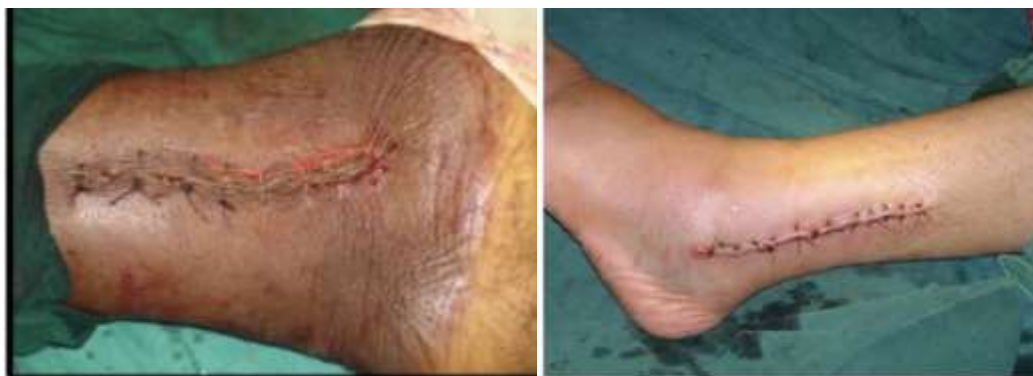

Figure 9; Skin incision after closure

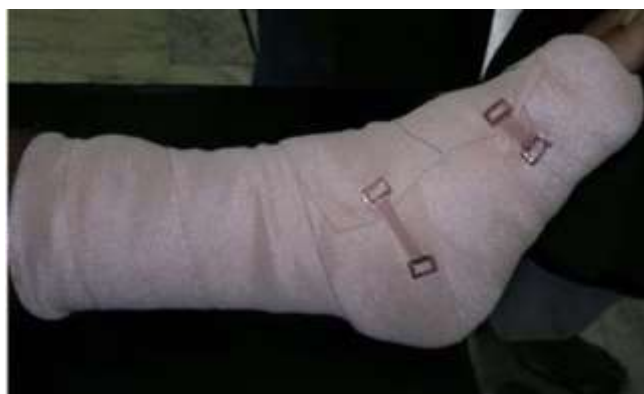

Figure 10: Short leg plaster splint

Post-operative management: Post operatively all patients received Antibiotics consisting of Cefotaxim and Amikacin were continued for 5 days. Analgesics and anti-edematous drugs were given. X-rays anteroposterior, lateral and mortise views were taken. Discharged patients with instruction of non-weight bearing crutch walk for a period of 6 weeks and to come for follow-up after 2 week.

FOLLOW UP: Patients were followed up at 2 weeks, 4 weeks, 6 weeks post operatively. After two weeks remove the stitch and change the slab. All the patients were followed up both Clinical examination regarding tenderness and movement of ankle and radiologically for a period of at least 3 months. The time to union was calculated from the day of surgery to the date of bone healing, which was assessed by the fracture gap being not visible on the two views of plain radiographs. At 6 weeks x- ray of the ankle was taken both AP and lateral views and looked for signs of fracture union and then were advised partial weight bearing for further period of 6 weeks with elevation of the limb at night times. Regular follow up was done at 1, 2 and 6 months after discharge till the fracture

united, Patients were allowed full weight bearing on the affected limb after three 3 month. In our study we used the Biard and Jackson ankle scoring to assessment of result.

Results

	Study population (n = 22)	
	n	%
Management		
- Antiglidle plate for medial malleolus n (%)	9	41%
- Antiglidle plate for medial malleolus & Semitubular Plate of lateral malleolus n (%)	13	59%

Table (1): Management of the studied group

Table (1) showed Management of the studied group. Number of patients with Antiglidle plate for medial malleolus Management in the study population was 9 (40.91%). Number of patients with Antiglidle plate for medial malleolus & Semitubular Plate of lateral malleolus Management in the study population was 13 (59%).

	Study population (n = 22)	
	n	%
Mechanism of Injury		
- Supination & Adduction n (%)	22	100%
- Other mechanism n (%)	0	0%

Table (2): Mechanism of Injury among the studied group

Table (2) showed Mechanism of Injury among the studied group. Number of patients with Supination & Adduction mechanism of Injury in the study population was 22 (100.00%).

	Study population (n = 22)
Time of Union (weeks)	
Mean \pm SD.	12.27 \pm 1.98
Median (IQR)	12 (10 - 14)
Range (Min-Max)	6 (10 - 16)

χ^2 : Chi- Square test

SD: standard deviation

Table (3): Time of union among the studied group

the study population ranged from 10 to 16 with mean \pm SD = 12.27 \pm 1.98.

	Study population (n = 22)	
	n	%
Pain intensity		
- While walking on uneven surface n (%)	4	18%
- None n (%)	18	82%

Table (4): Pain intensity among the studied group

Table (4) showed Pain intensity among the studied group. Number of patients with Pain while walking on uneven surface in the study population was 4 (18.18%)

	Study population (n = 22)	
	n	%
Activities of daily life		
- Same as before injury n (%)	6	27%
- Loss of tempo n (%)	16	73%
- Change to a simple job n (%)	0	0%
- Severly impaired work capacity n (%)	0	0%

Table (5): Activities of daily life among the studied group

Table (5) showed Activities of daily life among the studied group. Number of patients with Activities as same as before injury in the study population was 6 (27.27%). Number of patients with Loss of tempo of daily activities in the study population was 16 (72.83%).

	Study population (n = 22)
Total Score	
Mean \pm SD.	92.95 \pm 3.67
Median (IQR)	95 (91.25 - 95)
Range (Min-Max)	10 (85 - 95)

χ^2 : Chi- Square test

SD: standard deviation

Table (6): Olerud and Molander total Score among the studied group

Table (6) showed Olerud and Molander total Score among the studied group. The total Score in the study population ranged from 85 to 95 with mean \pm SD = 92.95 \pm 3.67.

	Study population (n = 22)	
	n	%
Rating		
- Excellent n (%)	16	73%
- Good n (%)	6	27%

Table (7): Rating among the studied group

Table (7) showed Rating among the studied group. Number of patients with Excellent Rating in the study population was 16 (72.73%). Number of patients with Good Rating in the study population was 6 (27.37%).

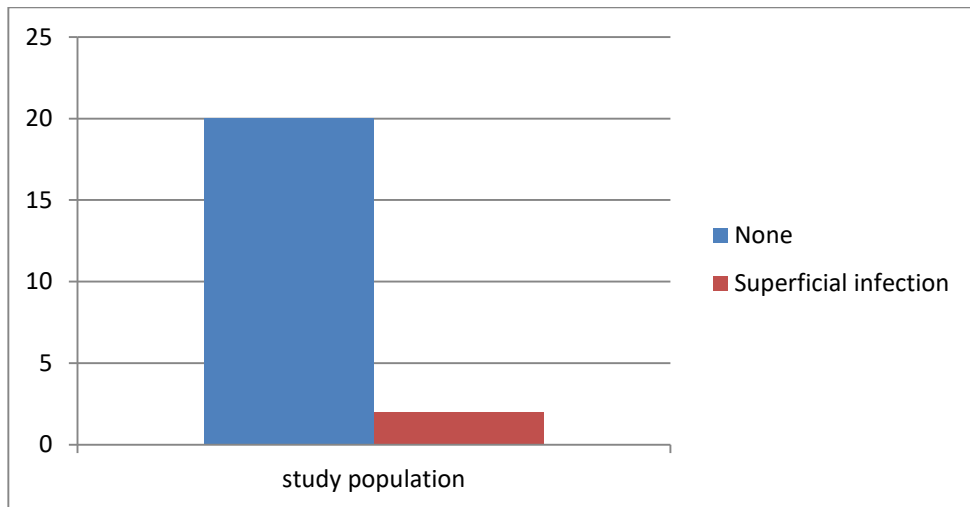


Figure (11): Bar chart showing study population data regarding Complications

Figure (11) showed Complications distribution among the studied group. Number of patients with no Complications in the study population was 20 (90.91%). Number of patients with superficial infection Complications in the study population was 2 (9.19%).

Case (1)

Male patient 55 years old admitted with vertical shear medial malleolus fracture and lateral malleolus fracture (danis weber type A), It was treated with T shape Antiglide plate and screws fixation for medial malleolus, and semi tubular plate for lateral malleolus .Operation was done at same day of admission, the patient follow up for sex (6) months and final result according to Olerud and Molander scoring system was excellent.

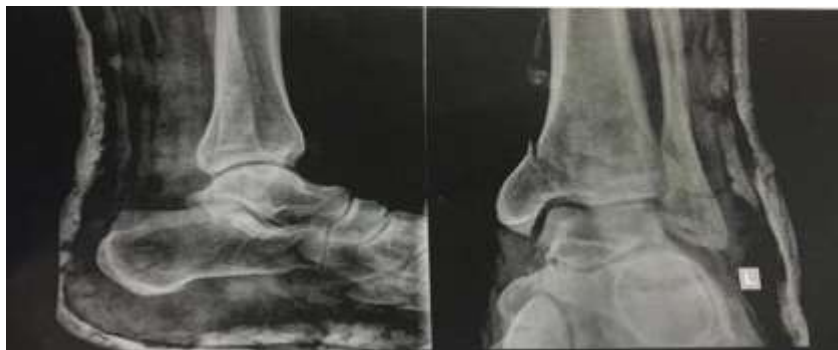

Figure (12): The preoperative x ray

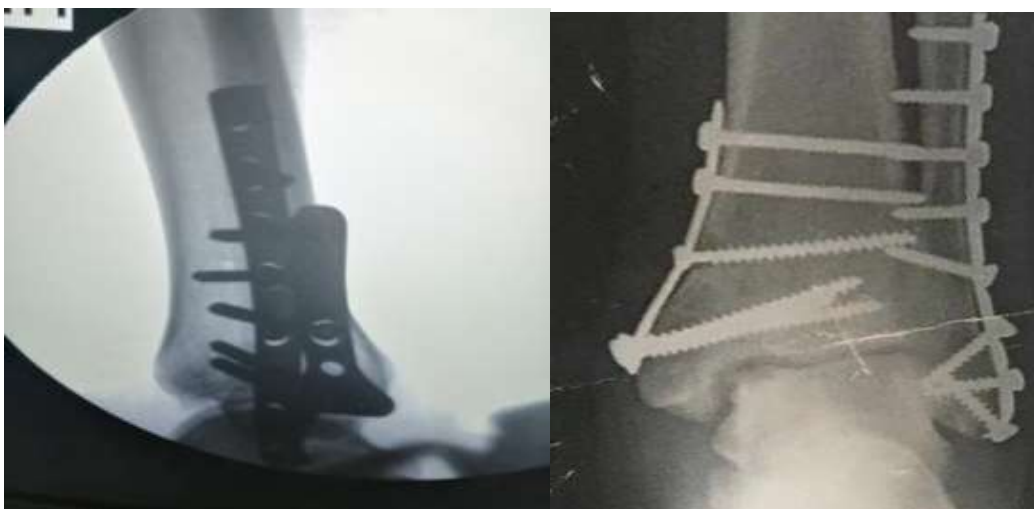

Figure (13): Immediate postoperative x-ray

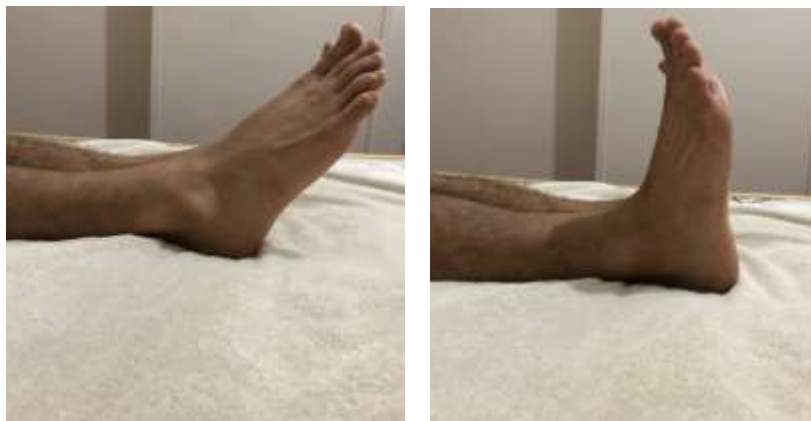

Figure (14): clinical photo after (6) months showing Dorsiflexion and plantarflexion of the ankle

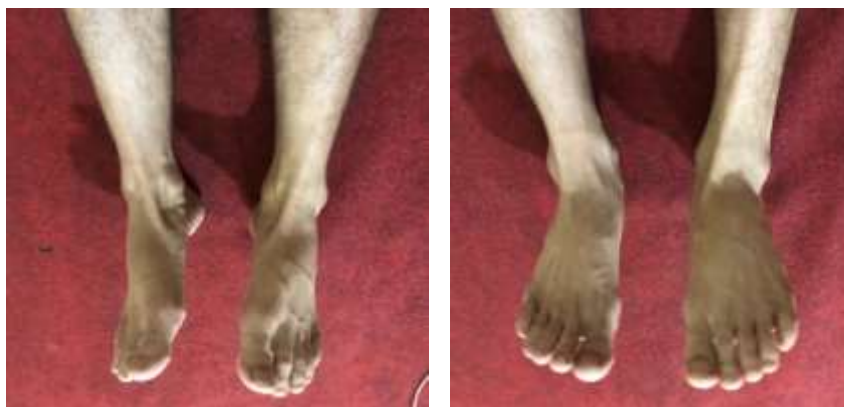

Figure (15): clinical photo after (6) months showing inversion and eversion of ankle

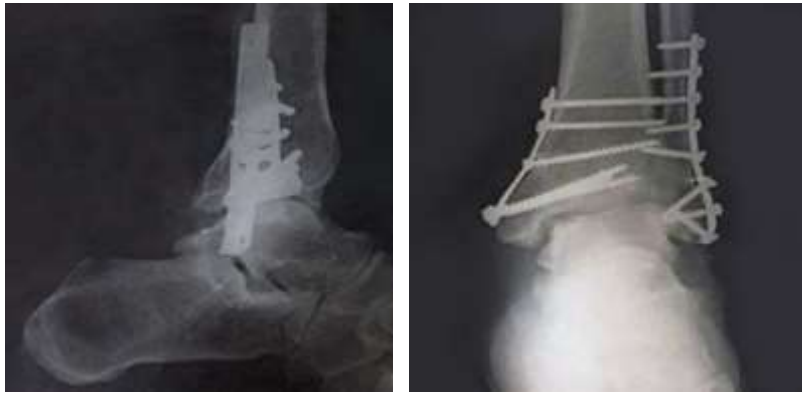

Figure (16): Antero posterior and lateral view of last follow up x-ray

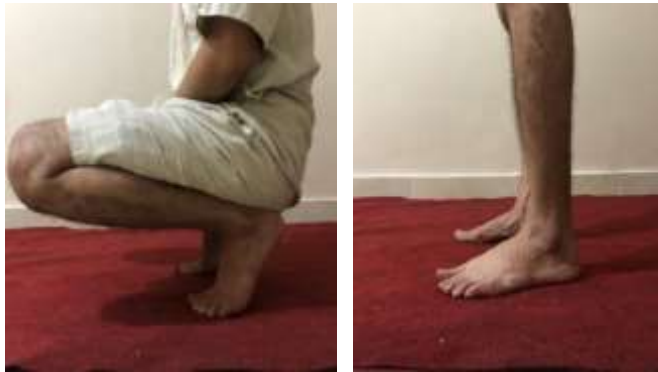

Figure (17): clinical photo after (6) months standing and squatting position

Case 2

Male patient 30 years old admitted with isolated vertical shear medial malleolus fracture (danis weber type A), It was treated with T shape Antiglide plate and screw fixation. Operation was done at same day of admission, the patient follow up for eight (8) months and final result according to Olerud and Molander scoring system was excellent.

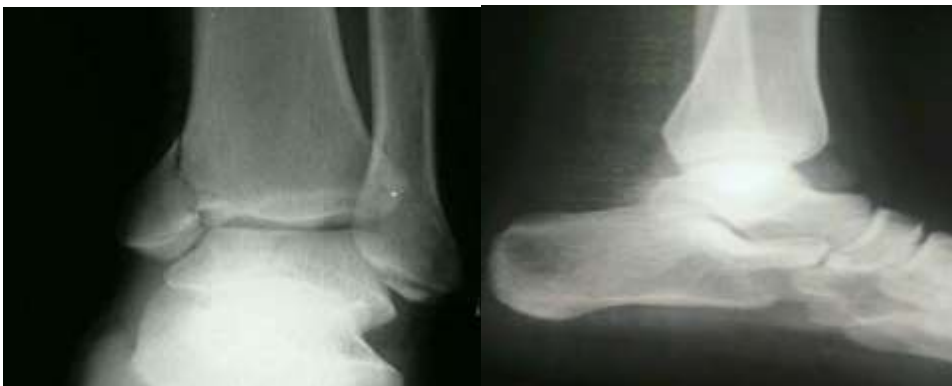

Figure (18): The preoperative x ray.

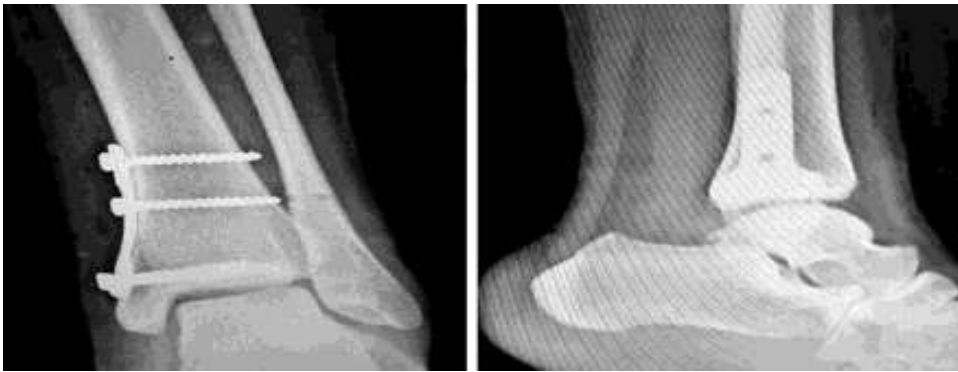

Figure (19): Immediate postoperative x-ray

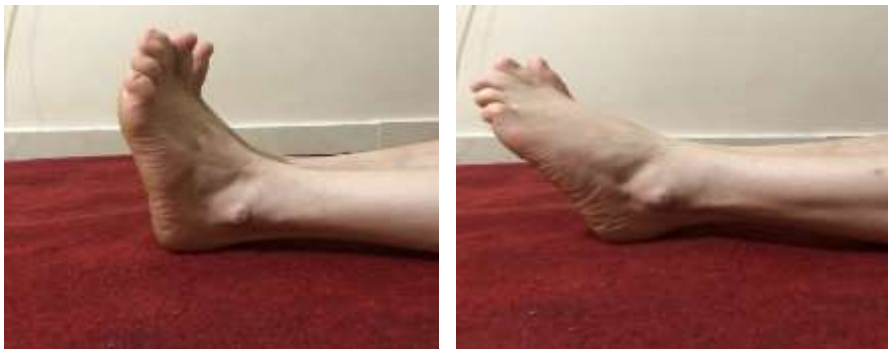

Figure (20): clinical photo after (8) months showing Dorsiflexion and plantarflexion of the ankle

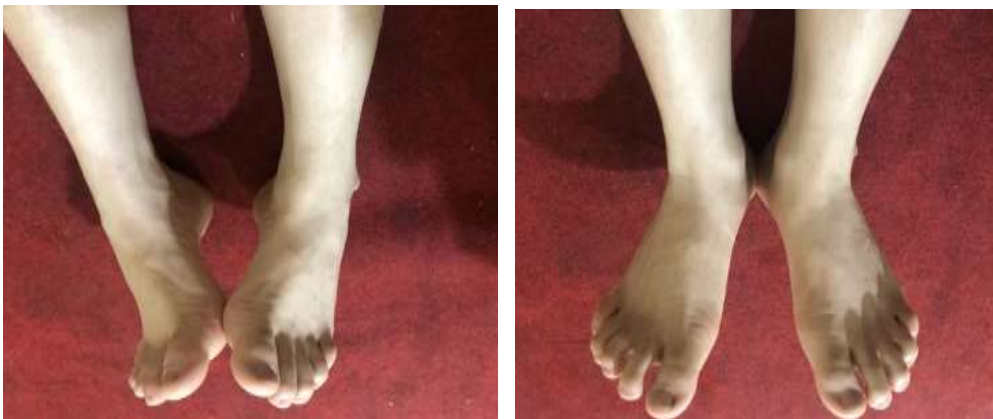

Figure (21): clinical photo after (8) months showing Inversion and eversion of ankle

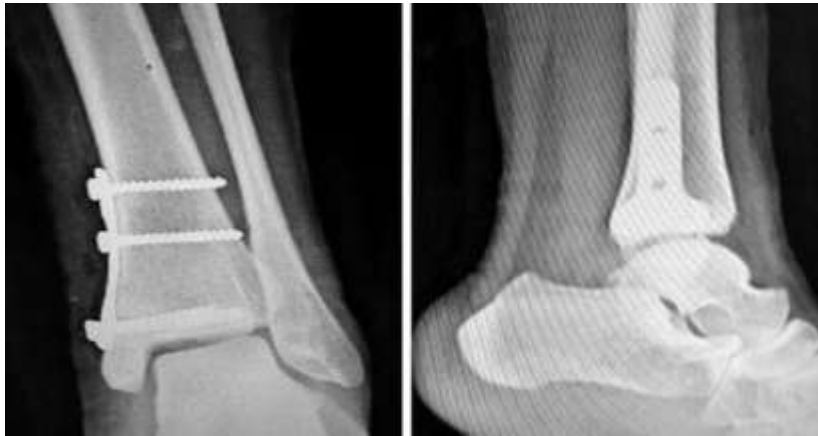

Figure (22): Antero posterior and lateral view of Last follow up x-ray

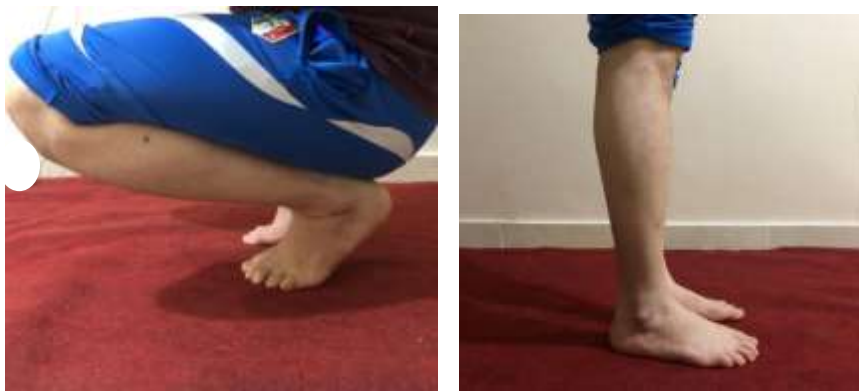

Figure (23): clinical photo after (8) months showing standing and squatting position

Discussion

This prospective case series study was carried out at the Orthopedics Departments of Al-Azhar University and Health Insurance Hospitals. The study included 22 patients with antiglide plating of vertical medial malleolus fracture. The duration of the study ranged from 6-12 months. As regard demographic data of the studied group. The Age in the study population ranged from 21 to 65 with mean \pm SD = 44.91 ± 14.7 . 45% of patients were in 51-65 years Age groups. 36% of patients were in 20-35 years Age groups. As regard sex distribution of the studied group. 12 (54.55%) of our study group were males. 10 (45%) of them were females.

Our results were supported by study of Gaurav et al., ⁶ as they reported that majority of the patients (43.33%) included in the study were in the age group 40-59 years. Out of total 30 patients considered in study 20 (66.66%) were male and 10 (33.33%) were female. Similarly, Arora et al., ⁷ demonstrated that the 64% of their studied cases were in age group 41-50 years. The majority of them (84%) were males. In the study in our hands, as regard Management of the studied group. Number of patients with Antiglide plate for medial malleolus Management in the study population was 9 (40.91%). Number of patients with Antiglide plate

for medial malleolus & Semitubular Plate of lateral malleolus Management in the study population was 13 (59%). As regard mechanism of Injury among the studied group. Number of patients with Supination & Adduction mechanism of Injury in the study population was 22 (100.00%).

Our results were supported by study of El-Alfy et al., ⁸ as they reported that patients with combined both medial and lateral malleoli were managed using antiglides plate for medial malleolus & semitubular plate for lateral malleolus, while patients with only medial malleolus injury was managed by antiglides plate. Our results showed that as regard time of union among the studied group. The Time of Union in the study population ranged from 10 to 16 with mean \pm SD = 12.27 ± 1.98 . As regard Pain intensity among the studied group. 4 (18.18%) of patients had Pain while walking on uneven surface. This is the same as Ahn et al., ⁹ in their study, which included 70 patients that were followed up for a minimum of 12 (mean 55, range 12 to 109) months. Bony union was obtained in all cases after a mean of 57 (range 37 to 81) days (nearly 14 weeks).

Additionally, Sukur et al., ¹⁰ found in their study that the follow-up evaluation at the 12th postoperative week showed union in all patients where the presence of a bridging callus in at least 3 cortices or the disappearance of the fracture line was accepted as radiological union. Also, Zheng et al., ¹¹ demonstrated that after surgery, patients resumed normal walking from 12 to 17 weeks with an average of (14.5 ± 1.3) weeks. In the study of Amanatullah et al., ¹² the average stiffness in tension was $177.7 \text{ N/mm} \pm 26.2 \text{ N/mm}$ for the plate group, $124 \text{ N/mm} \pm 15.9 \text{ N/mm}$ for the tension band group, $141.2 \text{ N/mm} \pm 23.9 \text{ N/mm}$ for the parallel group, and 112 ± 22.2 for the divergent group. The average stiffness in tension of the plate construct was significantly greater than that of any other construct ($p < 0.05$). The average stiffness in tension of the tension band, parallel screw, and divergent screw groups were not significantly different from each other ($p > 0.05$).

The current study showed that as regard Olerud and Molander total Score among the studied group. The total Score in the study population ranged from 85 to 95 with mean \pm SD = 92.95 ± 3.67 . As regard Rating among the studied group. Number of patients with Excellent Rating in the study population was 16 (72.73%). Number of patients with Good Rating in the study population was 6 (27.37%). In accordance with our results study of El-Alfy et al., ⁸ as they reported that Baird and Jackson's scoring system was 95.3 ± 4.9 that ranged from 76 to 98. Most of the studied group, 68.2% had excellent outcome, 22.7% of them had good outcome and 9.0% had poor outcome.

This is consistent with the outcome of most studies as Velez et al., ¹³ with 4.5% of cases with poor functional results. In addition, in the study of Singh et al., ¹⁴ they reported 5.4% had poor results. Besides, the clinical outcome of plating fixation of displaced fractures is satisfying, and poor results are infrequent. Moreover, the total outcome of the current study is in agreement with Jones et al. (79) who concluded that antiglides plating technique with lag-screw placement is biomechanically superior to the other 2 constructs commonly used. However, the outcome of the current study is close to Kilian et al., ¹⁵ where the final total score was 94.5 ± 6.0 (range 85– 100) points but they showed no dissatisfied patients.

In addition, Gaurav et al., ⁶ revealed that the mean Baird and Jackson score at the end of 6 months for CCS group was 94.06 and for TBW group was 95.13. The mean score in TBW group was found to be better as compared to CCS group. On applying unpaired t test, statistically significant difference was found (p value-0.018). Out of the 30 patients treated 36.66% had excellent results, 50% had good results and 13.33% had fair results. In the study in our hands, as regard Complications distribution among the studied group. Number of patients with no Complications in the study population was 20 (90.91%). Number of patients with superficial infection Complications in the study population was 2 (9.19%).

Our results were in agreement with study of El-Alfy et al., ⁸ as they reported that regarding complications in their study, most of the studied group (90.9%) didn't have any complications and only two patients (9.1%) had superficial infection with no other complications. Similarly, Zheng et al., ¹¹ demonstrated that no complications such as loss of reduction, loosening or rupture of internal fixation, nonunion of fracture, radiographic appearance of osteoarthritis occurred during following up. This is in contrast with Kilian et al., ¹⁵ where complications were observed in 3 (15%) patients of an antiglide plate (2 hardware irritation & 1 skin reaction with no infection).

Conclusion

Surgical management of vertical shear of medial malleolus fracture gave excellent anatomical reduction and rigid fixation to restore articular congruity, help to facilitate early mobilization and hence to achieve optimal ankle function. Osteosynthesis using the small T-plate in the vertical shear of medial malleolus fracture gave a good choice of rigid fixation. The antiglide plate fixation is readily available and cost significantly less than a precountoured anatomicspecific type of fixation.

Conflict of interest: no conflicts of interest.

References

1. Wegner, A. M. Antiglide plating of vertical medial malleolus fractures provides stiffer initial fixation than bicortical or unicortical screw fixation. Clin. Biomech. 2016; 31, 29–32 .
2. Heckman JD, Bucholz RW, Tornetta III P. Rockwood and green's fractures in adults: Two volumes plus Integrated content. Website, 2015.
3. Blake S, Yakubek G, Shaer J. Use of a Locked Fibular Plate for Fixation of a Vertical Shear Medial Malleolus Fracture: A Case Report. J. Foot Ankle Surg. 2015; 54(6):1202-5
4. Simanski CJ. Functionuy5al treatment and early weightbearing after an ankle fracture: a prospective study. J. Orthop. Trauma 2006; 20, 108–114 .
5. Dumigan RM, Bronson DG, Early JS. Analysis of fixation methods for vertical shear fractures of the medial malleolus. J. Orthop. Trauma 2006; 20: 687–691 .
6. Gaurav S, Gunaki RB, Gaonkar NK, Choudhary S. A comparative study of functional outcome of ankle joint after medial malleolar fractures treated with

- ORIF with TBW and CC screws. *International Journal of Orthopaedics*. 2019; 5(2):77-83.
7. Arora KK, Kapila R, Chaudhary P, Singh R, Kapila S. Efficacy of antiglide plate in vertical shear fractures of medial malleolus due to supination adduction injury around ankle: a prospective clinical study. *International Surgery Journal*. 2021; 8(12):3626-33.
 8. El-Alfy A, Abd-ELdayem A, Gaber AM, Alashher AM. Evaluation of the Results of Antiglide Plating of Vertical Medial Malleolus Fractures. *The Egyptian Journal of Hospital Medicine*. 2021; 82(1):137-41.
 9. Ahn J, Kim S, Lee J. Incidence of peroneal tendinopathy after application of a posterior antiglide plate for repair of supination external rotation lateral malleolar fractures. *J. Foot Ankle Surg*. 2016, 55: 90–93.
 10. Sukur E, Akmanb Y, Gokcenc H. Open reduction in pilon variant posterior malleolar fractures: radiological and clinical evaluation. *Orthop Traumatol Surg Res*. 2017; 103: 703–707.
 11. Wegner AM, Wolinsky PR, Robbins MA, Garcia TC, Maitra S, Amanatullah DF. Antiglide plating of vertical medial malleolus fractures provides stiffer initial fixation than bicortical or unicortical screw fixation. *Clinical Biomechanics*. 2016; 31: 29-32.
 12. Amanatullah DF, Khan SN, Curtiss S, Wolinsky PR. Effect of divergent screw fixation in vertical medial malleolus fractures. *J. Trauma Acute Care Surg*. 2012; 72: 751–754
 13. Velez N, Moreno A, Martínez O. Posterior antiglide plate vs lateral plate to treat Weber type B ankle fractures. *Acta Ortopédica Mex*, 2004; 18: 39–44.
 14. Singh R, Kamal T, Roulohamin N. Ankle fractures: a literature review of current treatment methods. *Open J. Orthop*, 2014; 4: 292–303.
 15. Kilian M, Csörgö P, Vajczikova S. Antiglide versus lateral plate fixation for Danis-Weber type B malleolar fractures caused by supination-external rotation injury. *J Clin Orthop Trauma*, 2017; 8: 327–331.