

How to Cite:

Sankararaman, B., Thasneem, E. A., Natchiar, A., & Jabbar, J. A. (2022). Tyson's Glands: Non existent entity or a real one? The conundrum revisited. *International Journal of Health Sciences*, 6(S3), 4637–4641. <https://doi.org/10.53730/ijhs.v6nS3.6951>

Tyson's Glands: Non existent entity or a real one? The conundrum revisited

B. Sankararaman

Department of General Surgery, Vinayaka Mission's Medical College, Vinayaka Mission's Research Foundation (Deemed to be University), Karaikal, Puducherry, India-609609

Thasneem E. A.

Department of General Surgery, Vinayaka Mission's Medical College, Vinayaka Mission's Research Foundation (Deemed to be University), Karaikal, Puducherry, India-609609

Arafath Natchiar

Department of General Surgery, Vinayaka Mission's Medical College, Vinayaka Mission's Research Foundation (Deemed to be University), Karaikal, Puducherry, India-609609

Jassim A. Jabbar

Department of General Surgery, Vinayaka Mission's Medical College, Vinayaka Mission's Research Foundation (Deemed to be University), Karaikal, Puducherry, India-609609

Abstract--Tyson's glands were supposed to be modified sebaceous glands said to be located on either side of frenulum of prepuce. They were first described by Edward Tyson in the 17th century as macroscopic structures on the corona of the penis, interpreting them as the source of smegma. We report a case of 65-year-old male who presented with the complaint of swelling in the prepuce, (the common location where Tyson's glands were supposed to located), in the last 6 months with no associated pain or discharge. The lesion was excised under local anesthesia. The specimen was sent for histopathological examination and was reported as "epidermal inclusion cyst". Penile epidermal cysts are extremely rare. In penile lesions a correct clinicopathological correlation is useful to arrive at a diagnosis to avoid unnecessary treatments and anxiety to the patients.

Keywords--Tyson's gland, smegma, epidermal inclusion cyst.

Introduction

In 1699, Tyson reported the presence of modified sebaceous glands along the balano preputial sulcus. Tyson noted macroscopic lesions on the corona of the penis, interpreting them as the source of smegma. Since then, efforts to confirm their existence in humans, with serial sectioning of penises removed for carcinoma, have been unsuccessful ^(1,2). Since Tyson had used the term "gland," microscopists who found ectopic sebaceous glands on the glans and prepuce referred to them as Tyson's glands, although they are not what Tyson described. Later authors described the same lesions under such terms as papillomatosis corona penis.

Case report

A 65-year-old male presented with the complaint of swelling in the prepuce in the past 6 months which was insidious in onset, initially small in size progressed to the present size. It was not associated with pain and not associated with discharge. General and systemic examinations were normal. On local examination, there was no phimosis. Prepuce was retracted to reveal a single globular swelling of 0.5 cm diameter on the left side of frenulum in the coronal sulcus. Surface of the swelling was smooth and skin over the swelling was shiny. There was no punctum or discharge. There was no local rise of temperature or tenderness or edema. The swelling was soft in consistency and had well defined margins. Fluctuation could not be elicited as the swelling was very small. Skin over the swelling was not pinchable. The inguinal lymph nodes were not enlarged. The lesion was excised under local anaesthesia. On the table, a point of discharge of whitish fluid in the coronal sulcus area was noted. An elliptical incision was made including the swelling and the discharging point. The swelling was excised completely. The wound was closed with 4-0 vicryl rapide. The specimen was sent for histopathological examination and was reported as keratin filled cyst lined by stratified squamous epithelium, suggestive of "epidermal inclusion cyst".

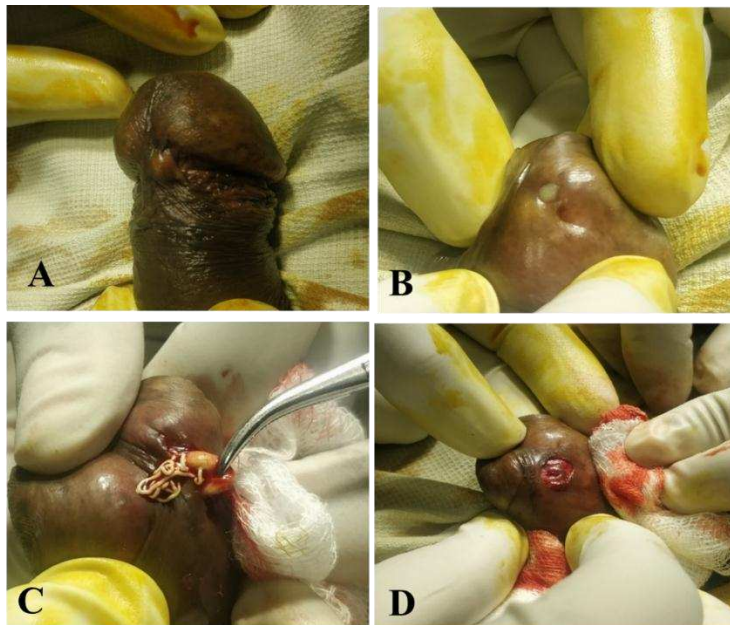


Figure 1. A - swelling of 0.5 cm near the frenulum on the coronal sulcus, B- Discharge point seen with whitish discharge, C- Cheesy material was expressed out from the incision site on applying pressure, D - Elliptical incision made including the swelling and discharging point.

Discussion

Tyson's glands were supposed to be modified sebaceous glands. They were said to be located on either side of frenulum of prepuce. They were first described by Edward Tyson in the 17th century as macroscopic structures on the corona of the penis, interpreting them as the source of smegma. Normal Tyson's glands might not be visible to naked eyes. They were considered to be vestigial in human beings⁽³⁾. Tysonitis, inflammation of Tyson's gland, though mentioned in literature as a complication of Gonorrhoea and nongonococcal genital infection, its occurrence is questionable.

The word 'smegma' is of Greek origin meaning Soap or lotion. Smegma is now known to be not a secretion of any particular gland. Smegma has characteristic slimy odour, composed of epithelial debris, desquamated cells, fat, and proteins⁽⁴⁾. Smegma is primarily collection of whitish debris in the subprepuceal space which collects if glans and coronal sulcus are not cleaned regularly⁽⁵⁾. It has a mixed bacterial flora with *Mycobacterium smegmatis* in 50% of cases. Other bacteria isolated are *Staphylococcus epidermidis*, *S. aureus*, *E. coli*⁽⁶⁾. Smegma itself is neither a damaging or irritating substance nor is it carcinogenic also⁽⁷⁾. Smegma collects when there are associated subprepuceal adhesions as in phimosis⁽⁸⁾. In the context of subprepuceal smegma collection two terminologies, i.e., Smegma Pearl and Preputial cyst need to be differentiated. Smegma Pearl is due to sub preputial collection of smegma between foreskin and glans while preputial cyst is one arising from the preputial skin⁽⁹⁾. Smegma protects and lubricates the glans

and inner lamella of the prepuce, facilitating erection, preputial eversion and penetration during sexual intercourse ⁽¹⁰⁾. Chemically, smegma contains compounds such as cathepsin B, lysozyme, chymotrypsin, neutrophil elastase-cytokines ⁽¹¹⁾, and hormones such as androsterone. Smegma also contains prostatic and seminal secretions, desquamated epithelial cells, and the mucin of the urethral glands of Littre⁽¹²⁾. Smegma can occur in females too. It may be the cause of vaginal odour. It can build up in the folds of the labia or around the clitoris. Similar to men, the easiest way to remove smegma from the female genitals is through proper personal hygiene. The existence and the role of Tyson's gland in secretion of smegma is thus disproved. Other differential diagnosis for Tyson's gland is epidermal cyst. Epidermal cyst is one of the common benign tumors which typically presents as nodule directly underneath the skin, and often with a visible central punctum. It is commonly called as sebaceous cyst, which is a misnomer as this cyst does not contain sebaceous material - instead has laminated layers of keratin reference.

Epidermal cysts are referred with various synonyms in literature including Wen, epidermoid cyst, epidermal inclusion cyst, infundibular cyst and keratin cyst. The most common sites are the face, scalp, neck, back and scrotum. They can also be found in the extremities, trunk or the back of the ears. Penile epidermal cysts are extremely rare ⁽¹³⁾ how rare. Its etiology can be of spontaneous origin or following trauma or surgery leading to epidermal elements being trapped within closed space. During wound healing, trapped squamous epithelium undergoes keratinisation and leads to cyst formation. Most cases present as painless swellings gradually increasing in size. Pain may be present only if they get inflamed or infected. If the cyst gets ruptured, the contents of the cyst spread to the surrounding subcutaneous tissues to cause inflammation. Discharge may occur through the punctum from time to time which may be foul smelling. Continuous long-term discharge can result in cutaneous horn which is a hard conical projection from the skin, made of compact keratin.

Histologically, the cyst is lined by stratified squamous epithelium. The cyst cavity is filled with laminated keratinous material. In a ruptured cyst, a keratin granuloma can be seen. Infected cysts show disruption of the cyst wall, acute inflammation or neutrophil infiltration or intense foreign body giant cell reaction. The diagnosis is purely clinical. Radiographic investigations are not necessary. FNAC should not be done for fear of infection, persistent discharge and complications. The definitive treatment is the complete surgical excision of the cyst with its wall intact. The main complication of surgery is recurrence due to incomplete excision. Other differential diagnosis are penile warts, molluscum contagiosum, epithelioid granuloma, lymphangioma circum scriptum, multiple syringomas, lichen planus, and bowenoid papulosis⁽¹⁴⁾.

Conclusion

In penile lesions a correct clinico-pathological correlation is useful to arrive at a diagnosis to avoid unnecessary treatments and anxiety to the patients. Surface microscopy improves the diagnosis of hyperplasia of the preputial sebaceous glands and is a useful method to differentiate from other surface lesions. Smegma is not formed by papillomatosis corona penis or ectopic sebaceous glands, but is

the result of desquamated epithelial cells of the glans and prepuce, maceration of epithelium and contamination with bacteria. For the sake of clarity and in order to avoid continued confusion, it is suggested that except for historical references, the term Tyson's glands be replaced by the appropriate descriptive expression, papillomatosis corona penis or ectopic sebaceous glands.

References

1. Rosai, J., 2004. Rosai and Ackerman's Surgical Pathology Vol1.
2. Barreto J, Caballero C, Cubilla A. Penis. In: Sternberg SS,ed. *Histology for Pathologists*. 2nd ed. Philadelphia, Pa: Lippincott-Raven; 1997:1039-1052.
3. Sankaranantham M. Tysonitis- due to a possible non-venereal infection. *MOJ Public Health*. 2018;7(6):323–324.
4. Parkash S, Jeyakumar S, Subramanyan K, Chaudhuri S. Human sub preputial collection: Its nature and formation. *J Urol* 1973;110:211-2.
5. Sali G, Ali I, Singh G, Rathod S. Smegma pearl. *Med J DY Patil Univ* 2014; 7:98-9
6. Anyanwu LJ, Kashibu E, Edwin CP, Mohammad AM. Microbiology of smegma in boys in Kano, Nigeria. *J Surg Res* 2012;173:21-5.
7. Van Howe RS, Hodges FM. The carcinogenicity of smegma: Debunking a myth. *J Eur Acad Dermatol Venereol* 2006;20:1046-54.
8. Prakash (sic, Parkash) S, Raghuram R, Venkatesan. Sub-preputial wetness- Its nature. *Ann Nat Med Sci (India)* 1982;18:109-12.
9. <http://www.mothing.com/community/t/764732/possible-seperation-issues-sore-red-irritated-ballooning-normal-development-etc>. [Last accessed on 2012 Dec 14]
10. NGUN, T., 2010. See also Definitive Penis Size Survey; Size; Steroids; Testosterone; Transgender/Transsexual. *Cultural Encyclopedia of the Penis*, 24(4), p.202.
11. Ahmed AA, Nordlind K, Schultzberg M *et al*. Immunohistochemical localization of IL-1 alpha-, IL-1 beta-, IL-6- and TNF-alpha-like immunoreactivities in human apocrine glands. *Arch Dermatol Res* 1995; 287: 764–766
12. Fleiss PM, Hodges FM, Van Howe RS. Immunological functions of the human prepuce. *Sexually transmitted infections*. October 1998;74(5):364–367. doi:10.1136/sti.74.5.364. PMID 10195034.
13. Jitendra Singh et al, *International journal of trichology*, Epidermal cysts: A Clinicopathological analysis with emphasis on unusual findings
14. Ena P, Origa D, Massarelli G. Sebaceous gland hyperplasia of the foreskin. *Clin Exp Dermatol* 2009 ;34:372-4.
15. Hyman AB, Brownstein MH. Tyson's "glands." Ectopic sebaceous glands and papillomatosis penis. *Arch Dermatol* 1969;99:31-6
16. Keith, A., and Shillitoe, A.: The Prepuccial or Odoriferous Glands of Man, *Lancet* 1:146-148 (Jan 16) 1904.
17. Goeckerman WH. Fordyce's condition of the penis. *Arch Derm Syph*. 1926; 14:50