

**How to Cite:**

Bali, V., Parimoo, R., & Singh, S. (2021). Classification of furcation involvement: A literature review. *International Journal of Health Sciences*, 5(S1), 428–440.  
<https://doi.org/10.53730/ijhs.v5nS1.5678>

# Classification of furcation involvement: A literature review

**Vikram Bali**

Professor & Head, Department of Periodontology, Desh Bhagat Dental College & Hospital, Mandi Gobindgarh

**Rajnesh Parimoo**

Senior Lecturer, Department of Periodontology, Desh Bhagat Dental College & Hospital, Mandi Gobindgarh

**Santokh Singh**

Junior Resident, Department of Periodontology, Desh Bhagat Dental College & Hospital, Mandi Gobindgarh

**Abstract**---Furcation lesions have been described by various classification systems. For many years, the most widely utilized classification system have been proposed by Glickman with no reference to the prognostic value of the lesion itself. This article reviews the old classification systems to classify furcation lesions on the basis of position of gingival margin and its relationship with the furcation area (exposed/non-exposed) for a better understanding of furcation involvements and increases the prognostic value of treatments in the long term.

**Keywords**---classification, furcation lesions, gingival recession, prognosis.

**Introduction**

Furcation is the anatomical area in multirouted teeth where the individual roots of multirouted tooth divides from the root trunk is called a bifurcation while in teeth with three roots it is called a trifurcation. The furcation is an area of complex anatomic morphology that may be difficult or impossible to debride by routine periodontal instrumentation. (Tal et al 1982). A furcation is defined as “the anatomical area of a multirouted tooth where the roots diverge” (American Academy of Periodontology 1992).<sup>1</sup>

Furcation involvement refers to a condition in which the bifurcations and trifurcations of multi-rooted teeth are invaded by periodontal disease, characterized by bone resorption and attachment loss in the interradicular space (Newmann et al, 2012). Glickman (1950) defined it as commonly occurring condition in which the bifurcation and trifurcation of multirouted teeth are denuded by periodontal disease. Bifurcation and trifurcation involvements are common periodontal lesions which occur as a result of gingival inflammation and bone resorption adjacent to and within the furca of multirouted teeth (Prichard et al 1965). According to Goldman & Cohen in 1968 furcation involvement is the extension of pocket into the interradicular area of bone in multirouted teeth. Furcation involvement is an indicator of the presence of advanced inflammatory plaque induced periodontitis and resultant bone loss in the area.

Currently, the proposed classifications are based on the extension of the defect and the degree of horizontal/vertical attachment loss. Glickman in 1953<sup>2</sup>, developed a classification system in order to describe the extension and main characteristics of the furcation defect (Grade I-IV). Hamp, Nyman and Lindhe<sup>3</sup> and Tarnow and Fletcher<sup>4</sup> proposed to measure the horizontal/vertical attachment loss, respectively. Moreover, other classifications have been proposed in an attempt to describe the anatomy of the furcation more completely, describing the number of remaining bony walls, the morphology of the existing bone and the relationship between root trunk and vertical/horizontal attachment loss.

Most of the classifications of furcation lesions are unable to convey all the relevant information related to the marginal tissue position and its relationship with the furcation involvement (clinically exposed/non-exposed furcation). This information could be important for diagnosis, prognosis and treatment planning as well as for the communication between clinicians and researchers. Furthermore, with a broad variety of cases with different clinical presentations, it is not always easy to classify all furcation defects according to classification systems in use to date. The surgical modalities for the furcation management includes: Open flap debridement alone in the furcation, open flap debridement in conjunction with bone grafts, and bone grafts with or without guided tissue regeneration<sup>5</sup>. The aim of the present article is to review different classifications of furcation involvement for a better understanding of furcation defects and to predict the prognosis by selecting the correct treatment for each case.

### **Classification of furcation involvement**

Several classifications have been proposed in an attempt to describe the anatomy of the furcation more completely, describing the morphology of the existing bone, the number of residual bone walls, the relationship between root trunk and horizontal or vertical attachment loss. It is important to appreciate that each furcation entrance must be examined and each entrance must be classified according to some criteria.

**1. Glickman** (1953) classified furcation involvement into four grades<sup>1,2</sup>

**Grade I:** A grade I furcation involvement is the incipient or early stage of furcation involvement. The pocket is supra-bony and primarily affects the soft tissues.

Early bone loss may have occurred with an increase in probing depth, but radiographic changes are not usually found.

**Grade II:** A grade II furcation can affect one or more of the furcation of the same tooth. The furcation lesion is essentially a cul-de-sac with a definite horizontal component. If multiple defects are present, they do not communicate with each other because a portion of the alveolar bone remains attached to the tooth. The extent of the horizontal probing of the furcation determines whether the defect is early or advanced. Vertical bone loss may be present and represents a therapeutic complication. Radiographs may or may not depict the furcation involvement, particularly with maxillary molars because of the radiographic overlap of the roots. In some views, however, the presence of furcation “arrows” indicates possible furcation involvement.

**Grade III:** In grade III furcation, the bone is not attached to the dome of the furcation. In early grade III involvement, the opening may be filled with soft tissue and may not be visible. The clinician may not even be able to pass a periodontal probe completely through the furcation because of interference with the bifurcational ridges or facial-lingual bony margins. However, if the clinician adds the buccal and lingual probing dimensions and obtains a cumulative probing measurement that is equal to or greater than the buccal-lingual dimension of the tooth at the furcation orifice, the clinician must conclude that a grade III furcation exists. Properly exposed and angled radiographs of early class III furcation display the defect as a radiolucent area in the crotch of the tooth.

**Grade IV:** In grade IV furcation, the interdental bone is destroyed, and the soft tissues have receded apically so that the furcation opening is clinically visible. A tunnel therefore exists between the roots of such an affected tooth. Thus, the periodontal probe passes readily from one aspect of the tooth to another.

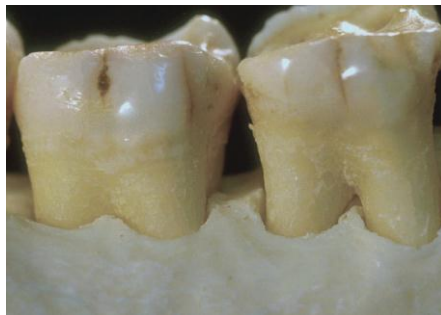

Figure 1 : Grade I furcation involvement (left) and Grade II furcation (right)

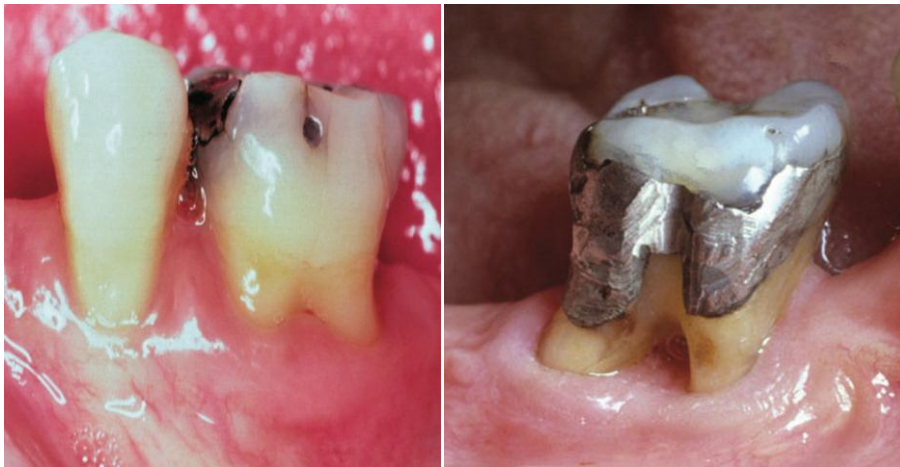


Figure 2 : Grade III (left) & IV furcations (right)

Goldman and Cohen (1958) have incorporated a descriptive classification of furcation invasion referring to grade I as incipient, grade II as cul-de-sac, and grade III as through-and-through<sup>3</sup>.

**Staffileno's classification** (1969) Based on surface location, number of bony walls, degree of furcation exposure, as follows<sup>4</sup>:

Class I: Furcations with a soft tissue lesion extending to furcal level but with minor degree of osseous destruction.

Class II: Furcations with a soft tissue lesion and variable degree of osseous destruction but not a through-and-through communication through the furca.

- Class II F: Furcations with osseous destruction from facial aspect only.
- Class II L: Furcations with osseous destruction from lingual aspect only.
- Class II M: Furcations with osseous destruction from mesial aspect only.
- Class II D: Furcations with osseous destruction from distal aspect only.

Class III: Furcations with osseous destruction that present with through and-through communication from buccal to lingual aspect or mesial to distal aspect<sup>5</sup>

**Easley and Drennan** (1969)

Class I: Incipient involvement, fluting coronal to furcation entrance is involved, no horizontal component.<sup>6</sup>

Class II: Divided further into Types 1 and 2

- Type 1: A definite horizontal loss of attachment into the furcation, but pattern of bone loss remains horizontal.
- Type 2: There is a buccal or lingual bony ledge and a definite vertical component to the furcation.

Class III: Through-and-through loss of attachment into the furcation and the pattern is horizontal in Type 1 and vertical in Type 2.

**Hamp et al** [1975]

Degree I: Horizontal loss of periodontal tissue support less than 3 mm.

Degree II: Horizontal loss of support 3 mm, but not encompassing the total width of the furcation.

Degree III: Horizontal through-and-through destruction of the periodontal tissue in the furcation.<sup>7</sup>

**Rosenberg, M.M.** (1978)

Horizontal Degree I. When the result of probing is not greater than 4 mm.

Degree II. When probing shows a value greater than 4 mm (i.e., the bifurcation lesion has already passed the center of the trifurcation).

Degree III. Two or three furcations classified as degree II are found.

Vertical Shallow: Slight lateral extension of an interradicular defect, from the center of the furcation in a horizontal direction, toward one or both adjacent furcations.

Deep: Internal furcation involvement denotes the greater lateral extension of the interradicular defect into but not penetrating the adjacent furcation<sup>8</sup>

**Ramfjord & Ash** (1979)

Class I: Beginning involvement. Tissue destruction, 2 mm (1/3 of tooth width) into the furcation.

Class II: Cul-de-sac. .2mm (.1/3 of tooth width), but not through-and-through.

Class III: Through-and-through involvement<sup>9</sup>

**Goldman and Cohen** (1980)

Degree I: Involves furcation entrance.

Degree II: Involvement extends under the roof of furcation but not through and-through.

Degree III: Through-and-through involvement<sup>10</sup>

**Ricchetti** (1982)

Class I: 1 mm of horizontal measurement; the root furrow.

Class Ia: 1–2 mm of horizontal invasion; earliest damage.

Class II: 2–4 mm of horizontal invasion.

Class IIa: 4–6 mm of horizontal invasion. Class III: 6 mm of horizontal invasion<sup>11</sup>

**Tal and Lemmer** (1982) The degree of severity of the furcation defects affecting each molar is assigned to one of four groups designated 1, 2, 3 and 4, referred to as furcation involvement index (FII) scores.

Furcal rating 1: Depth of the furcation is 0 mm.

Furcal rating 2: Depth of the furcation is 1 to 2 mm.

Furcal rating 3: Depth of the furcation is 3 mm.

Furcal rating 4: Depth of the furcation is 4 mm or more<sup>12</sup>

**Tarnow & Fletcher** (1984)

Vertical components

A: Vertical destruction upto 1/3<sup>rd</sup> of total inter-radicular height: (2-3 mm)

B: Vertical destruction reaching 2/3<sup>rd</sup> of the inter-radicular height (4-6 mm)

C: Inter-radicular bone destruction into or beyond apical third (> 7 mm)

Therefore, furcations will be classified as with horizontal and vertical components as:

IA, IB, IC  
 IIA, IIB, IIC  
 IIIA, IIIB, IIIC <sup>13</sup>

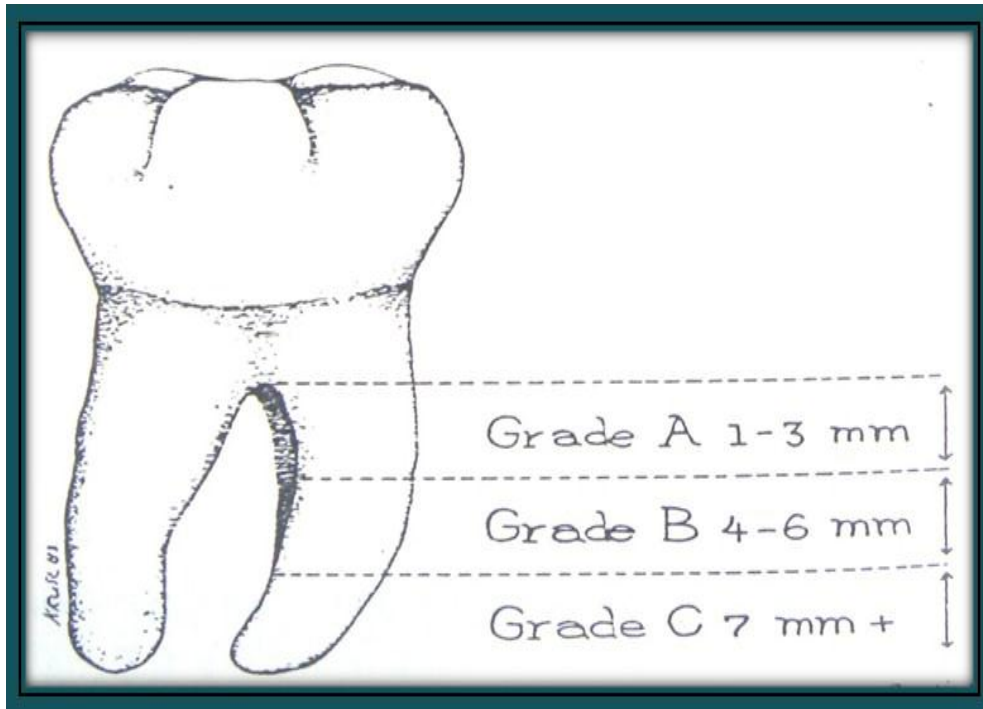


Figure 5: Tarnow & Fletcher

**Eskow and Kapin (1984)**

Furcation involvement is classified as grade I subclasses A, B, and C (vertical involvement) <sup>14</sup>

Subclass A: Vertical destruction  $> 1/3$ .

Subclass B: Vertical destruction of  $2/3$ .

Subclass C: Vertical destruction beyond the apical third of interradicular height.

**Fedi (1985)** combined the Glickman and Hamp classifications <sup>15</sup>

Grades are same as Glickman classifications (I-IV).

Grade II is sub-divided into degrees I & II.

Degree I: Vertical bone loss 1-3mm.

Degree II: Vertical bone loss greater than 3mm, but not communicate through and through.

**Grant et al. (1988)**

Class I: Involvement of the flute only.

Class II: Involvement partially under the roof or dome.

Class III: Through-and-through loss of furcation bone and attachment <sup>16</sup>

**Basaraba (1990)**

Class I: Initial/incipient furcation involvement.

Class II: Partial/patent furcation involvement.

Class III: Patent furcation involvement that communicates with 2nd or 3rd furcation opening; ie. communicating furcation involvement <sup>17</sup>

**Carnevale et al. (1997)** Modified Hamp et al. (1975) classification wherein the horizontal depth of furcation involvement is expressed in terms of 3 mm instead of thirds <sup>18</sup>

**Nevins and Capetta (1998)**

Class I: Incipient or early loss of attachment.

Class II: A deeper invasion and loss of attachment that does not extend to a complete invasion.

Class III: Complete loss of periodontium extending from buccal surface to lingual surface. Diagnosed radiographically and clinically.<sup>19</sup>

**Hou et al. (1998)** Classification based on root trunk length and horizontal and vertical bone loss [7]. Types of root trunk:

Type A: Furcation involving cervical third of root length.

Type B: Furcation involving cervical third and cervical two-thirds of root length.

Type C: Furcation involving cervical two thirds of root length.

Classes of furcation:

Class I: Horizontal loss of 3 mm.

Class II: Horizontal loss > 3 mm.

Class III: Horizontal –through-and-through loss.

Subclasses by radiographic assessment of the periapical view:

Sub-class 'a' Supra-bony defect.

Sub-class 'b' Infra-bony defect.

Classification of furcation:

AI, AII, AIII. Type A root trunks with class I, class II and class III furcations.

BI, BII, BIII. Type B root trunks with class I, class II and class III furcations.

CI, CII, CIII. Type C root trunks with class I, class II and class III furcations.<sup>20</sup>

**Fedi et al. (2000)** Modified Glickman's classification: Grade II degree I - exists when furcal bone loss possesses a vertical component of >1 but 3mm, but still does not communicate through-and-through.<sup>15</sup>

**Glossary of periodontal terms (2001)**

Class I: Minimal but notable bone loss in furcation.

Class II: Variable degree of bone destruction but not extending completely through furcation.

Class III: Bone resorption extending completely through furcation <sup>1</sup>.

**Walter, C. et al. (2009)** Modification of the Hamp et al. classification.

Degree I: Horizontal attachment loss < 1/3 of the width of the tooth. Degree II: Horizontal loss of support > 3 mm, < 6 mm.

Degree II–III: Horizontal loss of support > 6 mm, but not extending completely through furcation.

Degree III: Horizontal through-and-through destruction <sup>2</sup>

**Carnevale, G. et al. (2012)**

Degree I: Horizontal attachment loss  $< 1/3$

Degree II: Horizontal attachment loss  $> 1/3$

Degree III: Horizontal through-and-through destruction <sup>24</sup>

**Pilloni A, Rojas, M.A. (2018)**

NE – non exposed; E – exposed.

NEI: The furcation lesion is not clinically exposed. The horizontal attachment loss is 2 mm or less.

NEII: The furcation lesion is not clinically exposed. The horizontal attachment loss is 3 mm or more.

NEIII: The furcation lesion is not clinically exposed. The horizontal attachment loss is total, with through and through opening of the furcation.

EI: The furcation lesion is clinically exposed. The horizontal attachment loss is 2 mm or less.

EII: The furcation lesion is clinically exposed. The horizontal attachment loss is 3 mm or more.

EIII: The furcation lesion is clinically exposed. The horizontal attachment loss is total, with through and through opening of the furcation.<sup>25</sup>

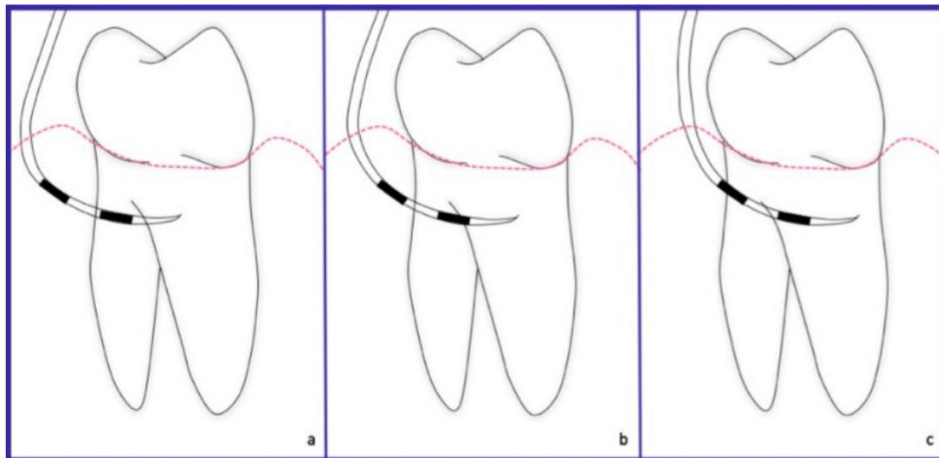


Figure 6 : Non-exposed furcation lesion (NE): (a) Class I: Incipient lesion. Horizontal attachment loss of 2 mm or less; (b) Class II: Horizontal attachment loss 3 mm or more; (c) Class III: Total horizontal attachment loss (through and through)



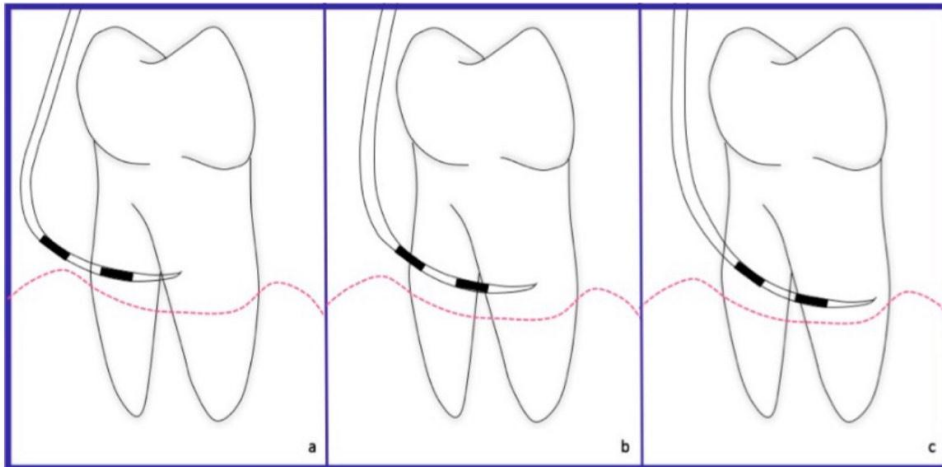


Figure 7 : Exposed furcation lesion (E): (a) Class I: Incipient lesion. Horizontal attachment loss of 2 mm or less; (b) Class II: Horizontal attachment loss of 3 mm or more; (c) Class III: Total horizontal attachment loss (through and through).

**Kolte, A.P. et al. (2018)**

Grade I - This type of furcation involvement is an inchoate lesion which develops by mild to moderate and uniform periodontal destruction extending into the flute of the furcation, and manifesting itself with increased probing depth.

Grade Ia: It comprises of all the features of Grade I FI, with the normal position of gingival margin which is slightly coronal to the CEJ.

Grade Ib: It comprises of all features of Grade I FI, with the position of gingival margin, 0-3 mm apical to CEJ.

Grade Ic: It comprises of all features of Grade I FI, with the position of gingival margin which is more than 3 mm apical to CEJ and may lead to mucogingival problem.

Grade II: This type of FI is a confined lesion which develops by moderate periodontal destruction of varying amount extending into the inter-radicular area, with an arched roof created by the furca and bordered by roots and bone.

Grade II type1a- It comprises of all the features of Grade II Type 1 FI with the normal position of gingival margin which is slightly coronal to the CEJ.

Grade II type1b - It comprises of all the features of Grade II Type 1 FI with the position of gingival margin which is 0-3 mm apical to the CEJ.

Grade II type1c- It comprises of all the features of Grade II Type 1 FI with the position of gingival margin which is more than 3 mm apical to the CEJ and may lead to mucogingival problem.

Grade II type2a- It comprises of all the features of Grade II Type 2 FI with the normal position of gingival margin which is slightly coronal to the CEJ.

Grade II type2b- It comprises of all the features of Grade II Type 2 FI with the position of gingival margin which is 0-3 mm apical to the CEJ.

Grade II type2c- It comprises of all the features of Grade II Type 2 FI with the position of gingival margin which is more than 3 mm apical to the CEJ and may lead to mucogingival problem.

Grade III – This type of FI is a complete lesion which develops by moderate to severe periodontal destruction in the furcation area permitting the passage of a probe bucco-lingually on the mandibular molars and bucco-mesially and bucco-distally on the maxillary molars.

Grade III type1a– It comprises of all the features of Grade III Type 1 FI with the normal position of gingival margin which is slightly coronal to the CEJ.

Grade III type1b– It comprises of all the features of Grade III Type 1 FI with the position of gingival margin which is 0-3 mm apical to the CEJ.

Grade III type1c– It comprises of all the features of Grade III Type 1 FI with the position of gingival margin which is more than 3 mm apical to the CEJ and may lead to mucogingival problem.

Grade III type 2a– It comprises of all the features of Grade III Type 2 FI with the normal position of gingival margin which is slightly coronal to the CEJ.

Grade III type 2b– It comprises of all the features of Grade III Type 2 FI with the position of gingival margin which is 0-3 mm apical to the CEJ.

Grade III type 2c– It comprises of all the features of Grade III type 2 FI with the position of gingival margin which is more than 3 mm apical to the CEJ and may lead to mucogingival problem.<sup>26</sup>

### **Limitations**

Although Glickman's classification<sup>2</sup> has been extensively used, there are limitations that need be considered:

1. As the reference point for the classification is the horizontal attachment loss, the absence of the precise numerical values to identify the horizontal attachment loss create difficulties in the classification between grade I and II.
2. In Glickman's grade III and IV furcation lesion the inter-radicular bone is completely absent, with the difference that in grade IV the furcation entrance is exposed. In this case, grade III and IV would represent a single group considering that the reference point of this classification is the horizontal attachment loss and it is the same for both groups. The difference between them could be represented by creating two subgroups.
3. In grade I and II furcation lesions the relationship with gingival margin (clinical exposition of the furcation) is not considered. In such cases, a furcation lesion with incipient bone loss (Glickman's grade I) but clinically exposed for the presence of gingival recession cannot be classified as grade I but neither as grade IV. The same problem arises for Glickman's grade II.

The classification systems that quantify the horizontal/vertical attachment loss [Hamp, Tarnow, Ramjford, Carnivale] also present limitations that should be considered:

1. The classification systems quantifying the horizontal attachment loss give rise to the same problem: in none of them one can clearly differentiate between grade I and II since both use the same reference point (less or greater than one third—less or greater than two or three millimeters)<sup>3,11</sup>, which means that it is not clear in which group furcation involvements with measures of one 1/3 or 2–3mm will be included.

2. When the furcation lesion is partially or not clinically exposed it is difficult to measure the vertical bone loss<sup>4,7</sup>. In these cases, a routine radiographic image could help only in cases where the inter-radicular bone loss is completely absent (grade III Glickman), and this will be in turn more precise in lower molars, because the overlapping of structures in upper molars makes diagnosis difficult.

## **Discussion**

Furcation is an area of a tooth that has a complex anatomy and morphology and it may be difficult to debride by means of routine periodontal instrumentation. Treatment of a multi-rooted tooth has been a challenge. The most important factors influencing the decision for the treatment of a furcation depend on tooth type and degree of furcation involvement. Hence, diagnosis and its correct interpretation are essential when establishing an adequate treatment.<sup>27</sup>

The proposed classification by Kolte et al. (2018) is one of the first attempts to develop a system that relates the extent of alveolar bone damage horizontally as well as vertically in the furcation and gingival positions. This classification system is probably the only one which takes into account the hard and soft tissue conditions around molars in periodontal diseases and can provide meaningful guidelines into advising a complete therapeutic correction of the defects.<sup>26</sup>

Furcation lesions are classified into two main groups: by exposure and non-exposure, according to Pilloni A., Rojas, M.A., (2018) classification. When a molar presents a long root trunk and gingival recession, the furcation lesion may not be visible. It will be listed as a non-exposed group for this reason. The main criteria for this method of diagnosis are more the exposure of the furcation defect than the occurrence of gingival recession. It is important to use two periodontal probes to avoid errors in the diagnosis of nonexposed lesions. If the probes get in touch the diagnosis of a class III furcation defect will be confirmed.

## **Conclusion**

The skill and dexterity of the clinician is definitely put to test while treating teeth with furcation involvement. Longevity of the tooth involved, depends on the degree of furcation involvement, the anatomy of the tooth, its position in the arch as well as on regular supportive care in addition to diligent oral hygiene maintenance by the patient.

The keys to successful treatment of furcation involvement are early diagnosis, thorough treatment planning, good oral hygiene by the patient, careful technical execution of the therapeutic modality and a well designed and implemented program of periodontal maintenance. This review study attempts to refine the existing drawbacks of current classifications so that the new system can be applied to a wider variety of cases to provide more accurate characterization of the lesions. This would be of significant aid in communication between clinicians and researchers providing a better understanding of furcation involvements and could be important to predict the prognosis and select correct treatment for each case.

## References

1. American Academy of Periodontology 1992
2. Glickman I. *Clinical Periodontology: Prevention, Diagnosis, and Treatment of Periodontal Disease in the Practice of General Dentistry*, 4th ed.; 1972; pp. 242–245. ISBN 0721641377.
3. Goldman HM. Therapy of the incipient bifurcation involvement. *J Periodontol*. 1958, 29:112–116.
4. Staffileno HJ. Surgical management of furca invasión. *Dent Clin N Am* 1969Jan, 13(1): 103–119.
5. Rajneesh Parimoo et al (2020); Clinical Evaluation of Mineral Trioxide Aggregate in the Surgical Management of Degree I and Degree II Furcation Defects, *Scientific Dental Journal*, Volume 4-Issue 3,September-December 2020;Page 79-84
6. Easley JR.; Drennan GA. Morphological classification of the furcation. *J Can Dent Assoc (Tor)* 1969 Feb, 35(2): 104–107.
7. Hamp, S. E., Nyman, S. & Lindhe, J. (1975) Periodontal treatment of multirooted teeth. Results after 5 years. *Journal of Clinical Periodontology* 2, 126–135.
8. Rosenberg MM. Management of osseous defects, furcation involvements, and periodontal-pulpal lesions. In *Clinical Dentistry, Periodontal and Oral Surgery*; Philadelphia, PA, USA, 1986.
9. Ramfjord SP, Ash MM. *Periodontology and Periodontics*; Saunders: Philadelphia, PA, USA, 1979; pp. 247–309. ISBN 13-978-0721674605.
10. Goldman HM, Cohen DW. *Periodontal Therapy*, 6th ed.; C. V. Mosby: St. Louis, IL, USA, 1988; p. 921. ISBN 13-9780801618741.
11. Richetti PA. A furcation classification based upon pulp-chamber relationships and vertical radiographic bone loss. *Int J Periodontics Restorative Dent*. 1982, 2(5): 50-9.
12. Tal H, Lemmer J. Furcal defects in dry mandibles. Part II: Severity of furcal defects. *J Periodontol* 1982 Jun, 53(6):364-7.
13. Tarnow D, Fletcher P. Classification of the vertical component of furcation involvement. *J Periodontol* 1984 May, 55(5): 283-4.
14. Eskow RN, Kapin SH. Furcation invasions: correlating a classification system with therapeutic considerations. Part I. Examination, diagnosis, and classification. *Compend Contin Educ Dent* 1984 Jun, 5(6): 477–487.
15. Fedi PF Jr. *The Periodontal Syllabus*, 2nd ed.; Lea and Febiger: Philadelphia, PA, USA, 1985; pp. 169–170. ISBN 13-978-0781779722.
16. Grant DA, Stern IB.; Listgarten MA. *Periodontics*, 6th ed.; C. V. Mosby: St. Louis, IL, USA, 1988; p. 931.
17. Basaraba N. Furcation invasions. In *Periodontal Diseases*; Schluger S, Yuodelis R, Page RC, Johnson RH, Eds.; Lea and Febiger: Philadelphia, PA, USA, 1990; ISBN 13-978-0812110845.
18. Carnevale G, Pontoriero R, Lindhe J. Treatment of furcation—involved teeth. In *Clinical Periodontology and Implant Dentistry*, 5th ed.; Lindhe J, Lang NP, Karring T, Eds.; Munksgaard: Copenhagen, Denmark, 2012; vol. 2, pp. 823–847. ISBN 978-1-118-35561-9.
19. Nevins M, Cappetta EG. Treatment of maxillary furcations. In *Periodontal Therapy-Clinical Approaches and Evidence of Success*;

- Nevins M, Mellonig JT, Eds.; Quintessence: Chicago, IL, USA, 1998;ISBN 13-978-0867153095.
20. Hou GL, Chen YM, Tsai CC, Weisgold AS. A new classification of molar furcation involvement based on the root trunk and horizontal and vertical bone loss. *Int J Periodontics Restor Dent* 1998 Jun, 18(3): 257–65.
  21. Vandersall DC: Concise Encyclopedia of Periodontology Blackwell Munksgaard 2007.
  22. American Academy of Periodontology. Glossary of Periodontal Terms, 4th ed.; Chicago, LA, USA, 2001; Available online: <https://members.perio.org/libraries/glossary>.
  23. Walter C, Kaner D, Berndt DC, Weiger R, Zitzmann NU. Three-dimensional imaging as a pre-operative tool in decision making for furcation surgery. *J Clin Periodontol* 2009 Mar, 36(3): 250–7.
  24. Carnevale G, Pontoriero R, Lindhe J. Treatment of furcation—involved teeth. In *Clinical Periodontology and Implant Dentistry*, 5th ed.; Lindhe J, Lang NP, Karring T, Eds.; Munksgaard: Copenhagen, Denmark, 2012; vol. 2, pp. 823–847. ISBN 978-1-118- 35561-9
  25. Piloni A, Rojas MA. Furcation Involvement Classification: A Comprehensive Review and a New System Proposal. *DentJ (Basel)* 2018 Sep, 6(3): 34.
  26. Kolte AP, Pajnigara NG et al. Comprehensive Classification System for Furcation Involvement – Incorporating Additional Variables, *J Clin Diag Res* 2018 Aug, 12(8): ZE01-ZE04, page 1-3.
  27. Van Swol RL, Eslami A, Sadeghi EM, Ellinger RF. New treatment for furcation defects involving strategic molars. *Int J Periodontics Restorative Dent* 1989;9:185-95.