

**How to Cite:**

Kaur, U., Arora, A., & Malhan, S. (2021). Retreatment endodontics: A review. *International Journal of Health Sciences*, 5(S1), 149–163. <https://doi.org/10.53730/ijhs.v5nS1.5410>

## Retreatment endodontics: A review

**Upneet Kaur**

Pg student (Final Year), Department of Conservative Dentistry and Endodontics, Desh Bhagat Dental College and Hospital, Mandi Gobindgarh  
Email: [upneet0011@yahoo.com](mailto:upneet0011@yahoo.com)

**Arvind Arora**

HOD, Department of Conservative Dentistry and Endodontics, Desh Bhagat Dental College and Hospital, Mandi Gobindgarh

**Sunil Malhan**

Professor, Department of Conservative Dentistry and Endodontics, Desh Bhagat Dental College and Hospital, Mandi Gobindgarh

**Abstract**---Endodontic retraction is a procedure performed on a tooth that received an earlier attempt at a definitive treatment that resulted in a condition requiring additional new endodontic treatment to achieve a successful outcome. The main cause of treatment failure is insufficient cleaning and inadequate obturation. The objective of this article is to evaluate, through a literature review, the endodontic retreatments with rotary and mechanical files, which is the best efficacy. Experimental and clinical studies were included (case reports, retrospective, prospective and randomized trials) with qualitative and quantitative analysis. The words were included “Endodontic Retreatments” and “Endodontic Treatments”. The conclusion of this article was that with recent technological advances in the area of endodontics, behind the literary reviews we can affirm that the system of instrumentation of the root canals with rotating files maintains the quality of the root preparation.

**Keywords**---endodontic Retreatments, rotary instrumentation, tooth.

**Introduction**

The increased awareness of the patients to preserve their teeth has lead to a growing interest in endodontic treatment in the recent times.<sup>1</sup> The major goals of root canal treatment is to clean and shape the root canal system and seal it in three dimensions to prevent reinfection of the tooth.<sup>2</sup> Root canal treatment fails when it falls short of acceptable standards. When a decision is made to preserve

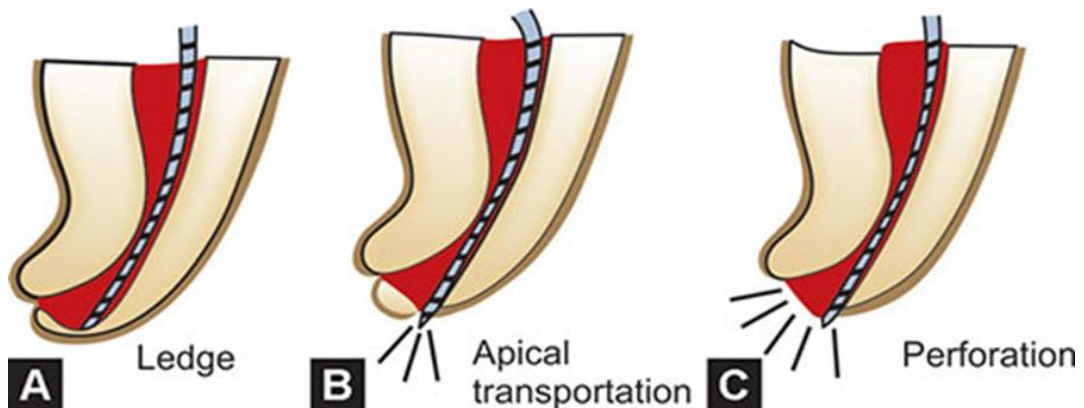
the previously treated tooth, the clinician must decide whether a surgical, non-surgical or combined approach is most appropriate.<sup>3</sup>

### Causes of endodontic treatment failure

1. **Intraradicular infection**
  - a. Persistent microorganisms
  - b. Procedural errors-
    1. Missed canals
    2. Ledges
    3. Apical transportation
    4. Poor obturation
    5. Poor irrigation and debridement
2. **Extraradicular infection**
  - a. Actinomycosis
  - b. Other extraradicular microbes
  - c. Non-microbial causes

### Procedural Errors

**Missed Canals:** The cause of endodontic failure are multifactorial, but a statistically significant percentage of failures are related to missed root canal systems. Missed canals hold tissue and, at times, bacteria and related irritants that inevitably contribute to clinical symptoms and lesions of endodontic origin.<sup>4</sup> Common teeth with additional canals are maxillary central incisors, maxillary first molar, maxillary 2 molar and C shaped molars.



**Ledges:** It is an artificially created irregularity on the surface of the root canal wall that prevents the placement of instrument to the apex of an otherwise patent canal. Ledges result when clinician's work short of working length.<sup>5</sup>

**Apical transportation:** Apical canal transportation is movement of the position of canals normal anatomic foramen to a new location on external root surface. These canals are under filled and bacteria persist in these canals.<sup>5</sup>

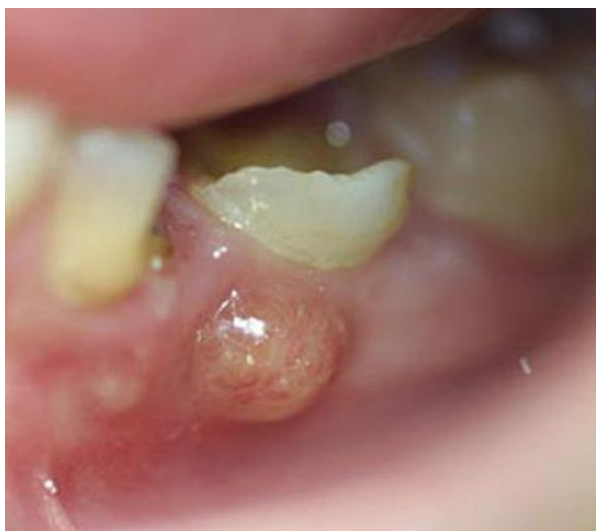**Perforations:** It is defined as mechanical or pathological communication between the root canal system and external tooth surface. It can be caused iatrogenically or due to caries. Iatrogenic perforations often are due to a loss of attention to the details of the internal anatomy of the root canal system and a failure to consider anatomical variations. Perforations also can be caused by an inability to maintain canal curvature because of ledge formation. The introduction of Mineral Trioxide Aggregate (MTA) has improved the outcome of perforation repair.<sup>5</sup>

**Poor obturation :** It leads to ingress of bacteria by coronal leakage or the persistence of bacterial colonies bathed in nutrients from tissue fluid. Sjogren U et al. also demonstrated that slight overfilling appeared to have no influence on the treatment outcome, even in teeth with apical periodontitis.<sup>6</sup> It has been claimed that the success rate of root canal treatment is decreased in cases of over-filling. Over instrumentation often precedes over-filling and in teeth with infected necrotic pulps this causes displacement of infected dentine or debris into the periradicular tissues.<sup>5</sup>

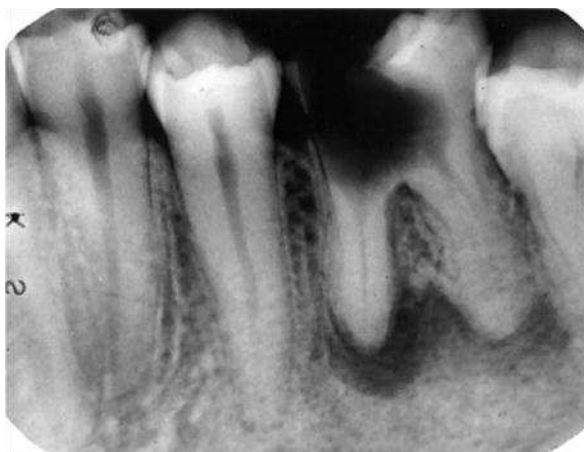### **Extraradicular infection**

Extraradicular infection can occur in the apical area of the tooth in the form of:

**Periapical abscess:** It is a focus of acute inflammation characterized by the presence of distinct collection of polymorphonuclear leukocytes within an already existing chronic granuloma. Depending on the presence or absence of epithelial strands, these lesions were further divided into epithelialized and non-epithelialized abscesses.<sup>6</sup>



**Periapical granuloma:** It is chronic inflammation that consists of a granulomatous tissue that is predominantly infiltrated with lymphocytes, plasma cells and macrophages. These lesions may be epithelialized or non epithelialized.<sup>6</sup>



### **Actinomycosis**

According to McGhee JR, Michalek SM, Cassel GH in 1982 it is a chronic, granulomatous infectious disease in humans and animals caused by the genera *Propionibacterium*.<sup>7</sup> Actinomycosis is clinically divided into cervicofacial, thoracic and abdominal forms. Periapical actinomycosis is a cervicofacial form of actinomycosis. Actinomycosis israeli is a commensal of the oral cavity and can be isolated from tonsils, dental plaque, periodontal pockets and carious lesions.<sup>7</sup>

### **Other Extraradicular Microbes**

Apical periodontitis has long been considered to be a dynamic defence enclosure against unrestrained invasion of microorganisms into peri radicular tissues. It is, therefore, conceivable that microorganisms generally invade extra radicular tissues during expanding and exacerbating phases of the disease process. Extra radicular infections are the cause of many failed endodontic treatments and such cases would not be amenable to a non-surgical approach and require apical surgery or systemic medications.<sup>7</sup>

### **Non-Microbial Causes**

#### **Cystic apical periodontitis**

A cyst has been defined as a pathological cavity containing fluid, semi fluid or gas which is usually lined by epithelium and is not formed by the accumulation of pus. The cyst occurring due to failed endodontic treatment can be of two types:

**Apical pocket cyst:** in this type of cyst the epithelium lined sac is in communication with the root canal system.

**Apical true cyst:** in this type of cyst the lesion is completely enclosed by epithelial lining and has no communication with root canal.<sup>7</sup>

### **Cholesterol crystals**

Although the presence of cholesterol crystals in apical periodontitis lesions has long been observed to be a common histopathological feature, its aetiological significance to failed root canal treatments has not yet been fully appreciated. Cholesterol is a steroid lipid that is present in abundance in all 'membrane-rich' animal cells. Excess blood level of cholesterol is suspected to play a role in atherosclerosis as a result of its deposition in the vascular walls. Accumulation of cholesterol crystals occurs in apical periodontitis lesions with clinical significance in endodontics. Cholesterol crystals are intensely sclerogenic.<sup>7</sup>

### **Foreign bodies**

Foreign materials trapped in periapical tissue during and after endodontic treatment can perpetuate apical periodontitis persisting after root canal treatment. Materials used in non-surgical root canal treatment and certain food particles can reach the periapex, induce a foreign body reaction that appears radiolucent and remain asymptomatic for several years.<sup>7</sup>

### **Gutta-percha**

The most frequently used root canal filling material is gutta-percha in the form of cones. The widely held view that it is biocompatible and well tolerated by human tissues is inconsistent with the clinical observation that extruded gutta-percha is associated with delayed healing of the periapex.<sup>7</sup>

### **Other Plant Materials**

Vegetable food particles, particularly leguminous seeds (pulses), and materials of plant origin that are used in endodontics can get lodged in the periapical tissue before and/or during the treatment procedures and prevent healing of the lesion.

**Periapical pulse granuloma:** These types of granulomas are associated with teeth damaged by caries and with the antecedence of endodontic treatment. Pulse granuloma are characterized by the presence of intensely iodine and PAS positive hyaline rings or bodies surrounded by giant cells and inflammatory cells. Leguminous seeds are the most frequently involved vegetable food material in such granulomatous lesions.<sup>7</sup>

**Cellulose granuloma:** apical periodontitis developing against particles of predominantly cellulose-containing materials that are used in endodontic practice has been denoted as cellulose granuloma. Endodontic paper points are utilized for microbial sampling and drying of root canals. Sterile and medicated cotton wool has been used as an apical seal. Particles of these materials can dislodge or get pushed into the periapical tissue so as to induce a foreign body reaction at the periapex.<sup>7</sup>

### **Other Foreign Materials**

They include amalgam, endodontic sealants and calcium salts derived from periapically extruded  $\text{Ca(OH)}_2$ .

### **Scar Tissue Healing**

There is evidence that unresolved periapical radiolucency's may occasionally be due to healing of the lesion by scar tissue that may be misdiagnosed as a radiographic sign of failed endodontic treatment. The pattern of healing depends on several factors, two of which are decisive. They are the regeneration potential and the speed with which the tissue cells bordering the defect react.<sup>7</sup>

### **Decision Making And Treatment Planning**

Factors contributing to differences in decision-making processes amongst groups of clinicians include the dentist, the patient, cost, environmental resources, clinical experience, training and speciality. Ultimately the decision whether to retreat or not is made between a clinician and the patient following presentation of all the factors on both sides. If root canal treatment has failed, there are usually five possible treatment options:

#### **Review or do Nothing**

There may be occasions where a conservative approach is appropriate . One of the most difficult decisions is whether to retreat a root-filled tooth that requires a crown when it shows no evidence of a defective core or periapical disease and is symptom-free but has a technically deficient root canal filling.<sup>8</sup>

Review may be considered when:

- The tooth is symptom-free.
- There are no signs of inflammation or infection.
- Root canal treatment has only recently been completed and the outcome is uncertain.

#### **Root Canal Retreatment**

Root canal retreatment is often the preferred means of treating a failed root canal procedure, especially when the failure is due to a technical deficiency. The existing root filling is removed and the infected root canal disinfected using irrigants and medicaments.

Root canal retreatment is normally indicated when:

- Conventional root canal treatment has failed.
- There are signs of inflammation or infection associated with a root-filled tooth.
- There are persistent symptoms from a root filled tooth, or the presence of a sinus tract, swelling or pain.
- A root-filled tooth has failed for technical reasons.
- There is systemic risk if no intervention is made.
- The tooth is restorable.
- The existing root filling is technically deficient and a new restoration is required.<sup>8</sup>

## **Root End Surgery**

Root end surgery may be considered when:

- It is impractical to carry out conventional root canal retreatment
- Root canal treatment or non-surgical retreatment has been unsuccessful
- As an adjunct to root canal retreatment, perhaps in perforation repair or to remove extruded material.
- When root or tooth resection is required.
- When a biopsy is required.<sup>8</sup>

## **Extraction**

If a tooth is unrestorable or the prognosis for root canal retreatment is poor, extraction is the only option. Extraction may be the treatment of choice:

- When the tooth or root is fractured and is not saveable.
- If an alternative, such as removable or fixed bridgework or an implant-based solution, would offer a better prognosis.
- When the patient elects not to have retreatment when all options have been explained.<sup>8</sup>

## **Referral**

There are specialist practitioners who have additional expertise in the retreatment of endodontic failures. Referral may be appropriate when:

- The clinician is unable to make a diagnosis.
- Access is limited.
- Root canal treatment has failed.
- Retreatment has failed.
- Complexity of treatment is greater than the clinician's expertise.
- Surgical endodontic treatment is required.<sup>8</sup>

## **Goals Of Nonsurgical Endodontic Retreatment**

Endodontic failures must be evaluated so that a decision can be made between nonsurgical retreatment, surgical retreatment, or extraction. The goals of non surgical retreatment are to remove materials from the root canal space and if present, address deficiencies or repair defects that are pathologic or iatrogenic in origin <sup>9</sup>

## **Coronal Access**

Clinicians typically access the pulp chamber through an existing restoration if it is judged to be functionally designed, well fitting and aesthetically pleasing. If the restoration is deemed inadequate and/or additional access is required, then it should be sacrificed. <sup>9</sup>

## Sectioning

If a crown is to be replaced, it can simply be removed by sectioning with a bur and the separate pieces elevated. Metal restorations can easily be cut using a tungsten carbide fissure bur. The crown is partially sectioned by cutting a groove from the gingival to the occlusal surface and then a crown remover, flat plastic or Coupland's chisel can be used to open up the groove and flex the restoration, breaking the cement lute.<sup>9</sup>

## Chisel And Mallet

A straight chisel and mallet can be used to tap off the crown. However, there are obvious risks involved in this method and it is perhaps not that pleasant for the patient.<sup>9</sup>

## Forceps

Special forceps for crown removal are available with rubber cups on the beaks. <sup>9</sup>

## Coronal Disassembly Devices

There are many tools available for coronal disassembly and they have been arbitrarily divided into three categories:

**Grasping instruments:** In general, this class of hand instruments works by applying inward pressure on two opposing handles.

**Percussive instruments:** This method of prosthetic disassembly involves using a selected and controlled percussive removal force.

**Active instruments:** The instruments in this category actively engage a restorative, enabling a specific dislodgement force to potentially lift off the prosthesis. These devices require a small occlusal window to be cut through the restorative to facilitate the mechanical action of the instrument. <sup>9</sup>

## Crown Removers

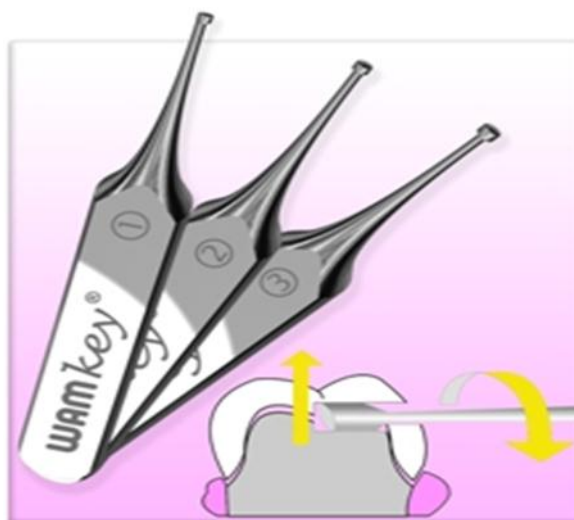These instruments are used to remove the restorations safely without damaging the underlying gingiva.

**The Richwell Crown and Bridge Remover:** this is essentially a tablet of water-soluble pliable resin which is softened in hot water and placed on the restoration that needs to be removed <sup>9</sup>. The patient is asked to bite down and compress the resin block to about two-thirds of its original thickness. When the resin is set, the patient is asked to open quickly, which will generate sufficient force to loosen and lift the restoration. This technique tends not to be particularly effective.<sup>9</sup>

## The Wamkey

It looks rather like a small key and can be effective for crown and bridge removal.  
<sup>9</sup>





### **Ultrasonics**

Ultrasonics is sometimes useful to loosen the cement from around the margins of a poorly fitted crown. This could be a simple ultrasonic tip vibrated at high power with a water spray or a specialist tip such as CT4.<sup>9</sup>

### **Removal of Obturation Materials**

There are four commonly encountered obturation materials found in root canals. These materials are gutta-percha, carrier-based obturators, silver points and paste fillers.<sup>9</sup>

#### **Gutta-Percha Removal**

Regardless of technique, gutta percha is best removed from a root canal in a progressive manner to prevent inadvertent displacement of irritants periapically. Dividing the roots into thirds, gutta-percha may be initially removed from the canal in the coronal one-third, then the middle one-third, and finally eliminated from the apical one-third. The removal techniques include rotary files, ultrasonic instruments, heat, hand files with heat or chemicals, and paper points with chemicals. Chemicals like xylene, chloroform, Eucalyptol oil, Endosolv halothane can be used along with K-files.<sup>9</sup>

#### **Rotary Removal**

The file should be rotated in the groove of the carrier and advanced with light pressure. Frictional heat will melt the gutta-percha, allowing the instrument to advance apically and create a pilot channel.<sup>9</sup>

## **Silver Point Removal**

Access preparations must be thoughtfully planned and carefully performed to minimize the risk of inadvertently foreshortening any given silver point. Initial access is accomplished with high speed, surgical-length cutting tools, then ultrasonic instruments can be used to brush-cut away remaining restorative materials and fully expose the silver point.<sup>9</sup>

**Indirect Ultrasonics:** when a segment of silver point is encountered below orifice and space is restricted the CPR -3,4,5 ultrasonics are used. Files, solvents and chelators: in a solvent filled chamber files are used laterally to the silver point to break up increments and to undermine and loosen the silver point. Advantage: this method is used when grasping techniques or indirect ultrasonics are unsuccessful. Disadvantage: certain solvent and chelators sometime irritate periapical tissue.<sup>9</sup>

## **Paste Removal**

When evaluating a paste filled tooth for retreatment, it is useful to clinically understand that pastes can generally be divided into soft, penetrable and removable versus hard, impenetrable and at times, unremovable. An excellent technique for the safe removal of hard, impenetrable paste form the straightaway portion of a canal utilizes abrasively coated ultrasonic instruments in conjunction with the microscope.<sup>9</sup>

## **Removal of nickel-titanium instruments**

Nickel-titanium (NiTi) alloys tend to be brittle and removing them with ultrasonics can be frustrating. There are four phases in the retrieval of a fractured nickel-titanium instrument:

### **Modification of the Access Cavity**

A common reason for failure of nickel-titanium rotary instruments is inadequate access preparation. Placement of the access cavity in the incorrect position or making it too small puts unnecessary stress on the instrument as it is rotated in the root canal. Placement of the access cavity in the incorrect position or making it too small puts unnecessary stress on the instrument as it is rotated in the root canal. The instrument then fails as a result of cyclical fatigue. <sup>9</sup>

### **Bypassing**

If it is not possible to retrieve an instrument or the operator feels that the risk of perforation or irreversible damage is too great, then bypassing should be attempted. The technique for bypassing an instrument is similar to that for retrieving silver cones or fractured instruments.<sup>9</sup>

## **Retaining the Fractured Instrument**

If it proves impossible to retrieve or bypass the instrument, there is no alternative but to leave it within the root canal system. The root filling is completed to the most coronal part of the fractured object and the canal obturated. In teeth without periapical radiolucency, this should not appear to affect the prognosis.<sup>9</sup>

## **Post Removal**

The posts are used in the root canals after root canal treatment where the tooth loss is extensive.

## **Indications**

1. Primary purpose is to retain a core in a tooth with extensive loss of coronal tooth structure.
2. If an endodontically treated tooth is to receive a crown.
3. Pulp chambers are too small to provide adequate retention and resistance.<sup>9</sup>
- 4.

There are various types of posts available such as:

### **Metallic post**

### **Cast Posts**

They are commonly used to restore anterior teeth. More complex cast cores are sometimes found on posterior teeth and can be dismantled using similar methods.

There are three phases to the removal of a cast post :

- Removal of the coronal restoration – having decided on the form of temporary restoration, the coronal restoration covering the post and core is removed.
- Uncovering the post – any remaining restorative material covering the post will need to be removed using ultrasonics.
- Extraction – a small rest seat is cut into the core material in which the ultrasonic tip can be inserted. Ultrasonic force is applied in the long access of the tooth to help loosen the cement. If the post is not completely removed with ultrasonic vibration after a period of 10–15 minutes, an alternative method would be used and less force should subsequently be required.<sup>10</sup>

## **Post Removal Devices**

There are several post removal devices available such as:

The Sword post puller

The Egger post remover

The Ruddle post removal system

Essentially all these devices work on the principle of exerting a force between the root face and the post such that the cement lute can be broken. Once this has

been achieved, the post can easily be removed with Stieglitz forceps. Although post removers have been shown to be more efficient in removing posts, vibration with ultrasound does significantly decrease the force required for removal. Post removers should never be used to try removing screw-type posts.<sup>10</sup>

### **Management Of Procedural Errors**

Failure to respect the biological and mechanical objectives for shaping canals and cleaning root canal systems predisposes to needless complications such as blocks, ledges, external transportations and perforations.<sup>10</sup>

### **Managing Blocked Canals**

Management of blocked canals begin by confirming straight line access and then pre-enlarging the canal coronal to obstruction. Short amplitude, light pecking strokes are best utilized to ensure safety, carry the reagent deeper, and increases the possibility of canal negotiation. If the apical extent of the file “sticks” or engages, then it may be useful to move to a smaller sized hand file.<sup>10</sup> Depending on the severity of the blockage, preservance will oftentimes allow the clinician to reach the foramen and establish patency. If the blocked canal is not negotiable, then the case should be filled utilizing a hydraulic warm gutta-percha technique.

<sup>10</sup>

### **Management of ledges**

An internal transportation of the canal is termed as a “ledge” and frequently results when clinician work short of working length and block the canal. Ledges are typically on the outer wall of the canal curvature and often times bypassed. Once the tip of the file is apical to the ledge, it is moved in and out of the canal utilizing the ultra-short push-pull movements with emphasis on staying apical to the defect. When the files move freely, it may be turned clockwise upon withdrawal to rasp, reduce, smooth or eliminate the ledge.<sup>10</sup>

### **Management Of Apical Transportation**

A canal that has been transported exhibits reverse apical architecture and predisposes to poorly packed canals that are oftentimes vertically overextended but internally underfilled. In these instances, a barrier/restorative can be selected to control bleeding and provide a backstop to pack against during subsequent obturation procedures. The barrier of choice for transportation is generally mineral trioxide aggregate (MTA), commercially known as ProRoot. MTA is an extraordinary material which can be used in canals which exhibit reverse apical architecture, such as in transportations or immature roots, nonsurgical perforation repairs, or in surgical repairs.<sup>11</sup>

### **Management Of Perforations**

The causes of perforations are resorptive defects, caries, or iatrogenic events that occur during and after endodontic treatment. Earlier the techniques for managing the perforations were similar to that of managing apical transportations. However,

on occasion, tooth-coloured restoratives may be the material of choice for repairing certain perforations. Tooth-coloured restoratives such as dual cured composite, require the placement of a barrier so the material is not contaminated during use.<sup>11</sup>

A barrier serves as a “hemostatic” and a “back-stop” so a restorative material can be placed into a clean, dry preparation with control. Calcium sulphate is an excellent absorbable barrier material when using the principles of wet bonding because it is biocompatible, osteogenic, and following placement, sets brick hard.<sup>11</sup>

### **Irrigation and Medication**

Commonly used irrigants are:

- Sodium hypochlorite: 5.2% sol is most effective irrigant.
- Iodine solution: It is a halogen *E.faecalis* is sensitive to it.
- Chlorhexidine gluconate: It has relatively broad spectrum of activity used in conc. of 1-2%.
- EDTA: Chelating agent used to remove smear layer of dentin.
- MTAD-mixture of tetracycline and disinfectant: It removes both organic and inorganic debris.

### **Commonly used medicament:**

- Calcium hydroxide
- Iodine and iodine+ calcium hydroxide
- Antibiotics.<sup>11</sup>

### **Biomechanical Preparation and Reobturation**

Objectives:

1. To debride and disinfect the root canal system.
2. To contour the root canal wall and apical tip for the purpose of sealing the root canal completely with condensed, inert filling material.<sup>11</sup>

### **Reobturation**

After biomechanical preparation of root canal it is reobtured with GP cones and tooth is restored with filling materials. If there is less tooth structure left then post may be indicated.<sup>11</sup>

### **Surgical Retreatment**

#### **Endodontic surgery:**

Indications:

- When conventional retreatment has failed.
- Surgery is required when iatrogenic events, pathological processes or developmental anomalies prevent a nonsurgical approach.
- When biopsy or investigation required.

- In combination with nonsurgical technique.
- When it is difficult to undertake prolonged RCT.
- Periradicular disease associated with foreign body.
- In cases with procedural errors like apical perforation which cannot be treated.<sup>11</sup>

## **Contraindication For Surgical Retreatment**

### **General contraindications**

1. Medically compromised patients.
2. Emotionally distressed patients.
3. Limitation in the surgical skill and experienced operator.<sup>11</sup>

### **Local contraindications**

1. Local acute inflammation.
2. Anatomic consideration.
3. Inaccessible surgical sites.
4. Teeth with a poor prognosis<sup>11</sup>

## **Endodontic Surgical Procedures**

These are as under:

**Curettage:** It involves the removal of reactive soft tissue from around the root end with or without root end resection and cavity preparation.<sup>11</sup>

**Apicoectomy:** It includes the root end resection in order to identify the root canal and provide access to the source of infection.<sup>11</sup>

**Root amputation:** It involves the removal of an individual root from a multi-rooted tooth.<sup>11</sup>

**Hemisection:** It refers to sectioning of the crown of a molar tooth, with the removal of half the crown and its supporting root structure.<sup>11</sup>

**Perforation repair:** certain perforations are managed surgically.<sup>11</sup>

Various steps in surgical procedures include:

Administration of anaesthesia

Reflection of flap

Penetration of cortical plate

Curettage

Root end resection

Root end filling

Sutures

## **Surgical Versus Non-Surgical Retreatment**

Over the past various studies have been conducted to evaluate and compare success rates of surgical and non surgical retreatment.<sup>12</sup> Caliskan MK 2005 evaluated the outcome of nonsurgical retreatment of teeth with periapical lesions which had previously been managed by either endodontic or surgical intervention to identify the factors which can affect the prognosis. He concluded that nonsurgical root canal retreatment is an alternative to surgical intervention of postendodontic or postsurgical failure<sup>10</sup> Benenati FW and Khajotia SS 2002

determined the success of standardized nonsurgical endodontic treatments by using radiographic techniques. They concluded that the results were not affected by age and gender. <sup>12</sup>

## References

1. Ruddle CJ. Nonsurgical endodontic retreatment. CDA Journal 2004; 32(6),474-84.
2. Schilder H. Cleaning and shaping the root canal. Dent Clin North Am. 1974; 18,269-96.
3. Bystrom A. Evaluation of endodontic treatment of teeth with apical periodontitis. Thesis 1986; University of Umea.
4. Cohen S, Burns RC Pathways of the pulp. 8<sup>th</sup> ed. Chap 25, Pg 875-930.
5. Gorni FGM, Gagliani MM. The outcome of endodontic retreatment: A 2-yr follow-up. J Endod. 2004; 30(1),1-4.
6. Sjogren U, Hagglund B, Sundqvist G, Wing K Factors affecting the long-term results of endodontic treatment. J Endod. 1990; 16(10),498-504.
7. McGhee JR, Michalek SM, Cassel GH. Dental Microbiology. Philadelphia: Harper & Row; 1982.
8. Siqueira JF Jr. Uzeda M, Fonseca MEL. Scanning electron microscopic evaluation of vitro dentinal tubules penetration by selected anaerobic bacteria. J Endod. 1996; 22,308-10.
9. Rhodes JS. Advanced endodontics: clinical retreatment and surgery. 1<sup>st</sup> ed. Chap 2, Pg 23-44.
10. Caliskan MK. Nonsurgical retreatment of teeth with periapical lesions previously managed by either endodontic or surgical intervention. Oral Surg Oral Med Oral Pathol Oral Radiol Endod. 2005; 100,242-48.
11. Benenati FW, Khajotia SS. A radiographic recall evaluation of 894 endodontic cases treated in a dental school setting. J Endod. 2002; 28(5), 391-95.
12. Torabinejad M, Corr R, Handysides R, Shabahang S. Outcomes of nonsurgical retreatment and endodontic surgery: A systematic review J Endod. 2009; 35(7), 930-37.