

How to Cite:

Singh, A., Bhalla, P., & Gupta, G. (2021). Reconstruction of a single-tooth traumatic defect in the anterior maxilla using the khoury bone plate graft. *International Journal of Health Sciences*, 5(S2), 53–63. <https://doi.org/10.53730/ijhs.v5nS2.5363>

Reconstruction of a Single-tooth Traumatic Defect in the Anterior Maxilla using the Khoury Bone Plate Graft

Aman Singh

Department of Periodontics and Implantology, Desh Bhagat Dental College & Hospital, Mandi Gobindgarh, India

Pritish Bhalla

Department of Periodontics and Implantology, Desh Bhagat Dental College & Hospital, Mandi Gobindgarh, India

Gagandeep Gupta

Department of Periodontics and Implantology, Desh Bhagat Dental College & Hospital, Mandi Gobindgarh, India

Abstract---Often Trauma to teeth leads to defects in the dento-alveolar process which precludes many challenges to straight forward implant therapy of the patient. Bone and soft tissue augmentation hence becomes mandatory before any implant surgery can be undertaken. This helps in adequately preparing the site for implant and its restoration. Defects in the anterior aesthetic zone that require both bone and soft tissue grafting and a restoration that harmonizes the adjacent pink and white aesthetics presents even more significant challenge to the restorative team. Hereafter a case of trauma to an anterior maxillary tooth that saw destruction of the ridge is presented, with the defect reconstructed to accommodate a functional and aesthetically pleasing implant supported restoration.

Keywords---bone augmentation, implant therapy, anterior maxilla, plate graft.

Introduction

In spite of all the efforts to save the tooth, a traumatized tooth may lead to resorption of the alveolar process¹. Healing tooth socket only exaggerates the tissue loss if the tooth eventually needs to be removed. The result may be a ridge defect difficult to restore by straight forward and conventional implant therapy techniques. The maxillary anterior teeth are fundamental to the smile and in

International Journal of Health Sciences ISSN 2550-6978 E-ISSN 2550-696X © 2021.

Corresponding author: *authorname*; Email: dr.aman@aol.in

Manuscript submitted: 18 Sept 2021, Manuscript revised: 9 Nov 2021, Accepted for publication: 12 Dec 2021

addition to a patient's facial aesthetics provide lip support, speech, phonetics and incisor function 3. Reconstruction of a ridge defect prior to implant placement in this area is extremely important. The treatment would be even more important not to mention challenging should the ridge lack adequate vertical height in addition to a horizontal defect 4. If a tooth is in place and proper planning is done, the site can be prepared by orthodontic extrusion to draw the entire dento-gingival complex coronally 5. Alternatively, osseo-distraction may be a viable method in certain cases to gain ridge height 6. The site could also be "tented" by a mini-implant to support and provide space maintenance for a barrier membrane overlying a graft material 7. Alternatively, bone or bone substitute material block grafts could be fixed to the ridge as a scaffold to provide space maintenance for a GBR procedure. 2 Well reported in the literature is Misch's technique utilizing the mandibular ramus for harvesting an autogenous block of donor bone. 8 Khoury's split bone block technique similarly also harvests an autograft from the buccal shelf 9 or the symphysis region. 12 The bone block(s) fixed to the alveolar ridge recreate the bony envelope within which bone particulate may be packed to reconstruct the site. An implant may even be placed simultaneous to the augmentation should it be placed in the correct prosthetically planned position and with enough residual bone to gain acceptable primary stability. An aesthetically pleasing reconstruction of soft tissue also augment the gingival marginal seal around the restoration. 10, 11 despite the original defect an implant supported restoration can be provided to the patient that recreates pink and white aesthetics comparable to the neighboring teeth that may significantly improve the patient's quality of life.

Case report

A 27-year-old male patient had suffered blunt impact trauma to the face during a bicycle accident 12 years prior. Tooth 21 had been avulsed and the tooth socket was damaged from the impact (Figure 1, 2, 3). Patient was wearing a removal partial denture for last 10 years due to financial constraints. The patient sought definitive treatment for the potential edentulous space in his smile after being financial stable. A social history indicated he was a non-smoker, and the medical history was non-contributory. The neighboring maxillary teeth had high scalloped zeniths and a thin gingival biotype. Clinical examination of site 11 demonstrated probing depths greater than 15 mm both buccally and palatally. Cone beam computed tomography (CBCT) indicated drastic resorption of the tooth socket involving greater than two thirds of the tooth root on the buccal aspect (Fig.4a). Diagnostic IOPA RVG was also made (Figure 4b). The patient sought fixed restorative treatment. A treatment plan was then mutually agreed upon, planned as first surgery to augment the area, then the second surgery for implant placement to later be restored with a single tooth implant crown. The possible augmentation treatment options were given to the patient and an autogenous bone block procedure was then agreed upon, to be followed by the two-stage implant therapy. Preoperative planning by CBCT of the mandible indicated adequate safety for harvesting of a bone block from mandibular symphysis area (Figure 5).

The bone donor site was anaesthetized by bilateral mental nerve block. A horizontal sub crestal incision was made 3-4mm below the muco-gingival junction in

vestibular mucosa extending mesio-distally \pm 30 mm on to the labial shelf from the midline allowed for reflection of a full thickness flap exposing symphysis (Fig. 6). A bone block was then harvested using a Piezoelectric saw (Woodpecker Piezo) (Fig.7). The bone blocks were kept in sterile normal saline solution to preserve it for later use. Osteotomy was completed (Figure 8) and a 3.1 mm by 13mm Dentium NR Line Implant was placed (Figure 9). After the Implant placement was completed, the blocks were transferred to the recipient site (Figure 10), fitted in place and adjusted until the desired size and shape, all whilst harvesting the bone removed. Before securing the block the recipient site was conditioned with Citric acid and macro holes were made to increase the surface area. To firmly hold the Bone block, titanium mesh was placed and screwed with bone tags (Fig. 11,12,13). The site was also filled with Synthetic Bone Graft (Osteon II, Dentium) to fill the voids (Figure.14). The flap was closed and wound allowed to heal (Figure 15). Sutures were removed after 7days. IOPA radiograph was made to confirm positioning of fixtures (Figure16). The site was left undisturbed for 6 months. After 6 month the site was exposed, the titanium mesh, bone tags were removed, and Gingival former was given for 2 weeks. A CBCT was done at this stage to assess the healing (Figure 17). After 2 weeks of giving gingival former, impression was made, and patient was given a crown after 3 days. The post op CBCT revealed excellent healing and bone regeneration at the site.

Conclusion

Trauma to the orofacial region can be debilitating and detrimental to the patient, even as loss of a single tooth. Ridge defects can be challenging to reconstruct, especially in the anterior maxilla where aesthetic value is high. Compromising by omitting augmentation of the tissues to correctly accommodate a functional and aesthetic implant-supported restoration can result in poor aesthetics and treatment failure. Selecting the augmentation procedure requires meticulous planning, realistic goals in vertical height gain, coupled with knowledge of the procedure and good restorative principles. Alveolar bone ridge augmentation by autogenous bone block onlay grafting can produce aesthetically rehabilitative outcomes as reported here.

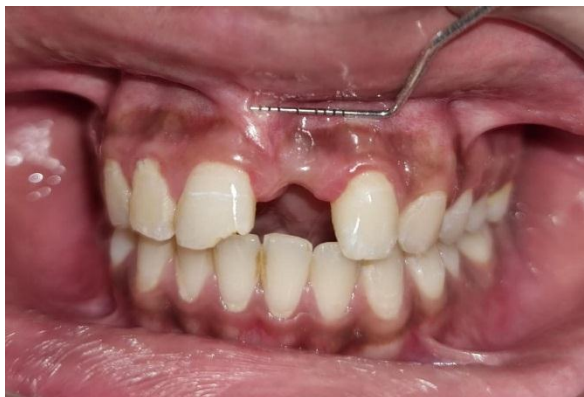

Figure 1. Missing 21

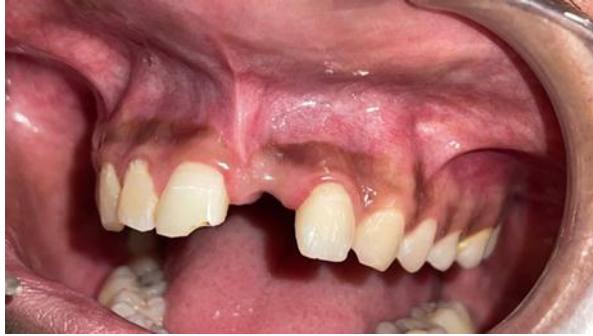

Figure 2. Missing 21

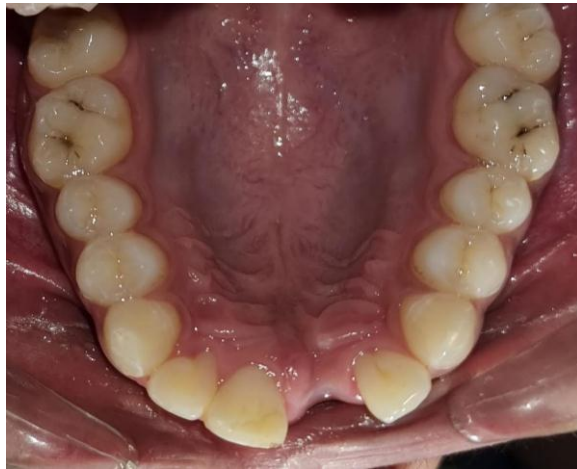

Figure 3. Missing 21

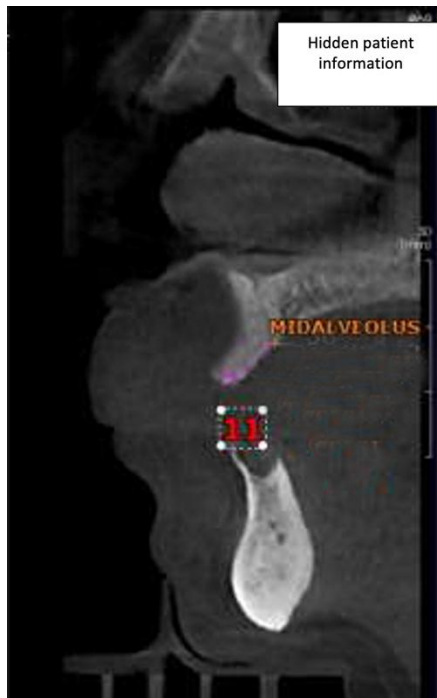

Figure 4b. CBCT of the Large Buccal Bony Defect

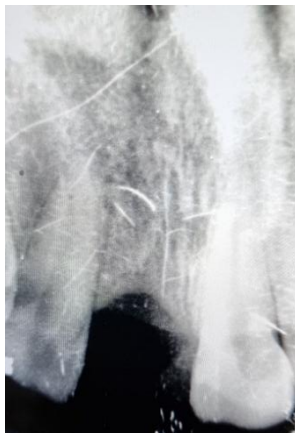

Figure 4a. IOPA RVG of the Missing 21

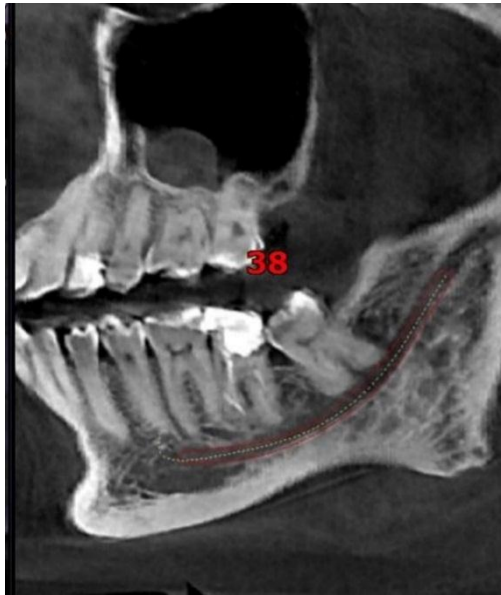


Figure 5. CBCT of Symphysis area showing adequate bone.

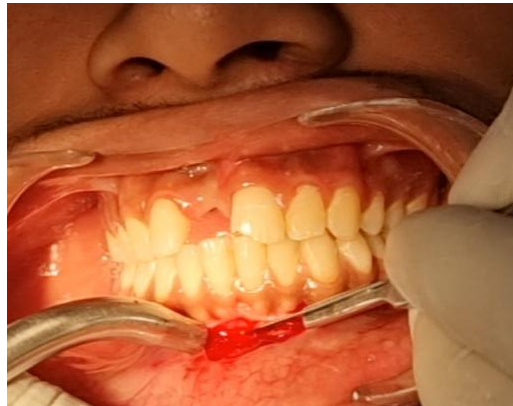

Figure 6. Incision at the Donor site.

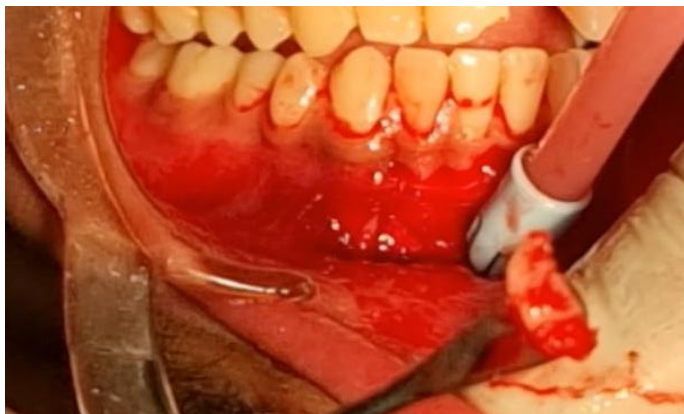

Figure 7. Harvested Bone Graft.

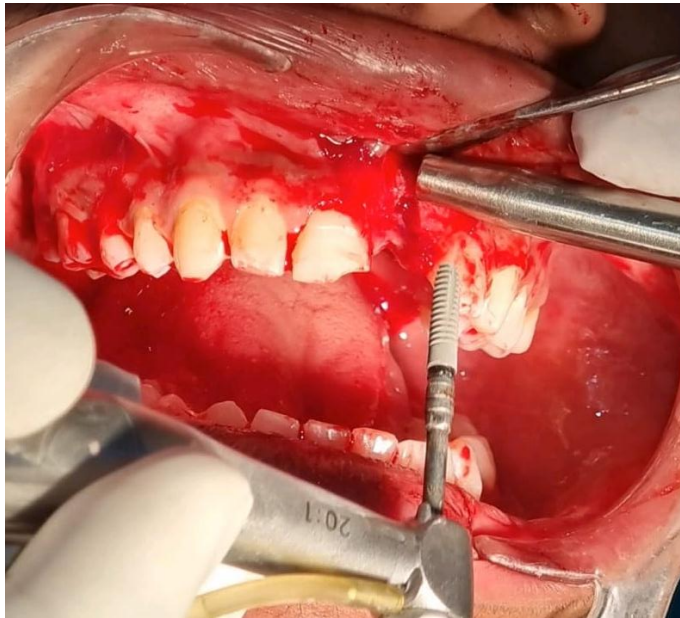


Figure 8. Osteotomy completed

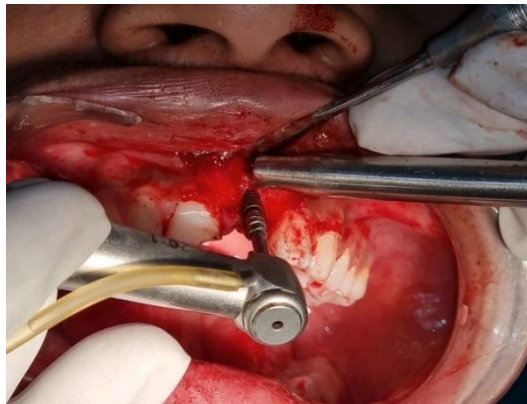


Figure 9. Implant Placed

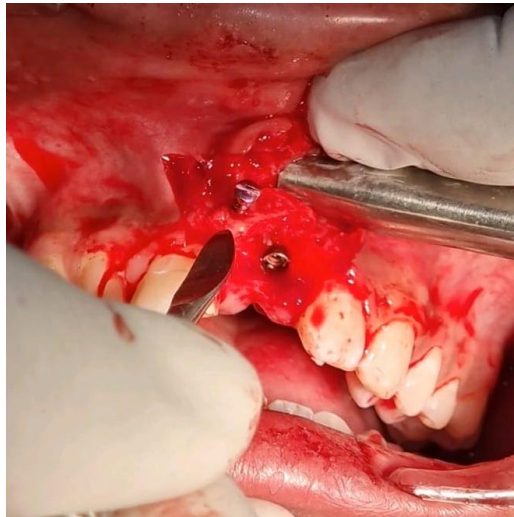


Figure 10. Bone Block stabilized

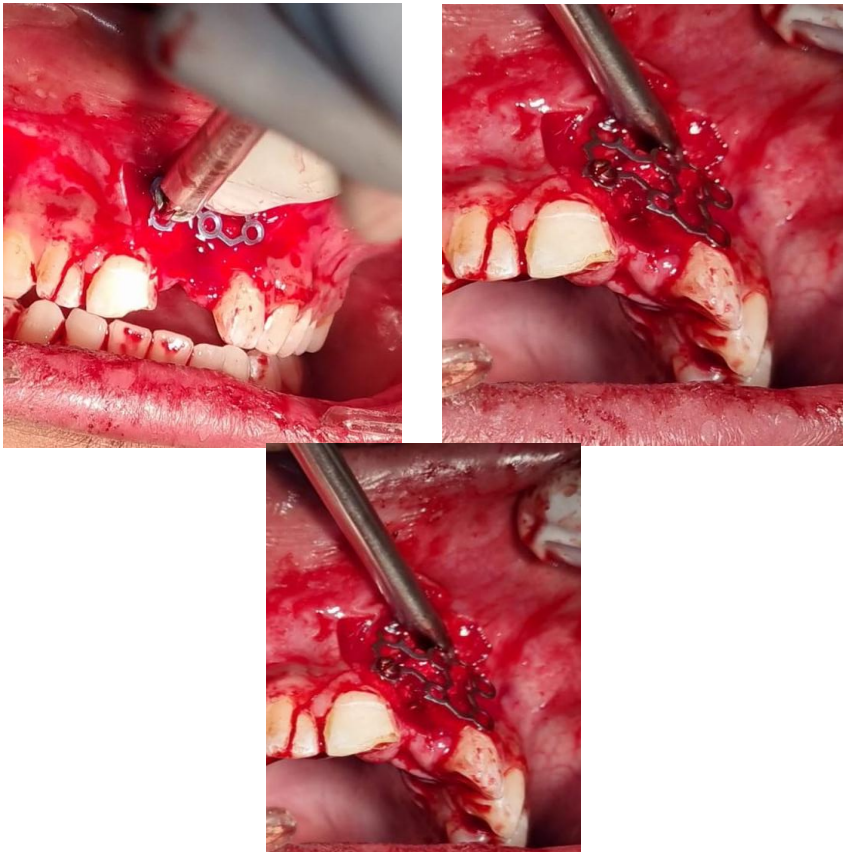


Figure 11,12,13. Bone Block further secured using Titanium mesh and bone tags

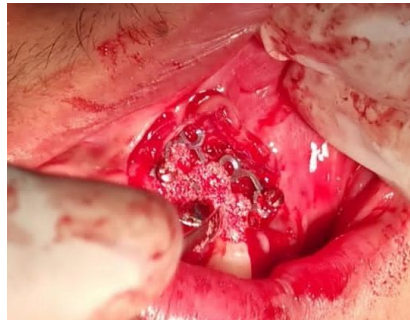

Figure 14. Synthetic Bone Graft Material (Osteon II, Dentium) used to fill the voids

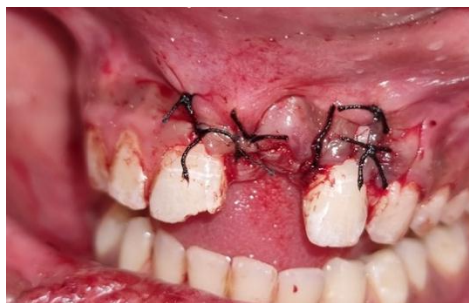

Figure 15. Flaps sutured

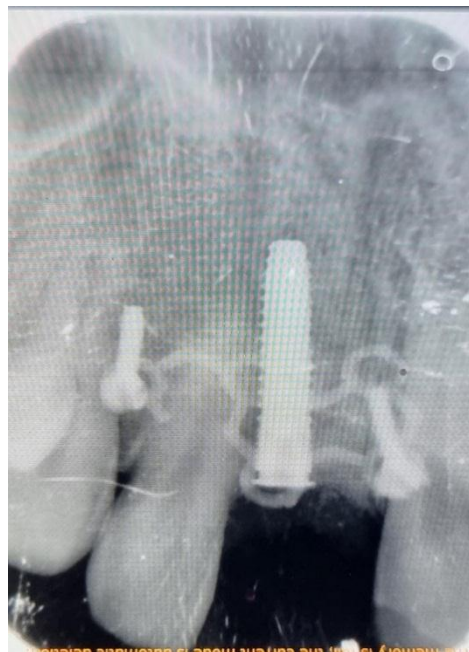

Figure 16. Post op Radiograph

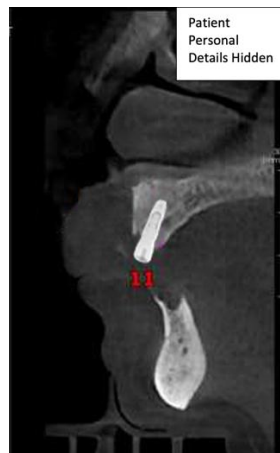

Figure 17. Post Healing CBCT

References

1. Andreasen FM. Transient root resorption after dental trauma: the clinician's dilemma. *J Esthet Restor Dent.* 2003;15(2):80-92.
2. Kuchler U, von Arx T. Horizontal ridge augmentation in conjunction with or prior to implant placement in the anterior maxilla: a systematic review. *Int J Oral Maxillofac Implants.* 2014;29 Suppl:14-24.
3. Comut A, Mehra M, Saito HJ. Pontic site development with a root submergence technique for a screw-retained prosthesis in the anterior maxilla. *Prosthet Dent.* 2013;110(5):337-43.
4. Louis PJ. Vertical ridge augmentation using titanium mesh. *Oral Maxillofac Surg Clin North Am.* 2010;22(3):353-68.
5. Kim SH, Tramontina VA, Papalexiou V, Luczyszyn SM. Orthodontic extrusion and implant site development using an interocclusal appliance for a severe mucogingival deformity: a clinical report. *J Prosthet Dent.* 2011;105(2):72-7.
6. Froum SJ, Rosenberg ES, Elian N, Tarnow D, Cho SC. Distraction osteogenesis for ridge augmentation: prevention and treatment of complications. Thirty case reports. *Int J Periodontics Restorative Dent.* 2008;28(4):337-45.
7. Buser D, Bragger U, Lang NP, Nyman S. Regeneration and enlargement of jaw bone using guided tissue regeneration. *Clin Oral Implants Res.* 1990;1(1):22-32.
8. Misch CE, Dietsch F. Autogenous bone grafts for endosteal implants--indications and failures. *Int J Oral Implantol.* 1991;8(1):13-20.
9. Khoury F, Antoun H, Missika P. Bone augmentation in oral implantology. UK: Quintessence; 2007.
10. Levine RA, Huynh-Ba G, Cochran DL. Soft tissue augmentation procedures for mucogingival defects in esthetic sites. *Int J Oral Maxillofac Implants.* 2014;29 Suppl:155-85.
11. Chen ST, Buser D. Esthetic outcomes following immediate and early implant placement in the anterior maxilla--a systematic review. *Int J Oral Maxillofac Implants.* 2014;29 Suppl:186-215.

12. Khoury F. Augmentation of the sinus floor with mandibular bone block and simultaneous implantation: a 6-year clinical investigation. *Int J Oral Maxillofac Implants*. 1999 Jul-Aug;14(4):557-64. PMID: 10453672.