



Wireless Microcurrent Stimulation Therapy for Wound Healing

Debryna Dewi Lumanauw,¹ Roys A. Pangayoman²

¹Department of Emergency Medicine, Harbor-UCLA Medical Center, Los Angeles, USA,

²Department of Surgery, Siloam Hospitals Simatupang, Jakarta, Indonesia

ABSTRACT

Wound healing is a complex process to restore the normal function, structure and integrity of body cells after injury. All wounds will advance to three phases: inflammatory, proliferative and maturation. When the sequence of healing does not go in timely and orderly manner, the wound becomes chronic and more difficult to heal. Chronic, nonhealing wounds require a tailored management. The most fundamental pillars are adequate debridement, managing underlying diseases/factors and applying proper dressings. Additional novel adjuvant therapies, such as electrical stimulation, hyperbaric chamber and ultrasound, are currently being developed. Wireless microcurrent stimulation (WMCS) is a new method for wound healing. Studies have recommended the use of WMCS, considering the safety, easy to use, and benefits.

Keywords: Chronic wound, wireless microcurrent stimulation, wound healing

ABSTRAK

Penyembuhan luka adalah proses kompleks untuk mengembalikan fungsi dan integritas seluler dan biokimiawi normal jaringan setelah terjadi luka. Semua luka akan melewati fase inflamasi, proliferasi, dan maturasi, hingga tercapai penyembuhan. Apabila proses penyembuhan tidak teratur dan tidak sesuai dengan waktu yang diharapkan, luka dapat menjadi kronis. Penanganan luka kronis memerlukan pendekatan yang sesuai dan dinamis. Pilar terpenting adalah *debridement* adekuat, mengatasi faktor-faktor predisposisi lain, dan pemilihan *dressing* yang tepat. Terapi tambahan lain seperti *electrical stimulation* (ES), *hyperbaric chamber* dan *ultrasound*. *Wireless microcurrent stimulation* (WMCS) merupakan perkembangan terbaru terapi ES. Beberapa penelitian membuktikan bahwa manfaat WMCS sama dengan metode konvensional, bahkan dapat menjadi pilihan terbaik karena aman, tidak mengiritasi, mudah dipindahkan dan digunakan. **Debryna Dewi Lumanauw, Roys A. Pangayoman.** *Wireless Microcurrent Stimulation* untuk Penyembuhan Luka

Kata kunci: Luka kronik, penyembuhan luka, *wireless microcurrent stimulation*

Wound Healing

Wound healing is a complex process when the body cells are trying to restore their normal function, structure and integrity after injury. The goal of every wound healing is regeneration: a perfect structural and functional cellular restoration achieved without any scar formation. However, this concept is only found during embryonic process or in certain compartments like bones and liver. In human skin, perfect repair is always sacrificed because of urgency of its function.

All wounds proceed through series of cellular and biochemical events to regain the normal tissue integrity. This event is commonly divided into three distinctive phases: inflammatory, proliferative and maturation. These phases often overlap which means a single wound

could have different phases simultaneously.

Hemostasis and Inflammatory Phase

Some authors describe hemostasis and inflammatory as two different, separate phases. Nonetheless, the inflammatory reaction is always initiated with hemostasis. This provides further evidence of the overlapping nature of wound healing phases. Within the first few minutes of injury, hemostasis occurs at the site of the wound to prevent further blood loss.^{1,2,5}

Platelet α -granules releases vasodilator substances such as platelet-derived growth factor (PDGF), transforming growth factor- β (TGF- β), insulin-like growth factor type I (IGF-I), fibronectin, fibrinogen and serotonin which will increase vascular permeability. The increased vascular permeability stimulates chemotactic factors (complements, interleukin-1) and

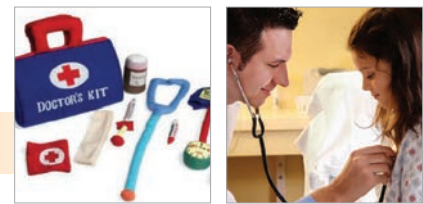prostaglandin to promote migration of PMNs, neutrophils and monocytes to the wound. This cell migration peaks at 24 – 48 hours after injury and the macrophages will continue its cleansing process until three to four days.²

Proliferative Phase

The acute response of hemostasis and inflammation subside after the fourth to twelfth day and the proliferative phase begins. This phase is characterized by repair of the underlying dermal and mesenchymal layer and neovascularization which will then lead to granulation tissue formation, followed by epithelialization of the epidermis.

During the inflammatory phase, fibroblasts migrate to the wound and lay down type I and III collagens needed for true fibrils formation. The wound has also been well suffused

Alamat Korespondensi email: debryna.lumanauw@emedharbor.edu, dr.roys.pangayoman@siloamhospitals.com



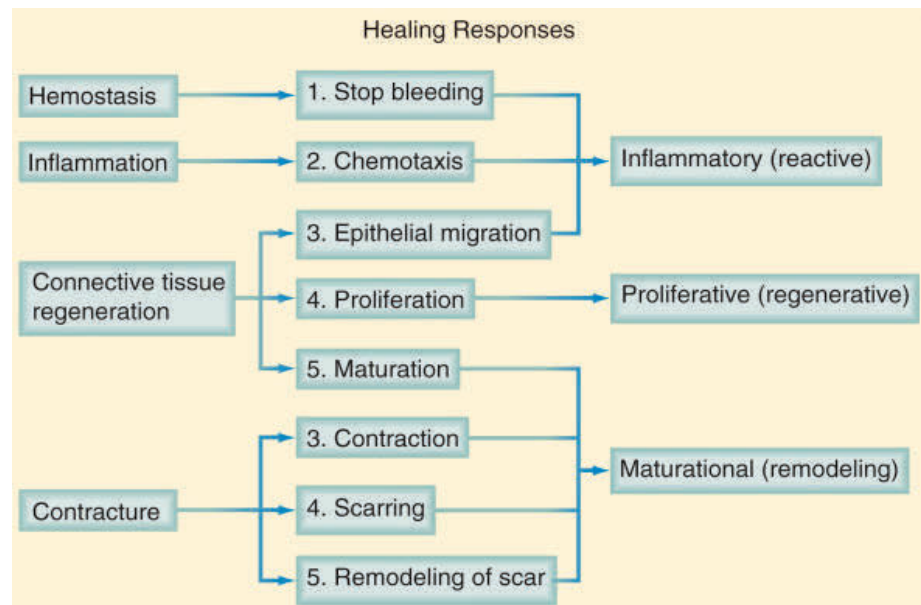
with glycosaminoglycan (GAGs), the most important amino sugar needed for matrix deposition. The formation of this substance is strongly dependent to other systemic factors such as oxygen supply, nutrition (amino acids and carbohydrates, vitamins and minerals) and the wound environment (vascular supply, infection). The growth factors that modulate angiogenesis during inflammatory phase continue to form the new vasculatures. EGF stimulates epithelialization since the first 24 hours after injury. The cells are migrated to the periphery of the wound and adnexal structures, creating a thin epithelial layer, which bridges the wound. This phase will be completed up to four weeks if the wound is clean and uncontaminated.

Remodelling and Maturation Phase

After third to fourth week, the collagen

deposition in the wound peaks and the remodeling phase begins. In this phase, the proliferative and neovascularization undergo a regression, followed by contraction of the wound. The wound contraction happens after an adequate proliferation of myofibroblast, which resemble contractile smooth muscle cells. The wound contraction occurs greater secondary healing compared to primary healing.

The tensile strength of the wound drastically increases during the first to sixth week after injury but the epidermal layer may still be fragile. Thereafter, it will go to a plateau state that can last for a year. Maximal tensile strength of the wound is achieved by the twelfth week, and the ultimate resultant scar has only 80% of the tensile strength of the original skin that is replaced.



Picture 1. Wound healing phases.¹

Table 1. Cytokines that affect wound healing.²

Growth Factor	Wound Cell Origin	Effects
Platelet derived growth factors (PDGF)	Platelets, macrophages, smooth muscle cells, endothelial cells	Chemotaxis, stimulation of angiogenesis, collagen synthesis
Fibroblast growth factors (FGF) and keratinocyte growth factors	Fibroblasts, keratinocytes, smooth muscle cells, endothelial cells	Stimulation of angiogenesis, fibroblasts, keratinocytes, myoblasts, chondrocytes
Epidermal growth factors (EGF)	Platelets, macrophages	Stimulates proliferation of epithelial cells
Transforming growth factors (TGF) α and β	Keratinocytes, platelets, macrophages, T lymphocytes, neutrophils	Stimulates wound matrix production, regulation of inflammation (also inhibits scar formation)
Insulin-like growth factors (IGF)	Platelets	Stimulates extracellular matrix synthesis and membrane glucose transport
Vascular endothelial growth factors (VEGF) and granulocyte-macrophage colony stimulating factor	Macrophages, fibroblasts, keratinocytes, endothelial cells	Stimulates macrophage proliferation, chemotaxis, stimulation of angiogenesis

Best Method for Wound Healing

For a successful wound healing, it is important to firstly decide which wound closure is the best. Three types of wound closure are primary, secondary and tertiary.

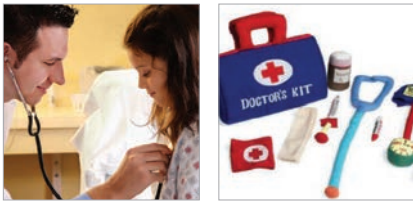In primary or first-intention wound healing, the wound is immediately sealed with simple suturing, skin graft, flap or other surgical techniques. This method is intended for uncomplicated wounds, e.g. a clean wound by surgical incision without any loss of tissue and secondary infection.

The other type of wound is an open and contaminated one with tissue defects that requires a more complicated process because large tissue losses need to be filled. This process takes longer and can only occur with secondary-intention healing because a large amount of granulation tissue must be formed to fill the tissue defect. Here, a spontaneous healing by epithelialization, followed by wound contraction, is expected and there is no active intent to seal the wound with any procedure.

Tertiary-intention wound healing, also known as delayed primary closure is the combination of the two methods. The wound is left open for a few days, allowing enough granulation tissue formed to raise the wound bed, and after that the wound will be closed in an orderly fashion. This method is also favorable for complicated wounds, with benefit of it taking less time than secondary-intention wound healing.^{1,2,4}

Secondary Wound Healing for Chronic Wound

Every normal, acute wound will undergo each healing phases in an orderly and timely process to restore its functional and structural integrity. When the reparative process fails to do so over a reasonable period, the wound becomes chronic. Chronic wounds stall at one or more phases of healing (usually during inflammatory phase), resulting in a far slower recovery of its mechanical strength compared to those with normal healing rate. It is characterized by the presence of a raised, hyperproliferative, yet non-advancing wound margin. The prolonged, continuous state of inflammation induces a cascade of tissue responses that impair and delay healing.



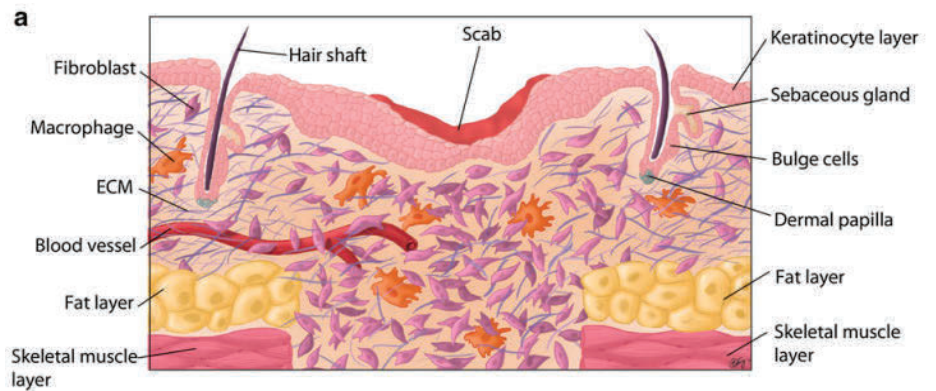
As chronic wounds heal neither in an orderly nor timely manner, the functional and anatomical restorations are not as satisfying as acute wounds and these wounds frequently relapse. This can be a very time consuming and costly process. Another element that might cause further challenge is that each wound has different characteristics and inconstant healing progress. A detailed understanding on the mechanism is needed to control the chronic inflammatory response and tissue repair, so that all chronic wounds can be treated meticulously with the most dynamic approach.⁶

The first step of chronic wound management is a thorough assessment of the wound and the patient. Identifying the etiology and underlying factors that may affect wound healing can facilitates physician to optimize patient's overall condition to create a more favorable environment for wound healing. In chronic wounds, however, it is rather complex since various factors can complicate healing process. These factors can be local and systemic. Local factors directly affect the wound environment, while systemic factors are the general health or disease state of the individual that may influence the process of wound healing.

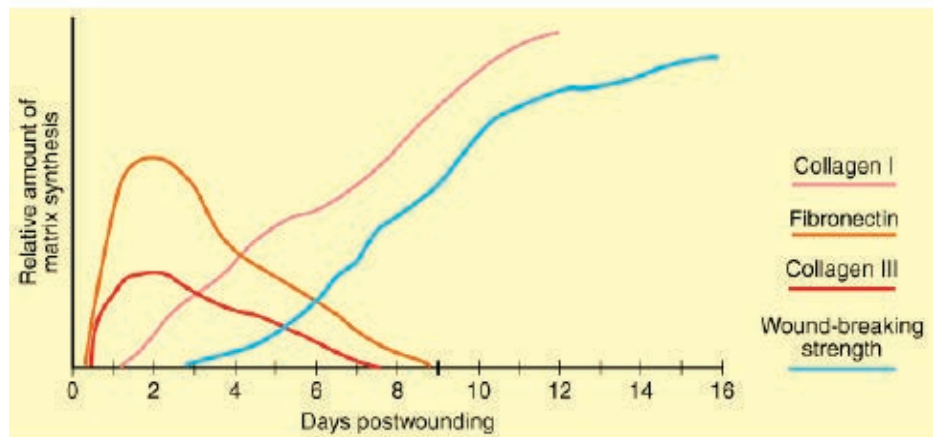
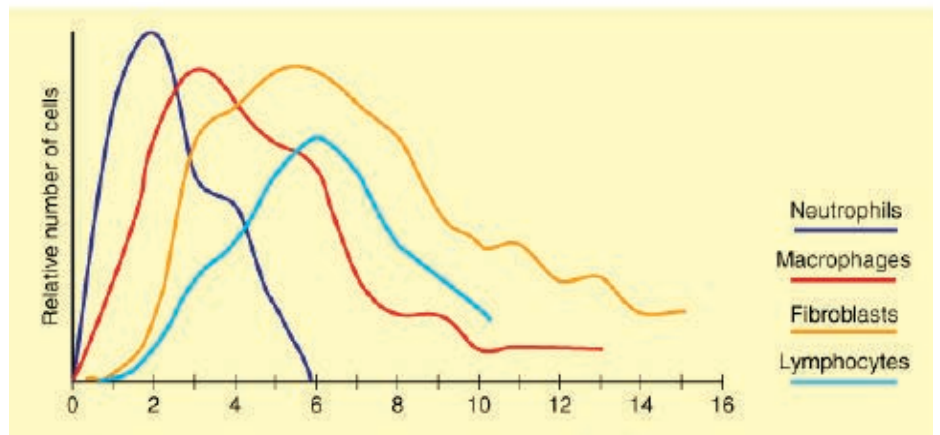
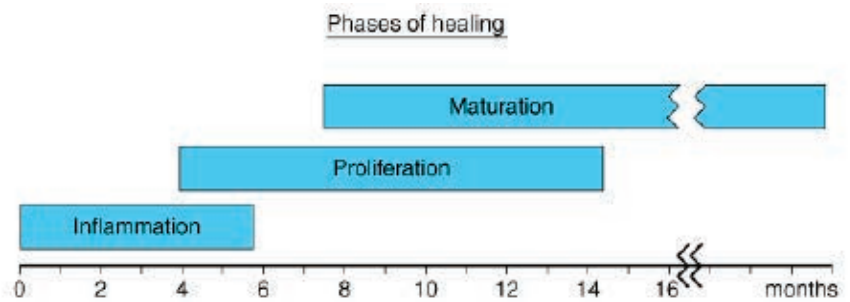
Another important component of wound healing is sufficient debridement by removing devitalized, non-viable, infected tissue, a potential feature for developing contamination and infection. Through proper debridement, a chronic wound may then be converted into an acute one, and then expectantly progress to normal wound healing phases.⁷

After the wound is comprehensively cleansed, a suitable selection of dressing must be taken into an account. The goal of appropriate dressing is to maintain moisture and keep the wound clean, so create the most ideal environment possible. The desired characteristics of wound dressings are:

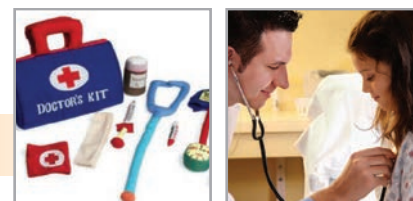
- Maintain a moist and clean environment
- Prevent pressure or mechanical trauma
- Nonallergenic and nonirritating
- Nontraumatic removal
- Convenience (less frequent dressing changes)
- Cost effective



Picture 2. Proliferative phase of wound healing.³



Picture 3. Normal timeline of wound healing.²

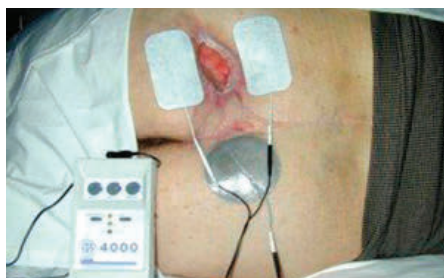

However, it is still far from a clinical reality to find one perfect dressing for every type of wounds. But technological advances are now promising.^{2,8}

Electrical Stimulation as a New Trend of Adjunctive Therapy

Many novel wound management options available in the market and the variety keeps growing. However, quality randomized controlled trials concerning their safety and efficacy are still lacking. Ultrasound, hyperbaric oxygen therapy and electrical stimulation seem to be the most promising therapies at present, with extensive theoretical, rational and preclinical studies.⁵

Electrical stimulation (ES) has long been believed as an effective adjunctive therapy to promote wound healing. ES has been widely documented and developed since early in the 19th century.¹⁰ The conventional application of ES requires a wet electrode pad in contact with the wound bed and external skin surface. Another two electrodes are needed to complete the electric circuit and the current will ultimately be transferred to the wound area (Picture 4).¹¹



Picture 4. Electrode placement near wound area.¹¹

There are, reported complaints of pain and risk of infection due to the electrodes in the wound area. An innovative method of ES, wireless micro current stimulation (WMCS), is recently introduced to tackle the problems and yet delivers the same effective benefits.¹²

Wireless Micro-Current Stimulation

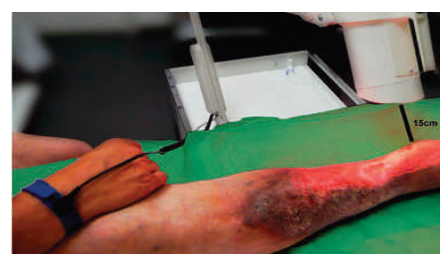The work mechanism of Wireless Micro Current Stimulation (WMCS) is principally the same as the ordinary ES. It has been proven that there is a surrounding electric field around the skin and tissue near the wound, which is known to play a significant role in wound healing. The current of this electric field, also called the "current of injury", was found to be in the intensity of less than 1 mA and it

extends up to a radius of 2-3 mm around the wound. This current of injury is constant when occlusive and moist dressing is applied. When the wound is left open and unprotected, the current decreased and as it heals, the current will also be gradually reduced.¹³

The use of ES enhances the mechanism of wound healing because it resembles the natural electric field or current of injury by galvanotaxis (directional movement of cells or any of its parts in response to an electric current). Certain chemotaxis factors such as neutrophils, macrophage, fibroblast and other epidermal cells are needed to provide autolysis, granulation tissue formation, anti-inflammatory activities and epidermal resurfacing. These cells carry either a positive or negative charge and the electrical stimulation helps to facilitate their attraction into the tissue. In inflammation phase, the stimulation of neutrophils and macrophage promoting phagocytosis and tissue oxygenation are enhanced. The galvanotaxic attraction also

stimulates fibroblast and epidermal cells, leading to faster granulation tissue formation and reepithelization.^{3,4}

Using available gases (nitrogen and oxygen), WMCS transfers thenegatively charged ions into the wound without touching the wound bed or surrounding skin. Nitrogen and oxygen will donate electrons and generate current. During treatment, a neutral electrode strap is connected to the patient's intact skin on the wrist or ankle. This will enable an adjustment of the current (1.5 - 4 μ A) and treatment duration in the control box.¹⁴



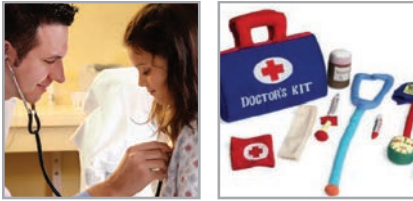Picture 5. WMCS therapy on chronic leg ulcer.

Table 2. Factors affecting wound healing.⁴

Local Factors	Systemic Factors
Oxygenation	Age
Infection	Sex hormones
Foreign Body	Obesity
Venous Insufficiency	Diseases: ischemia, keloids, uremia
	Immunocompromised conditions: diabetes, malignancy, AIDS
	Medications: glucocorticoid steroids, chemotherapy
	Lifestyle: nutrition, smoking, alcohol, stress

Table 3. Basic wound dressings.^{8,9}

Dressings	Advantages	Disadvantages	Indications	Frequency of Change
Low adherent dressings (gauzes, tulle)	Accessible Inexpensive	Poor barrier Drying	Packing deep wounds	Every 12 hours
Films	Moisture retentive Transparent, allowing visual check Semiocclusive Protect wound from contamination	No absorption Skin stripping Provides no cushion	Wounds with minimal exudate As a secondary dressing	Can leave up to 7 days or until fluid leaks
Hydrogels	Moisture retentive Nontraumatic removal	May overhydrate Need secondary dressing	Dry wounds Painful wounds	Every 1-3 days
Hydrocolloids	Absorbent Occlusive Protect wound from contamination	Fluid trapping Skin stripping Malodorous discharge Need secondary dressing	Wounds with minimal to moderate exudate	Can leave up to 7 days or until fluid leaks
Alginates	Highly absorbent Hemostatic	Fibrous debris Need secondary dressing	Wounds with moderate to heavy exudate Mild hemostasis	Can leave in place until soaked with exudate
Foams	Absorbent Thermal insulation Occlusive	Malodorous discharge	Wounds with minimal to moderate exudate	Every 3 days



The WMCS protocol specified treatment frequency of 2 – 3 sessions per week, for 45 – 60 minutes per session, with 1.5 μ A current intensity to exchange electrons. This protocol is to be used for patients with nonhealing wounds caused by venous insufficiency, arterial diseases, diabetes, pressure ulcers and pyoderma. One clinical study of 47 chronic wounds patients reported that the application of WMCS together with the standard wound care had significantly accelerated wound healing. The mean reduction of the wound area after WMCS treatment in eight weeks was 95% and complete healing was achieved within three months in most cases.¹⁵ No side effects reported during or after the use of

WMCS in numbers of studies.^{12,15,16}

WMCS vs. Other Means of Wound Healing Treatment

The previous method of ES had long been studied and received substantial positive reviews. ES has been more widely used and recommended in comparison to other adjunctive wound healing therapies, such as ultrasound or hyperbaric oxygen.⁵

Compared to the conventional ES, WMCS has the advantages of being noninvasive, pain-free, no risk of infection, easy to handle and transport. WMCS has no unwanted side effects on the wound and overall health. Most

recent studies on WMCS have also supported its effectiveness to speed up the process of wound healing. WMCS is still considered as new therapy and more researches are needed to review its use under other variables (eg. different etiology, cost effectiveness, frequency of treatment).^{12,16}

SUMMARY

This therapy works as an adjunctive treatment for wound healing. The fundamental pillars of wound care management (debridement, solving underlying problems and proper dressings) are indispensable and cannot be replaced by WMCS or any other adjunctive treatments.

REFERENCES

1. Townsend, Beauchamp, Evers, Mattox. Sabiston textbook of surgery. 20th ed. Texas: Saunders Elsevier; 2016.
2. Brunicaardi FC, Andersen DK, Billiar TR, Dunn DL, Hunter JG, Matthews JB, et al. Schwartz's Principles of Surgery. 9th ed. Los Angeles: McGraw-Hill; 2014.
3. Bielefeld KA, Amini-Nik S, Alman BA. Cutaneous wound healing: Recruiting developmental pathways for regeneration. Cell Mol Life Sci. 2013;70(1):2059–81
4. Guo S, DiPietro LA. Factors affecting wound healing. J DentRes. 2010;89(3):219-29.
5. Velnar T, Bailey T, Smrkolj V. The wound healing process: An overview of the cellular and molecular mechanisms. J Int Med Res. 2009;37(5):1528-42
6. Werdin F, Tennenhaus M, Schaller HE, Rennekampff HO. Evidence-based management strategies for treatment of chronic wounds. Eplasty [Internet]. 2009 [cited 2016 Aug 8];9:19. Available from: <http://www.ncbi.nlm.nih.gov/pmc/articles/PMC2691645/pdf/eplasty09e19.pdf>
7. Attinger CE, Bulan EJ. Débridement. The key initial first step in wound healing. Foot Ankle Clin. 2001;6(4):627-60.
8. Fonder MA, Lazarus GS, Cowan DA, Aronson-Cook B, Kohli AR, Mamelak AJ. Treating the chronic wound: A practical approach to the care of nonhealing wounds and wound care dressings. J Am Acad Dermatol. 2008;58(2):185-206.
9. Jones V, Grey JE, Harding KG. Wound dressings. BMJ. 2006;332(7544):777-80.
10. Thakral G, LaFontaine J, Najafi B, Talal TK, Kim P, Lavery LA. Electrical stimulation to accelerate wound healing. Diabetic Foot & Ankle. 2013;4:10.3402/dfa.v4i0.22081.
11. Kloth LC. Electrical stimulation technologies for wound healing. Advances in Wound Care. 2014;3(2):81-90.
12. Lagoumintzis G, Kambouris ME, Boltsis I, Ramadhinara A, Koureleas S, Koutsojannis C, et al. Clinical applications of wireless microcurrent stimulation. Proceedings of the BioEM2013; Jun 10 - 14, 2013.
13. Balakatounis KC, Angoules AG. Low-intensity electrical stimulation in wound healing: Review of the efficacy of externally applied currents resembling the current of injury. Eplasty [Internet]. 2008 [cited 2016 Aug 9];8:28. Available from: <http://www.ncbi.nlm.nih.gov/pmc/articles/PMC2396465/pdf/eplasty08e28.pdf>
14. Utama D, Wardhana A. The effects of wireless micro current stimulation for partial thickness burn injury treatment. Jurnal Plastik Rekonstruksi 2012;1(3):348-51
15. Wirsing PG, Habrom AD, Zehnder TM, Friedli S, Blatti M. Wireless micro current stimulation - an innovative electrical stimulation method for the treatment of patients with leg and diabetic foot ulcers. Int Wound J. 2015;12(6):693-8.
16. Ramadhinara A, Poulas K. Use of wireless microcurrent stimulation for the treatment of diabetes-related wounds: 2 Case reports. Advances in Skin & Wound Care 2013;6(1):1-4.