



# The Role of Conventional Chest X-Ray in Detection and Evaluation of Long COVID-19

Andri, Yuanita Amanda

Wahidin Sudirohusodo Hospital, Mojokerto, East Java, Indonesia

## ABSTRACT

A 52-year-old woman came to ER with shortness of breath, fever, and cough with oxygen saturation of 80% on room air. The COVID-19 PCR test was positive. CXR showed it infiltrates ground-glass opacities in both lungs and cardiomegaly. Chest X-ray at discharge from the hospital showed decreased infiltrate and fibrosis in two lung. She came to the ER 4 days later with worsened shortness of breath. CXR showed diffuse infiltrates in both lungs and cardiomegaly. **Discussion:** COVID-19 patients can develop long-term sequelae and complications (long COVID-19). Although CT is now considered the primary investigation for COVID-19, CXR is still valid for detecting and monitoring its progression. **Conclusion:** CXR is useful for detecting and monitoring the rapid advancement of lung abnormalities in long COVID-19.

**Keywords:** COVID-19, long COVID-19 chest X-ray

## ABSTRAK

Wanita 52 tahun datang ke IGD dengan sesak napas, demam, batuk; dengan saturasi oksigen 80% udara ruangan. Tes PCR COVID-19 positif. Rontgen toraks menunjukkan infiltrat di kedua lapangan paru, *ground glass opacities*, dan kardiomegali. Rontgen toraks saat keluar rumah sakit menunjukkan penurunan gambaran infiltrat dan fibrosis pada dua lapangan paru. Empat hari setelah keluar rumah sakit pasien kembali sesak napas. Rontgen toraks menunjukkan infiltrat difus di kedua paru dan kardiomegali. **Diskusi:** Pasien COVID-19 dapat mengalami sekuele jangka panjang dan komplikasi, disebut *long COVID-19*. Walaupun *CT-scan* menjadi pendeteksi utama COVID-19, rontgen toraks masih bermanfaat untuk memantau progresi sindrom tersebut. **Simpulan:** Rontgen toraks berguna untuk deteksi dan memantau kelainan paru pada *long COVID-19*. **Andri, Yuanita Amanda. Peranan Rontgen Toraks untuk Deteksi dan Evaluasi Long COVID-19.**

**Kata kunci:** COVID-19, foto toraks, *long COVID-19*

## INTRODUCTION

COVID-19 is a novel disease, causing a global pandemic with a risk of long-term sequelae, called long COVID-19.<sup>1</sup> The role of conventional radiography should be studied for the detection and evaluation of long COVID-19 because of its availability and its efficiency and ease to use.<sup>2</sup>

### Case

A 52-year-old woman came to ER with shortness of breath, fever, and cough with oxygen saturation on 80% room air. Her COVID-19 PCR Test was positive. The chest X-Ray AP position showed infiltrates and ground-glass opacities in both sides of the lung and cardiomegaly with CTR of 76% (Figure 1). The diagnosis was COVID-19 pneumonia.

She was admitted to the isolation room, treated with oxygen, anti-viral, antibiotics, vitamins, and other symptomatic drugs, and discharged after

three weeks. At discharge, her symptoms got better. The oxygen saturation was on 93% room air, but the COVID-19 PCR test was still positive. The chest X-Ray still showed infiltrates in both lungs with minimal visible improvement from the first CXR and cardiomegaly with CTR 76%; concluded as COVID-19 pneumonia seemed to improve from the first chest X-ray (Figure 2). She was discharged, followed by self-isolation at home.

She came to the ER again four days later with worsened shortness of breath. Her oxygen saturation dropped to 86% in room air. The COVID-19 PCR test was still positive, and the chest X-Ray showed deterioration. The chest X-Ray showed diffuse infiltrates in both lungs and cardiomegaly with a CTR of 74%. The conclusion was typical viral pneumonia (Figure 3).

She was readmitted and took a serial chest X-ray

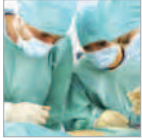for evaluation. After ten days, her symptoms got better; and the oxygen saturation was 97% in room air. COVID-19 PCR test was negative, and the chest X-Ray showed improvement. The chest X-Ray findings were decreased infiltrates and fibrotic on both lungs; resolution of opacities, and cardiomegaly with CTR of 78% (Figure 4).

### Discussion

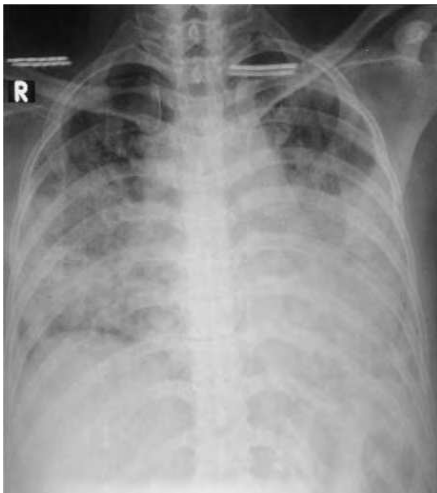COVID-19 patients can develop long-term sequelae and complications. National Institute for Health and Care Excellence (NICE) stated that ongoing symptomatic COVID-19 is defined as signs and symptoms that persist between 4 and 12 weeks from the onset of the infection.<sup>3</sup> A prospective study of COVID-19

patients found 13.3% had symptoms lasting  $\geq 4$  weeks.<sup>1</sup> This lasting effect has been termed long-COVID-19.<sup>1</sup> The term 'long COVID-19' includes both ongoing

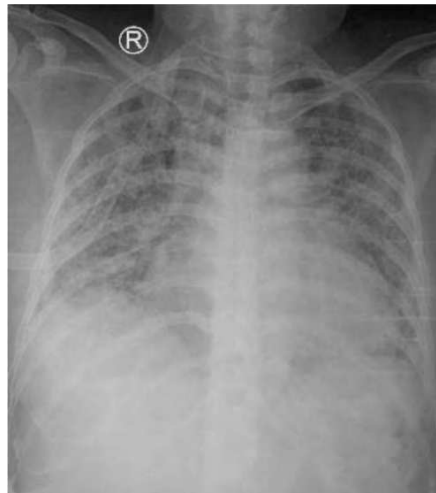
**Alamat Korespondensi** email: just.andri96@gmail.com, amandayuanita21@gmail.com



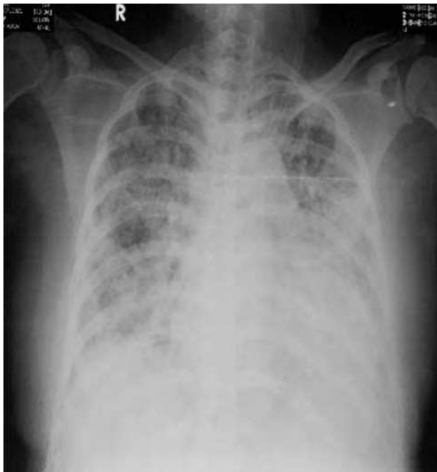## LAPORAN KASUS



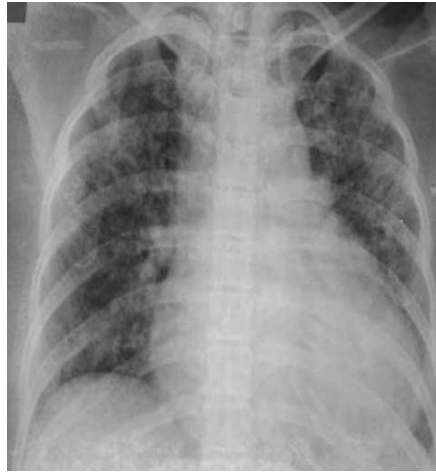**Figure 1.** Anteroposterior CXR at first admission - showed infiltrates, ground-glass opacities in both lungs and cardiomegaly



**Figure 3.** Anteroposterior CXR at second admission - showed infiltrates and ground-glass opacities on both lungs indicated COVID-19 pneumonia



**Figure 2.** Anteroposterior CXR at first discharge - showed infiltrates on both sides of the lungs and cardiomegaly



**Figure 4.** Anteroposterior CXR at second discharge - showed resolution of the infiltrates and opacities and the formation of fibrosis on both lungs

symptomatic COVID-19 (4–12 weeks) and pasca-COVID-19 syndrome (>12 weeks).<sup>3</sup> The clinical symptoms of this syndrome include fatigue, breathlessness, cough, joint pain,

chest pain, muscle aches, headaches.<sup>4</sup> These symptoms can be multisystemic, often appear as clusters, fluctuate over time, and can have a significant psychological and social impact on

patients. Therefore these symptoms should be detected as early as possible. It also needs to be regularly monitored.<sup>3</sup>

Chest X-ray (CXR) helps detect and monitor lung abnormalities in COVID-19, especially in critical patients admitted to intensive care units. It is also used as one of the proposed diagnostic criteria for long COVID-19.<sup>4</sup> In a review of SARS-CoV-2 pneumonia patients in Spain, none of the X-rays performed at 8-12 weeks were normal. Findings included reticular opacities/peripheral atelectasis in 88% of cases and ground-glass opacities in 61%. Remarkably, 25% of examinations showed poor inspiratory effort. In most patients who survive severe COVID-19, there is a significant tendency to develop fibrotic lung tissue.<sup>2</sup>

Although CT is now considered the primary investigation for COVID-19, not every health center has the facility, and the procedure requires maximum infection control measurements. The American College of Radiology finds this may disrupt the availability of radiological services and recommended portable chest X-ray (CXR) as a first-line triage tool.<sup>5</sup> With moderate ease of use and interpretation and common side effects, CXR remains one of the most used non-invasive chest imaging techniques, including for the follow-up of COVID-19. CT should still be performed to confirm the severity and progression of the disease.<sup>6</sup>

### Conclusion

Chest X-ray (CXR) helps detect and monitor the rapid progression of lung abnormalities in long COVID-19 because of the availability, ease of use, interpretation, and common side effects.

### REFERENCES

1. Omolulu A, Ojelade B, Ajayi O, Adesomi T, Alade O, Adebisi S, et al. Long COVID: A case report of persistent symptoms in a patient with prolonged SARS-CoV-2 shedding for over 110 days. *SAGE Open Medical Case Rep* 2021;9:1–3. doi: 10.1177/2050313X211015494
2. Alarcón-Rodríguez J, Fernández-Velilla M, Ureña-Vacas A, Martín-Pinacho JJ, Rigual-Bobillo JA, Jaureguizar-Oriol A, et al. Radiological management and follow-up of post COVID-19 patients. *Radiología* 2021;63:258–69. doi: 10.1016/j.rx.2021.02.003
3. Taribagil P, Creer D, Tahir H. Long COVID syndrome. *BMJ Case Rep*. 2021;14:e241485. doi:10.1136/bcr-2020-241485
4. Raveendran AV. Long COVID-19: Challenges in the diagnosis and proposed diagnostic criteria. *Diabetes & Metabolic Syndrome: Clin Res Reviews* 2021;15:145–6. <https://doi.org/10.1016/j.dsx.2020.12.025>
5. Yasin R, Gouda W. Chest X-ray findings monitoring COVID-19 disease course and severity. *Egypt J Radiol Nucl Med*. 2020;51:193. <https://doi.org/10.1186/s43055-020-00296-x>
6. Alqahtani JS, Alghamdi SM, Aldhahir AM, Althobiani M, Raya RP, Oyelade T. Thoracic imaging outcomes in COVID-19 survivors. *World J Radiol*. 2021;13(6):149–56. doi:10.4329/wjr.v13.i6.149