

Evidence Based Case Report

Neonatal Mastitis Treatment: Oral or Intravenous Antibiotics**Dion D. Samsudin,^{1*} Jason J. Samsudin,² Sonny Samsudin²****¹Department of Child Health, Faculty of Medicine Universitas Indonesia –
dr. Cipto Mangunkusumo National Hospital, Jakarta, Indonesia****²Faculty of Medicine, Universitas Katolik Atma Jaya, Jakarta, Indonesia**

*corresponding author: diondarius@gmail.com

Received 30 October 2019; Accepted 13 April 2020

DOI: 10.23886/ejki.8.11338.

Abstract

Neonatal mastitis (NM) is an infection of the breast which ultimately leads to abscess and sepsis. Up to date, there is no general consensus of therapy for NM, and physicians have broad therapy preferences. Twenty-eight-day-old baby came to the outpatient clinic with chief complaint of enlarged breast since 1 week before admission, with a mild sign of infection and no systemic symptoms. Laboratory examination revealed a normal result. The patient was discharged with oral antibiotics. Is this treatment adequate? Is intravenous antibiotics needed for this case? A literature search was performed from 3 databases: Pubmed, Google Scholar, Cochrane with keywords: "neonatal mastitis," "treatment," "oral antibiotics," "intravenous antibiotics," and "effectiveness". Two articles were found to be relevant to answer the research questions. Failure with oral antibiotics in NM reached up to 71%, and intravenous antibiotics is still the treatment of choice for severe NM. Complete blood count and blood and discharge culture should be performed in all NM cases. A suggestion for clinical pathway of NM in Indonesia was provided in this article. NM is a severe infection which might develop into abscess or sepsis. Complete blood count and blood and discharge culture should be performed in all suspected NM cases. Oral antibiotics can only be considered in mild NM cases with routine follow-up.

Keywords: Neonatal, mastitis, antibiotics, oral, intravenous.

Mastitis pada Bayi: Terapi Antibiotik Oral atau Intravena**Abstrak**

Mastitis neonatal (MN) adalah kondisi infeksi pada payudara bayi yang dapat menyebabkan abses dan sepsis. Sampai saat ini tidak ada panduan terapi untuk MN, dan setiap dokter memiliki preferensi yang berbeda dalam menangani kasus tersebut. Bayi usia 28 hari datang ke klinik dengan keluhan payudara membesar sejak 1 minggu yang lalu dengan tanda infeksi ringan. Pemeriksaan laboratorium didapatkan hasil normal, kemudian pasien dilakukan rawat jalan dengan antibiotik oral. Apakah terapi ini sudah adekuat dan apakah terapi antibiotik intravena masih diperlukan? Dilakukan pencarian literatur terhadap 3 database: Pubmed, Google Scholar, Cochrane dengan kata kunci "neonatal mastitis," "treatment," "oral antibiotics," "intravenous antibiotics," and "effectiveness." Ditemukan 2 artikel yang relevan untuk menjawab pertanyaan penelitian. Kegagalan terapi oral antibiotik pada kasus MN mencapai 71%. Kasus MN berat harus mendapat antibiotik intravena selama 2-5 hari, kemudian dilanjutkan dengan antibiotik oral selama 7-14 hari. Pemeriksaan laboratorium lengkap dan kultur resistensi dianjurkan terhadap seluruh kasus MN. Rekomendasi clinical pathway penanganan MN di Indonesia disertakan dalam artikel ini. MN adalah kondisi infeksi serius yang dapat berkembang menjadi abses dan sepsis. Pemeriksaan darah lengkap dan kultur resistensi harus dilakukan terhadap seluruh kasus MN, dan antibiotik oral hanya dapat dipergunakan untuk kasus MN ringan dengan pengawasan ketat.

Kata kunci: Neonatus, mastitis, antibiotik, oral, intravena

Introduction

Breast enlargement in neonates is a common chief complaint upon health visits to a general practitioner or pediatrician. Normal breast enlargement in neonates is caused by the falling levels of estrogen, which trigger the pituitary gland of the newborn to produce prolactin. This condition typically affects full-term infants, equally between male and female gender, mostly appears in the first week of life, with no sign of inflammation.¹ It may generate a clear or milky discharge from the nipple. This condition is normal and expected to resolve in a few weeks to months.¹

Breast enlargement in neonates may be complicated by infection and even developing into an abscess, this is known as neonatal mastitis (NM), which is an uncommon condition, with very little data on the prevalence worldwide.² Data from the Havana province in Cuba showed the incidence of 3.5 cases per 1000 live birth (0.35%).³ Incidence data from Indonesia was not available.

Swift treatment for NM is important because it may develop into an abscess and ultimately, sepsis if not adequately treated. Because of the infrequent incidence, there are no treatment guidelines, and there is disruption among physician's preferences, specifically to treat or not to treat, additional workup and what types of treatment should be administered.⁴ Regardless of the severity of the disease, outpatient treatment is preferable for neonates because it will promote better bonding with the parents and a higher chance of successful breastfeeding.⁵ Severe cases, however, may require intravenous (IV) antibiotics and even surgical care for abscess drainage.⁴

This evidence-based case report will elaborate on a neonate with a mild case of NM, and regarding the treatment dilemma: to use oral or intravenous antibiotics. What is the current evidence?

Clinical Scenario

Twenty-eight-day-old female baby came to our outpatient clinic in district hospital Ibnu Sutowo, Baturaja town, Sumatera Selatan province, Indonesia, with a chief complaint of bilateral breast enlargement since one week before admission. Mother started to notice bilateral breast swelling, which gradually enlarged, the baby cried when the breast was touched, suggesting pain sensation there was a discharge of clear fluid, which later becomes milky white. There was no fever, no vomiting, no abdominal distention, urination, and defecation were normal.

The patient was the second child in the family, full-term gestation, with no record of antenatal visit or ultrasound examination. The patient was delivered via vaginal route by the midwife, complicated by green amniotic fluid and foul smell, the baby cried spontaneously. There was no post-labor care in the primary health center or hospital (physical examination upon birth: body length: 47 cm, bodyweight: 3 kg, head circumference: 32 cm, with normal anatomy). The patient was exclusively breastfed, the house was located approximately 50 kilometers from the hospital.

Physical examination at the clinic showed a bodyweight of 3.3 kg, active baby, with normal vital signs. Chest examination revealed bilateral breast enlargement the size of 3x3 cm depth 0.5 cm, hard consistency, slight reddish skin color, slightly warm to touch Figure 1(A). Upon light touch, the right breast discharged suppurative fluid, and the baby cried Figure 1(B). There was no fluid discharge on the left breast. Another physical examination of the baby was unremarkable. Other source of infection was not found. Laboratory examination revealed no abnormalities. Hemoglobin 14.7 g/dL, hematocrite 48%, leukocyte 11.800/uL, granulocyte 65%, lymphocyte 30%, monocyte 5%, thrombocyte 343.000/uL, erythrocyte sedimentation rate (ESR) 10mm/hour.

Patient was diagnosed with mild NM and was discharged with oral antibiotics amoxicillin and topical ointment of steroid and antibiotic cream. Patient was advised to immediately seek medical care if there is worsening of condition such as fever or abscess formation. Follow up consultation was scheduled in one week.

Methods

Formulation of The Research

Neonatal mastitis primary treatment is antibiotics, and intravenous route is preferred because it provided higher bioavailability and higher effectiveness. However, inpatient care has its disadvantages and most parents prefer outpatient care. Therefore lies our research question: can neonatal mastitis be treated with oral antibiotics? How is the effectiveness? Population (P): Neonatal mastitis; Intervention (I): Oral antibiotics; Comparison (C): Intravenous antibiotics; Outcome (O): Effectiveness.

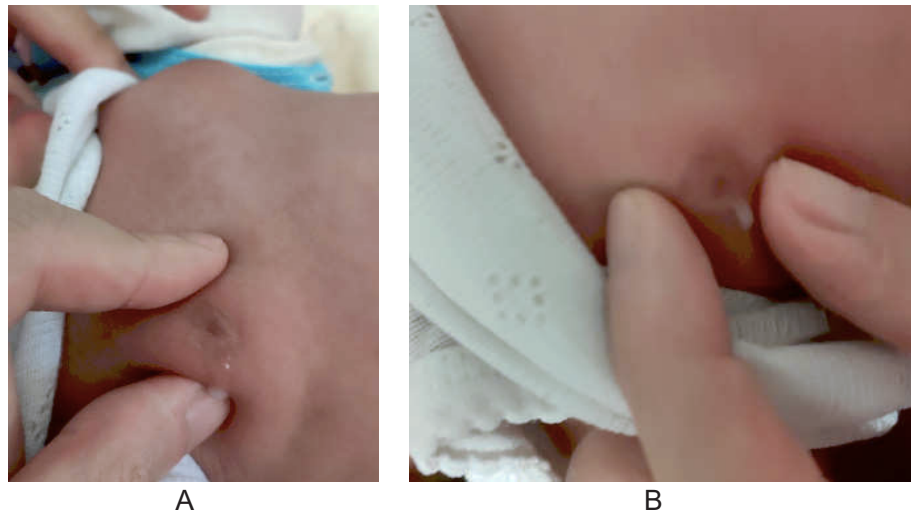


Figure 1. (A) Bilateral Breast Enlargement with Slightly Reddish Color. (B) Suppurative Breast Discharge from The Right Breast Upon Slight Touch

Evidence Research Strategy

To answer our research question, we performed an online literature search via search engines: Pubmed, Google Scholar, and Cochrane. The keywords used were “neonatal mastitis,” “treatment,” “oral antibiotic,” “intravenous antibiotic,” and “effectiveness.” Result was not limited to

publication year, language, or research types. Every article is reviewed if deemed to be relevant to our research question. The initial result revealed 10 articles after reviewed for abstracts and full texts, 2 articles were considered relevant and included in our report (Figure 2). Level of evidence (LoE) was determined from the Oxford Centre for Evidence-Based Medicine Level of Evidence classification.⁶

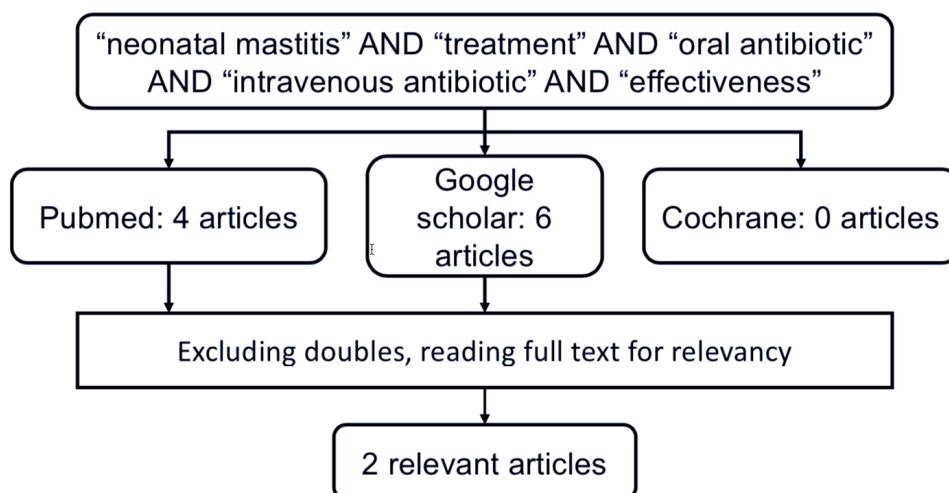


Figure 2. Literature Search and Results

Results

Our literature search found two relevant articles to answer our research question, an individual case-control study by Masoodi et al.,⁷ and a case series by Ruwaili et al.⁸ An individual case-control study was performed by Masoodi et al.⁷ in a tertiary hospital in Kashmir, India, from the year 2011 to 2013. The aim is to study the microbial sensitivity pattern and suggest an effective treatment plan for NM. 32 babies age 6-48 days with mastitis were recruited for this study; the ratio of male to female was 1:2. Besides fulfilling history and physical examination, complete blood count with C-reactive protein (CRP) was done for all patients. Duration of symptoms ranged from 1-7 days, and all patients were breastfed.

The patients appeared well and systemic problems were noted in only 6 patients (19%), fever in 5 patients (16%), and refusal of feeds in 3 patients (9%). Five out of 32 patients (16%) had bilateral breast involvement. Breast abscess was identified in 63% of patients. Polymorphonuclear leukocytosis (defined as leukocyte count more than 17.000/uL and polymorphs >70% was observed in 18 patients (56%) and CRP was positive in 20 patients (63%). Pus discharge was obtained from 23 patients (72%) and cultured, which showed gram-positive cocci in 13 patients (40%) and gram-negative rods in 1 patient.

Seven patients (22%) was pretreated with oral amoxicillin and cefpodoxime, 5 out of 7 (71%) developed breast abscess and was treated with IV antibiotics (penicillin/ cephalosporin and aminoglycoside). The rest of the patients were treated with intravenous antibiotics for 2-5 days, followed by oral antibiotic for 7-14 days (amoxicillin-clavulanate/ cephalexin/ linezolid or clindamycin). The open incision for pus drainage was performed in patients with abscess. The author concluded that oral treatment failure was apparently due to poor compliance and poor bioavailability of the drugs in neonates. An intravenous antibiotic was given based on the culture sensitivity result, and a satisfactory response was achieved.

The study was conducted by Ruwaili et al.⁸ in a tertiary hospital in Toronto, Canada. All neonates with mastitis over 9 year (2000-2009) were reviewed for clinical presentations, investigations performed, and treatment choices. Before the start of the research, a survey was conducted to pediatric emergency staff to estimate their action towards a 2-week-old afebrile baby without any sign of toxicity with clear signs of unilateral mastitis. Forty-six physicians were included in this survey, and 4.3% would perform a full sepsis workup, lumbar puncture, followed by IV antibiotics and hospital admission. Twenty-eight percent chose discharge on oral antibiotics, and 45% considered admission only if blood work showed abnormalities or suggests sepsis.

Over 9 years, 12 neonates were diagnosed with NM, 10 females and 2 males, with a mean age of 17.9 days. The mean duration of symptoms before presentation to the emergency department was 2.6 days. Breast abscess and purulent breast discharge was apparent in 50% of the patients. Complete blood count was performed in 75% of the patients, and 44% showed high leukocyte (14.400-24.000 /uL) with a high band count. All six patients who had breast discharge was cultured and positive for *Staphylococcus aureus*.

Among the 12 neonates with NM, 8 patients (66%) was admitted and started IV antibiotics, 2 patients (17%) received oral antibiotics, and 2 patients (17%) received no antibiotics. Patients was treated with IV antibiotics (cloxacillin/ cefotaxime/ tobramycin/ cefazolin) for 2-5 days, followed by oral antibiotics for 7 days. Two patients received oral antibiotics cloxacillin, one of the patient returned after 48 days because the condition was not improving, and was admitted and started on intravenous antibiotics. It was concluded that there are differences between physicians in the treatment of NM. However in general, non-toxic infants with mastitis can be managed with only limited investigation, and oral antibiotic treatment can be considered with routine follow-up. The summary of critical appraisal of both articles are provided in Table 1.

Table 1. Summary of Critical Appraisal of Individual Case Control Study and Case Series

Article	Masoodi et al ⁷ (2014)	Ruwalli et al ⁸ (2012)
Research design	Individual case control study	Case series
Level of evidence	3b	4
PICO	P: Neonates with NM I: Intravenous antibiotics C: Oral Antibiotics O: Microbial sensitivity pattern and treatment effectiveness	P: Neonates with NM I: Intravenous antibiotics C: Oral Antibiotics O: Clinical presentations, investigations performed and treatment choices
Validity	Recruitment 32 babies age 6-48 days with mastitis were recruited for this study. there was no randomization on the group, and allocation to intravenous or oral antibiotics was not explained. Research was conducted from 2011 to 2013 in a tertiary hospital in Kashmir, India. Allocation: Subject was observed based on clinical symptoms and culture results. Maintenance: Both groups received the same monitoring protocol. Measurement: Microbial sensitivity pattern, clinical amelioration. Conclusion: valid	Recruitment 12 babies with confirmed diagnosis of mastitis were included in the study. Complete blood count and blood and breast discharge (when available) culture were performed. Eight out of 12 patients (66%) received IV antibiotics, 2 patients (17%) received oral antibiotics cloxacillin and 2 patients (17%) received no antibiotics. Patient allocation was not specified. Research was conducted by tracing medical record over the year 2000 to 2009 from a tertiary hospital in Toronto, Canada. Allocation: Subject was observed based on clinical symptoms and culture results. Maintenance: Both groups received the same monitoring protocol. Measurement: Microbial sensitivity pattern, investigation result, clinical amelioration. Conclusion: valid
Importance	Result: Seven out of 32 patients (22%) were treated with oral amoxicillin and cefpodoxime, 5 out of 7 patients (71%) developed breast abscess and considered a treatment failure, and IV antibiotics were introduced (penicillin/ cephalosporin and aminoglycoside). The duration for IV antibiotic treatment was 2-5 days, and treatment was continued with oral antibiotics (amoxicillin-clavulanate/ cephalexin/ linezolid or clindamycin) for 7-14 days. The failure of oral treatment was due to bad compliance and poor bioavailability of the drugs in the neonates. IV antibiotic treatment was successful.	Result: Complete blood count was performed in 75% of the subjects, and 44% showed increased leukocyte (14.400-24.000/uL) with high band count. Patient with breast discharged was cultured and was tested positive for <i>Staphylococcus aureus</i> . Patients who received IV antibiotics (cloxacillin/ cefotaxime/ tobramycin or cefazolin) for 2-5 days had a good clinical response. The treatment was continued with oral antibiotics for 7 days (cloxacillin). Two patients who initially treated with oral antibiotics (cloxacillin), one of the patient returned after 48 hours because the condition did not improve, and was admitted and started on IV antibiotics. During the study, 46 physicians were questioned on their plan against a 2 weeks old afebrile baby without any sign of toxicity with a clear sign of unilateral mastitis. In essence, 4.3% would perform full sepsis workup, lumbar puncture followed by IV antibiotics, 28% would discharge the patient with oral antibiotics, and 45% considered admission only if the blood work showed abnormalities. The author concluded that oral antibiotics are useful only for a mild case of NM, and that there are inconsistencies in the management of NM between physicians.
Applicability	Is the population similar? Yes Can the intervention be applied in my workplace? Yes Do the benefits outweigh the weaknesses? Yes	Is the population similar? Yes Can the intervention be applied in my workplace? Yes Do the benefits outweigh the weaknesses? Yes

Discussion

Neonatal mastitis is a rare condition in neonates characterized by enlargement of the breast with sign of inflammation (hyperemic, warm to touch, pain, breast discharge), this condition is more prominent in female than male, and most of this case is not accompanied by other systemic complain such as fever, lethargy, irritability or feeding refusal.¹ Extensive clinical presentation is reported in NM, ranging from breast enlargement without obvious sign of infection until suppurative abscess on one side of the breast, which requires aggressive antibiotics treatment.^{7,8} Major bacteria cultivated from NM cases are the gram-positive *Staphylococcus aureus*, which served antibiotics as the primary treatment. In every antibiotic therapy, a physician must consider the method of delivery (oral, intravenous, or topical) and the types of antibiotics (broad spectrum antibiotic followed by culture sensitivity result).^{9,10} Overtreatment may cause antimicrobial resistance and other

unwanted reaction, and under treatment may cause worsening of the condition which can ultimately lead to sepsis.^{11,12}

Despite our rigorous effort to search for literature, we did not find a good systematic review or case-control trial to answer our research question, our best evidence was gathered from an individual case control study (LoE 3b) and a case series (LoE 4).⁶⁻⁸

Our literature review provided evidence that IV antibiotics are the preferred treatment for NM, with the satisfactory result after 2-5 days, and must be continued with oral antibiotics for 7-14 days.^{7,8} Initial therapy with oral antibiotics have a failure rate of 50-71% and possesses several problems such as bad compliance and the need for routine monitoring for symptoms progression.^{7,8} Cases of NM which benefits from oral antibiotics are mild cases with no systemic symptoms and routine laboratory workup results.^{1,7,8}

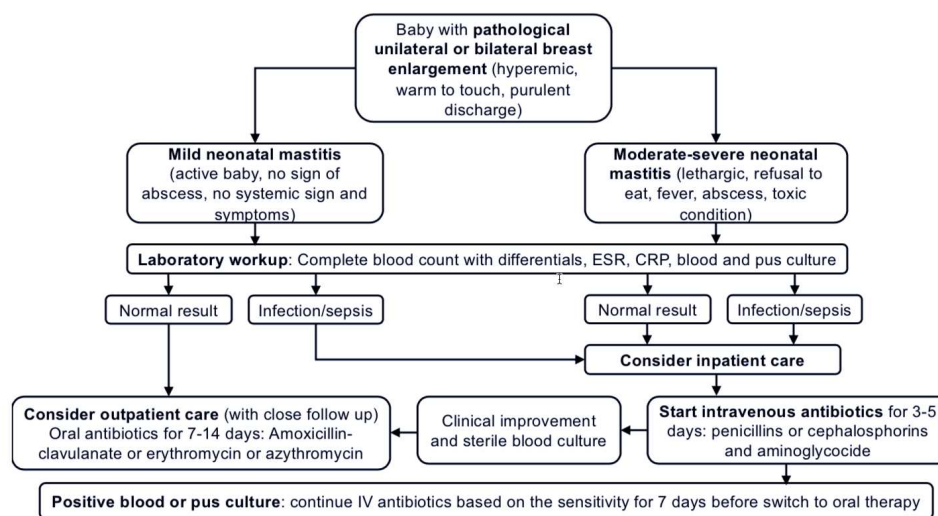


Figure 3. Suggestion of Clinical Pathway of Neonatal Mastitis in Indonesia

The uncertain clinical presentation and wide therapy variation was confirmed in the literature, Ruwaili et al⁸ mentioned that doctors have various approach in the treatment of NM, starting from no antibiotic treatment, to full sepsis workup including lumbar puncture, and course of IV antibiotics followed by abscess drainage when needed. Based on the literature review,^{7,8} we would like to suggest a clinical pathway in dealing with a patient with suspected NM (this clinical pathway was intended for healthcare system in Indonesia) Figure 3. More high-quality evidence is needed to provide better care for patients with NM, especially in Indonesia.

Every baby with suspected NM should be categorized into a mild case or moderate-severe case and undergo laboratory workup, as mentioned in figure 3. Mild NM with routine laboratory workup can be treated with an oral antibiotic, with close monitoring. Moderate-severe NM or mild NM with abnormal laboratory results should be admitted to inpatient care and received intravenous antibiotics. The clinical pathway above mentioned broad-spectrum antibiotics and should shift to sensitive antibiotic based on the culture and sensitivity result. The intravenous antibiotic course was given for 3-5 days, followed by oral antibiotics for 7-14

days. Patients with a severe abscess may benefit from open abscess incision or needle aspiration.

Conclusion

Neonatal mastitis is a rare condition with a broad clinical presentation and wide therapy variation from physicians. In general, mild NM can be treated with oral antibiotics with close monitoring; however moderate to severe NM must be admitted to received IV antibiotics. Laboratory evaluation is mandatory for all patients suspected with NM. The clinical pathway for management of NM was provided in the article.

Failure of Oral treatment is common in the case of NM, with a failure rate up to 71%. Failed treatment must receive immediate IV antibiotics. More high-quality evidence is still needed to provide better care of NM in Indonesian babies.

Acknowledgments

We would like to express our deep gratitude to the head of Ibnu Sutowo District hospital, dr. Rynna Dyanna and the head of pediatric department Dr. dr. Rosiana Marbun Sp.A for their guidance during our work in the hospital, and to all the pediatric nurses in the pediatric inpatient department.

References

1. Donaire A, Guillen J, Rajegowda B. Neonatal Breast Hypertrophy: Revisited. *Pediatr Thera*. 2016;6:3.
2. Sharma D, Murki S, Pratap T. Mastitis Neonatorum: An Interesting and Uncommon Conditions Seen in Infants. *J Neonatal Biol*. 2017;6:1.
3. Alvarez MD, Batista BA, Batista JA, Mesa EM. Incidence and Geographical Origin of Neonatal Mastitis in Havana Province, 2013-2014. *Revista Habanera de Ciencias Medicas*. 2016;15(4):589-98.
4. Peker K, Dehmen D, Peker NA, Isik A. Mastitis in Early Infancy. *J Clin Neonatol*. 2014;3(4):226-7.
5. Maria A, Dasgupta R. Family-Centered Care for Sick Newborns: A Thumbnail View. *Indian J Community Med*. 2016;41(1):11-5.
6. Oxford Centre of Evidence-Based Medicine. Levels of evidence. 2011 [accessed on October 30th, 2019]. From: <http://www.cebm.net/wp-content/uploads/2014/06/CEBM-levels-of-evidence-2.1.pdf>.
7. Masoodi T, Mufti GN, Bhat JI, Lone R, Arshi S, Ahmad SK. Neonatal Mastitis: A Clinic-Microbiological Study. *J Neonatal Surg*. 2014;3(1):2.
8. Ruwaili NA, Scolnik D. Neonatal Mastitis: Controversies in Management. *J Clin Neonatol*. 2012;1(4):207-10.
9. Ladhani S, Garbash M. Staphylococcal Skin Infections in Children: Rational Drug Therapy Recommendations. *Pediatr Drugs*. 2005;7(2):77-102.
10. Fortunov RM, Hulten KG, Hammerman WA, Mason EO Jr, Kaplan SL. Evaluation and Treatment of Community-Acquired Staphylococcus Aureus Infections in Term and Late-Preterm Previously Healthy Neonates. *Pediatrics*. 2007;120(5):937-45.
11. Davey P, Marwick CA, Scott CL, Charani E, Meneil K, Brown E, et al. Intervention to Improve Antibiotic Prescribing Practices for Hospital Inpatients (Review). *Cochrane Database of Systematic Reviews*. 2017;2. Art. No: CD003543.
12. Schulman J, Dimand RJ, Lee Hc, Duenas GV, Bennet MV, Gould JB. Neonatal Intensive Care Unit Antibiotic Use. *Pediatrics*. 2015;135:826-33.