



Extraocular Muscle Imbalance and Outcomes of Scleral Buckling Surgery for Primary Rhegmatogenous Retinal Detachment

Sadia Nawaz¹, Ayesha Babar Kawish² and Qandeel Tahir³

1. Al-Shifa Trust Eye Hospital, Rawalpindi, Pakistan
2. Al-Shifa School of Public Health, Rawalpindi, Pakistan

*Correspondence: qandeel.tahir89@gmail.com

Keywords: Muscle imbalance, restrictive motility, retinal detachment, sclera buckling surgery

doi: 10.5281/zenodo.3613460

Submitted: July 10, 2019
Accepted: November 6, 2019
Published Online: November 9, 2019

How to cite this:

Nawaz, S., Kasish, A.B. and Tahir, Q. 2020. Extraocular Muscle Imbalance and Outcomes of Scleral Buckling Surgery for Primary Rhegmatogenous Retinal Detachment. Int J Front Sci, 4(1), 40-43.



This article is open access under terms of Creative Commons Attribution License 4.0 which permits unrestricted use, distribution and reproduction in any medium provided the original work is cited properly.

Significance:

Scleral buckling for major rhegmatogenous detachment can end in severe consequences that include an increase in pressure, muscle imbalance, diplopia and post-operative restricted motility. The present study addressed presence and quantification of muscles imbalance before and after retinal surgery along with restrictive motility in different gazes. The key outcome of this study was amount of imbalance, type of deviation, macular status and restrictions in different gazes.

ABSTRACT

Objective: The objective was to study the muscle imbalance, restrictive motility in unlike gazes and the outcomes of the scleral buckling surgery for rhegmatogenous retinal detachment.

Study design: Prospective follow-up study

Settings and duration: The study was conducted at Al-Shifa Trust Eye Hospital Rawalpindi from Aug 2015 to Jan 2016.

Methodology: The patients were checked prior to surgery and two follow up visits were done afterwards. Thorough history was taken along with full orthoptic assessment and ocular motility in all four main gazes including elevation, depression, adduction and abduction. Vision, type and position of explants, site of detachment, and risk factors of detachment were also observed.

Results: A total of 48 eyes of 46 patients were taken. Mean age of the study participants was 37.16 ± 20.37 years. Horizontal, vertical and combined deviations were observed in study population. Exo deviation was most common deviation among patients. Most reported risk factors of retinal detachment included trauma, pseudophakia, aphakia and myopia. Motility limitations of all four gazes was observed and it was found out that after buckling the squint and restriction is been increased up till two months.

Conclusion: Ocular restriction among the patients was observed over a period of 2 months and it depicted that encircling with sclera buckling elicited an increase in restrictive ocular motility from pre-operative to 1 week and 2 months after surgery.

Introduction

Rhegmatogenous retinal detachment (RRD) is the most widespread form of retinal detachment, where a

retinal 'break' allows the ingress of fluid from the vitreous cavity to the sub-retinal space, resulting in retinal separation. It occurs in about 1 in 10,000 people a year. (1)

Rhegmatogenous retinal detachment is demonstrated as an urgent situation for treatment in ophthalmology. Rhegmatogenous retinal separation (RRD) is a conceivably blinding condition. (2) Retinal disease is the main reason of visual loss in developed countries. The etiology and appearance of retinal detachment in the developing and underdeveloped countries is influenced by environmental and genetic factors. (3)

North America and Europe have more frequent appearance of detachments in contrast to India and Africa. It is a state which can result in total loss of vision if left untreated. Retinal detachment is a major reason for low acuity in wealthy countries while in developing countries due to scarcity of resources its treatment is not well looked upon. (4) The main reason for late treatment is that, it presents at a very later stage therefore projection of the problem is variable in accordance with its appearance and presentation. (2)

The treatments used for retinal detachment are pars plana vitrectomy pneumatic retinopexy and conventional scleral buckling surgery. Scleral clasping comprises of setting a scleral clasp or adaptable band a bit of silicone wipe, elastic, or semi-hard plastic) around the equator of the eye to adjust any force that is being put upon the retina along these lines. This whole process relieves the traction on retina. An exterior entry point is made in the sclera and choroid to drain the sub-retinal liquid, if necessary. (4)

Scleral buckling for major rhegmatogenous detachment can end in severe consequences that include an increase in pressure, muscle imbalance, diplopia and post-operative restricted motility. (1)

It is of utmost importance to take into consideration the form and degree of changes that are brought about by retinal surgery in Outpatient Department (OPD) of Retina Clinic undergoing scleral buckling. It is also important to put a figure on the side effects and muscle limitation. Another most crucial subject is to quantify the success rate of post-operative attachments and to raise proficient professional awareness.

The present study addressed the presence and quantification of muscles imbalance before and after retinal surgery along with restrictive motility in different gazes. The key outcome of this study was

amount of imbalance, type of deviation, macular status and restrictions in different gazes.

Methodology

A prospective follow up study was conducted at Retina Clinic of Al-Shifa Trust Eye Hospital Rawalpindi. Data for the study was collected from August 2015 to January 2016. A total of 48 eyes of 46 patients were included in the study through non-probability convenient sampling. Patients included in the study presented retinal detachment and were advised scleral buckling surgery during the study duration. Patients were informed about the procedure and the follow up visits. A verbal informed consent was taken from each patient.

Silicon was used as a material for buckling surgery in all cases. All patients were programmed to be examined pre-operatively and after 1 week and 2 months post-surgery.

Anatomical reattachment of retina at 1-week post-operation follow-up visit was considered as the main outcome variable for the surgery. Detailed history including family history, history of trauma, history of strabismus when presented for surgery, eye status and previous history of surgery were included in pre-designed questionnaire.

Visual acuity of RD eye and normal eye of each patient was measured by Snellen acuity chart at six meters. Muscle imbalance was checked by cover test. Imbalance was measured as heterotropias or heterophoria. Muscle restriction was measured in four major gazes; “elevation, depression, adduction and abduction”. Restriction was labeled from 0 “normal motility” to -4.0 “fully restricted”. Details of all patients were routinely recorded for the above-mentioned variables.

Data analysis was done using SPSS version 17.0. Frequencies and percentages of categorical variables were reported, a Chi-square test was applied to find out the association between ocular motility of groups divided on basis of age while repeated measures ANOVA test was applied for comparison between pre-operative and post-operative data. P-value < 0.05 was taken as significant.

Results

A total of 48 eyes of 46 patients were included in the study. Mean age of the study participants was 37.16±20.37 years (ranging from 15-90 years). Out of the 46 patients 34 (75%) were males while 12 (25%) were females.

Eye status of patients was variable with 25 males and 10 females having Phakic eyes, 10 males and 2

females had Pseudophatic eyes and only 1 male was Aphakic.

Patients were asked about ocular history. Out of the 46 patients, 10.4% had a positive ocular family history, 29.2% had a positive history of ocular surgery, 50% had a positive history for Strabismus while 39% of the patients had history of trauma that resulted in retinal detachment. Location of retinal detachment was also taken into consideration; figure 1 shows the location of detached retina in all cases that were included in the study.

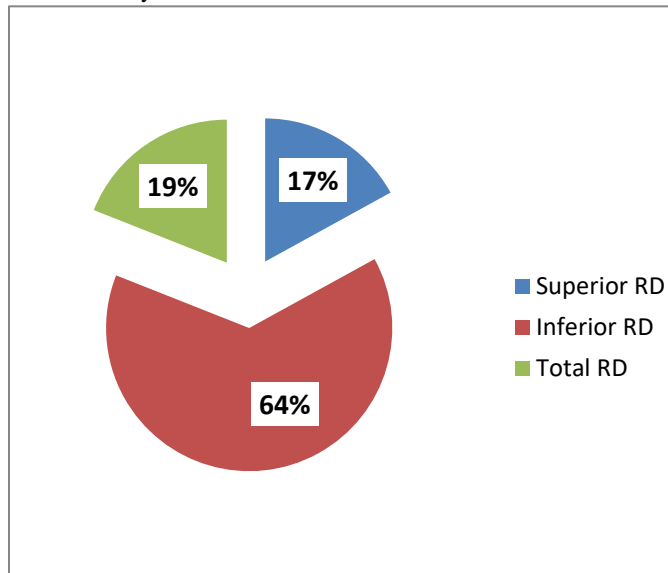


Figure 1: Location of Detached Retina

Ocular restriction was observed in 36 out of 48 eyes. Patients included in the study presented variety of combinations in restrictions. Table 1 shows the globe motility of patients.

Table 1: Mode of Ocular Restriction

Mode of Restriction	Frequency (n)	%
No Restriction	12	25
Restriction in One Gaze	08	16.7
Restriction in Two Gazes	21	43.8
Restriction in 3 Gazes	07	14.6
Total	48	100

Ocular motility restriction was also assessed in 2 groups; group 1 had individuals from ages 15-40 years while group 2 had individuals from ages 41-90 years. Statistical analysis showed that patients in younger age group 22 (47.8%) had more tendencies to develop ocular restriction in different gazes than patients of

older age 14 (30.4%). However, the results were not statistically significant with a p-value > 0.05.

Macular status was categorized as "ON or OFF" on 1-week post-operative visit. Fig 1 shows the detailed results. Visual acuity was recorded on all three visits. Frequencies revealed that visual acuity improved in patients in which macula was attached after scleral buckling. Fig 2 depicts the detailed acuities in the study population. Exo-deviation was shown by majority of patients according to the cover test results.

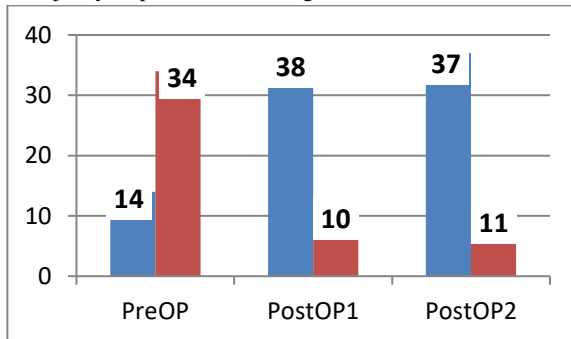


Figure 2: Macular Status among Population on all Three Follow-ups

Ocular restriction among the patients was observed over a period of 2 months. ANOVA statistics revealed statistically significant results between pre, 1 week and 2 months post-operation values. Post hoc Bonferroni correction depicted that encircling with sclera buckling elicited an increase in restrictive ocular motility from pre-operative to 1 week and 2 months after surgery (p-value 0.001). (Table 2)

Table 2: Ocular Restriction in Different Gazes on First & Second Post-OP F/U

Gaze under Observation	Pre-OP Mean ±SD	Post-OP 1 Mean ±SD	Post-OP 2 Mean ±SD	N	F Ratio	df	p-value
Elevation	0.00±0.00	-1.02±1.18	-1.32±1.30	48	5.57	2	0.00
Depression	0.00±0.00	-0.34±0.85	-0.33±0.87	48	4.79	2	0.013
Adduction	0.00±0.00	-0.19±0.45	-0.27±0.011	48	5.18	2	0.009
Abduction	0.00±0.00	-0.76±1.06	-1.05±1.24	48	16.72	2	0.00

Discussion

Scleral buckling is a method used to connect retina by indenting sclera with surrounding explants. The present study emphasized on estimating muscle imbalance, restrictive motility in different gazes and outcomes of scleral buckling surgery for retinal detachment.

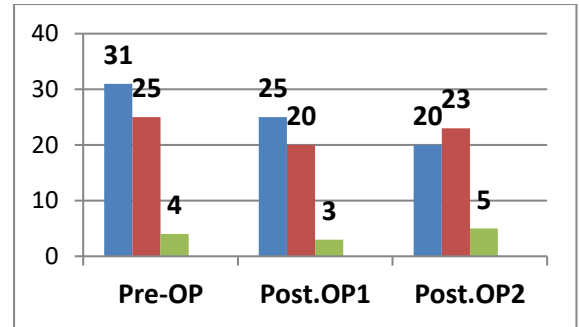


Figure 3: Visual Outcomes among Population on all Three Follow-ups

There are several mechanical reasons for postoperative muscles imbalance following buckling surgery. The most frequently addressed reasons include globe shape deformation by the collective effect of explants, damage to the extraocular muscles by traction sutures, reduction of buckling material, Tenon’s capsule scarring from periocular anesthesia and orbital fat. (5, 6, 7, 8, 9)

The differences seen in total deviation in the area of maximal deviation among our cohorts deduced that of the small number of different mechanisms, that participate in development of strabismus, the buckle if present increases the deviation in the extreme of gazes. The cause of this may be the tethering effect of buckling material on the vector forces of the muscles with which they are in direct contact, and this effect is multiplied in extremes of gaze.

In our study, all cases were treated with full 360 encirclement and the 360 band was in contact with all the four muscles, as the buckle was not removed in any case. The deviation horizontal, vertical and combined were present and restrictions of all four major gazes elevation, depression, adduction and abduction were seen and increased somewhat in two months duration. Table 2

Some authors have suggested that post-operative muscles imbalance induced by the buckling is temporary (10, 11), however the limitations of our study was that follow up period was too short to infer any such conclusion.

Anatomical success rates are generally higher at specialized clinics in developed countries than in the third world countries. Comer and his colleagues reported a final success rate of 97.4% at Cambridge UK 29, but in current study the success rate was about 79.1%. (12)

A study conducted in Iran by Ahmadieh H and his colleagues and documented the visual outcomes as, 44% achieved visual acuity better than 6/60. (11)

Another study conducted in Zaire, out of 34 eyes that were reattached at the last clinic visit, 21 (62%)

achieved a vision of 6/60 or better but that represents only 27% of the total number of eyes operated. One more study in Andhra Pradesh, 65% of eyes achieved 6/60 or better postoperatively. Among successfully re-attached eyes, 80% could see at least 6/60 and in current study under discussion 47.91 % of the study population achieved 6/60 to 6/36 and about 10.41% achieved 6/24 or better. (13)

In this study, the risk factors of retinal detachment are also studied. Trauma was the biggest risk factor, others were pseudophakia, aphakia, and myopia. (14) Another study stated that trauma is an imperative cause of RD in Africa. Trauma was considered to contribute to the detachment in 30% of eyes in South Africa and 23% in Zaire. In Minnesota trauma was responsible for 7% of detachments and in Japan blunt trauma accounted for only 1.6%. (8)

Another study suggested that male sex, young age, myopia, and increased axial length were all correlated with an increased risk of retinal detachment. (10)

Conclusion

Ocular restriction among the patients was observed over a period of 2 months and it depicted that encircling with sclera buckling elicited an increase in restrictive ocular motility from pre-operative to 1 week and 2 months after surgery

Limitations of Study

- The duration of both study and follow-up was very short.
- Sample size was small.
- Resources were limited.

Acknowledgments

The authors wish to extend their thanks to all those who helped in data collection.

Funding Resources

None to declare.

Conflict of interest: Authors do not have any conflict of interest to declare.

Disclosure: None

Human/Animal Rights: No human or animal rights are violated during this study.

References:

1. Tsao S. Vitrectomy for Retinal Detachment Repair. CSurgeries. 2017.
2. "Visual Impairment and Blindness". World Health Organization. N.P., 2016. Web. 14 Mar. 2016.
3. NicolasFeltgen,PeterWalter."RhegmatogenousRetinal Detachmentâ€"An Ophthalmologic Emergency". Deutsches Ã„rzteblatt International 111.1-2 (2014): 12. Web. 14 Mar. 2016.
4. Khan MT, Jan S, Karim S, Iqbal S, Saeed N. Outcome of sclera buckling procedures for primary rhegmatogenous retinal detachment. J Pak Med Assoc. 2010; 60(9):754-7.
5. Farr AK, Guyton DL. Strabismus after retinal detachmentsurgery. Curr Opin Ophthalmol 2000; 11: 207-210.
6. Salama H, Farr AK, Guyton DL. Anaesthetic myotoxicity as a cause of restrictive strabismus after scleral buckling surgery. Retina 2000; 20: 578-582.
7. Ahmadi H, Entezari M, Soheilian M, Azarmina M, Dehghan MH, Mashayekhi A, et al. Factors influencing anatomic and visual results in primary scleral buckling. Eur J Ophthalmol 2000; 10: 153-9
8. Mistry D, Charteris D, Yorston D, Siddiqui M, Campbell H, Murphy A et al. The Epidemiology and Socioeconomic Associations of Retinal Detachment in Scotland: A Two-Year Prospective Population-Based Study. Investigative Ophthalmology & Visual Science. 2010;51(10):4963.
9. Asaminew T, Gelaw Y, Bekele S, Solomon B. Correction: Retinal Detachment in Southwest Ethiopia: A Hospital Based Prospective Study. PLoS ONE. 2013;8(10).
10. Rabinowitz R, Velez F, Pineles S. Risk factors influencing the outcome of strabismus surgery following retinal detachment surgery with scleral buckle. Journal of American Association for Pediatric Ophthalmology and Strabismus. 2013;17(6):594-597.
11. Wong V, Kasbekar S, Young J, Stappeler T, Marsh I, Durman J. The effect of scleral exoplant removal on strabismus following retinal detachment repair. Journal of American Association for Pediatric Ophthalmology and Strabismus. 2011;15(4):331-333.
12. Comer MB, Newman DK, George ND, Tom BD, Martin KR, Moore AT. Who should manage primary retinal detachments? Eye (Lond) 2000;14: 572-8.
13. Mistry D, Charteris D, Fleck B, Campbell H, Singh J. The epidemiology of rhegmatogenous retinal detachment: geographical variation and clinical associations. British Journal of Ophthalmology. 2009;94(6):678-684.
14. Sönmez K, Keleş A. Macular Buckling Surgery for Retinal Detachment Associated with Macular Hole in High Myopia Eye. Türk Oftalmoloji Dergisi. 2017;351-354.