

## APPLICATION OF DIGITAL TOMOSYNTHESIS IN DIAGNOSING SPINAL TUBERCULOSIS – FIRST CLINICAL EXPERIENCE IN UKRAINE

**Olena Sharmazanova**

Department of Radiology  
Kharkiv Medical Academy of Post-graduate Education  
58 Amosova str., Kharkiv, Ukraine, 61176  
olena.sharm@gmail.com

**Nataliya Deresh**

Department of Radiology  
Diagnostic Centre «Omega»  
10 Maxymovycha str., Kyiv, Ukraine, 03022  
nataalka.deresh@gmail.com

**Larisa Urina**

Department of Radiology  
Children's Clinical Hospital № 3 of Solomyansky District  
21 Volynska str., Kyiv, Ukraine, 03151  
larisaurina49@gmail.com

**Yuriy Kovalenko**

Center of X-ray technologies of the Association of Radiologists of Ukraine,  
9 Dorogozhytska str., Kyiv, Ukraine, 04112  
aru-ua@ukr.net

---

### Abstract

Diagnosis of tuberculous spondylitis is based on the comparison of clinical-laboratory, bacteriological data and radiological methods. Digital tomosynthesis is a new method of X-ray diagnostics for performing with high-resolution limited-angle tomography at short-pulsed exposures in one pass of the tube with reconstruction of several hundred longitudinal sections of the research object without superposition of tissues. Possibilities of tomosynthesis are studied for various clinical situations.

Aim of research. To study and apply the possibilities of digital tomosynthesis in the diagnosis of tuberculous spondylitis, conduct a comparative analysis with other radiological methods.

Materials and methods. Digital tomosynthesis was performed for 95 patients with various spine diseases (select group 8.4 % with tuberculous spondylitis) at the domestic digital roentgen-diagnostic complex with the mode of digital tomosynthesis after performing digital projectional radiography of spine.

Results and discussion. The benefits of tomosynthesis were shown and a comparative analysis with other visualization methods in the diagnosis of spondylitis was performed. Cases of the first clinical application of the method in Ukraine were demonstrated.

Conclusion. Digital tomosynthesis of the spine is a new promising diagnostic tool by which you can obtain qualitative spine images in the form of numerical thin sections with no exaggeration effect. Results are comparable to CT data for detecting bone destruction at lower radiation load levels. Digital tomosynthesis provides better visualization of the small joints of the spine and the ability to evaluate each anatomical element of the vertebra at different depths, helps to detect pulmonary manifestation of tuberculosis.

**Keywords:** radiography, digital tomosynthesis, magnetic resonance imaging, computed tomography, spondylitis.

DOI: 10.21303/2504-5679.2018.00735

© Olena Sharmazanova, Nataliya Deresh, Larisa Urina, Yuriy Kovalenko

### 1. Introduction

Diagnosis of tuberculous spondylitis is based on the comparison of clinical-laboratory, bacteriological data and radiological methods [1]. Radiological signs are important not only for diag-

nostics, but for monitoring the dynamics and evaluation of effectiveness of the treatment. Early diagnosis of tuberculous spondylitis is crucial for effective treatment [2].

X-ray of the spine (projectional radiography) in two projections for a long time remained the basic method of diagnosis of spondylitis. However, due to the low sensitivity of 15–70 % [3], and some physical limitations of the method, it was replaced by the modern cross-sectional imaging methods of diagnosis: computer and magnetic resonance imaging (CT, MRI). They demonstrated a significant advantage in the diagnosis of spondylitis, in comparison with radiography, particularly due to the excellent three-dimensional visualization of any anatomical region of the spine and a multi-parametric morphological evaluation of all tissues involved in the inflammatory process.

The main benefit of MRI was the detection of spondylitis in the pre-roentgenological sub-clinical stage of the disease, before the appearance of bone destruction at the stage of bone marrow infiltration, as well as in evaluating of the process spreading to soft tissues, spinal channel and spinal structures with a sensitivity of 100 % and a specificity of 80 % [4]. However, this method still remains expensive and hardly accessible.

Due to the lack of an abstract effect, high spatial and contrast ability, CT gives us a complete access to see bone changes and destructive changes of the spine under spondylitis (severity and localization of lesions, the presence of cavities and sequestering, the full formation of the bone block or residual cavity, as well as the presence of Sequestrum formation, gas etc.) with a sensitivity of 98–100 % [4]. The disadvantage of CT remains a large radiation dose level, which is 5–10 mSv per one anatomical part of the spine. That requires some limitations for frequent use to control the effectiveness of treatment, as well as in paediatrics.

Digital tomosynthesis (DT) is a new method of X-ray diagnostics for performing with high-resolution limited-angle tomography at short-pulsed exposures in one pass of the tube with reconstruction of several hundred longitudinal sections of the research object [5]. DT avoids one of the main drawbacks of the X-ray method – the superposition of tissues (total projective overlay) and allows getting the huge number of images that can be viewed in the form of a video loop. In this case, the spatial resolution of the image in the plane of the cut at tomosynthesis is higher than in the case of CT. Radiation dose levels of DT comparable with projectional radiography. DT has an intermediate position between projective X-rays and CT, which allows considering it as a potential low-dose technique, an alternative to CT imaging [6, 7]. Possibilities of tomosynthesis are studied for various clinical situations, particularly for the detection of vascular, head and neck, breast, thoracic and musculoskeletal system pathologies [7]. In 2016–2017, foreign publications on the diagnostic capabilities of digital tomosynthesis for the visualization of bone and joint pathology appeared. They were mostly used in rheumatology for the diagnosis of rheumatoid arthritis, ankylosing and infectious spondylitis and traumatic bone lesions [8, 9]. In our country, the technique has not yet received a wide clinical use, with the exception of the mammographic direction [10] and still requires clinical examination.

## 2. Aim of research

Study and apply the possibilities of digital tomosynthesis in the diagnosis of tuberculous spondylitis, conduct a comparative analysis with other radiological methods.

## 3. Materials and methods

Digital tomosynthesis was performed for 95 patients with various spine diseases, of which a group of 8 cases (8.4 %) was selected for research with the diagnosis of tuberculous spondylitis on the basis of bacteriological and clinical-radiological comparison. In equal proportions, men and women are 1:1, 25 to 63 years old (44±19 on average). The tests were performed at the domestic digital roentgen-diagnostic complex with the mode of digital tomosynthesis after performing

digital projectional radiography of spine. Spine examinations were performed at anode voltage of 90–100 kV and 100–120 mAs in one projection, with the radiation dose level on the patient did not exceed 3.0 mSv. For each DT examination 256 images were taken in 1 mm step, viewed as a video loop with the possibility of post processing on standard DICOM viewers.

Selected criteria of diagnostics:

1. Detection and evaluation of bone destruction.
2. Evaluation of the intervertebral disc.
3. Detection and evaluation of paravertebral abscesses.
4. Evaluation of distribution in the vertebrate channel.

Digital radiographs, digital tomosynthesis, delivered CT and MRI spinal column images were compared.

#### 4. Results and discussion

Tuberculous spondylitis was defined as mono-segmental lesion (two adjacent vertebrae and intervertebral disk) in 75 % (n=6) cases and polysegmental in 25 % (n=2). All patients were already at the spondylitic stage of the disease with bone destruction 100 % (n=8). The tuberculosis process was localized in the thoracic spine (25 % n=2), thoraco-lumbar (25 % n=2), lumbar (50 % n=4). The predominant productive type of inflammation was 62.5 % (n=5). The main features of the injury were contact and fragmentary destruction of the vertebral bodies, lowering the height of the vertebral bodies and wedge-shaped deformation, lowering the height and structural changes in the intervertebral disks.

The results of detection of bone destruction on the DT appeared to be higher than radiographic data and comparable to CT scan: radiography 62.5 % (n=5), DT 100 % (n=8), CT 100 % (n=8). Sequestrum formation detected DT 12.5 % (n=1) and CT 25 % (n=2), not seen on radiography. With the help of DT, thin destruction of the cortical layer of vertebrae on the lateral surface under the spine ligament was detected with polysegmental lesion (12.5 %, n=1), which wasn't visible on the X-ray (**Fig. 1**).

Disc anomalies: decrease the height of the intervertebral disc – results are comparable to all methods (**Fig. 2**). Structural disks (signal abnormality, density or contrast enhancement) – X-ray and DT-0 %, CT 25 % (n=2), MRI 100 % (n=8).

In 75 % (n=7) of the study group paravertebral abscesses were detected (radiography of 25 % (n=2), DT 62.5 % (n=5), CT 75 % (n=7), MRI 75 % (n=7).

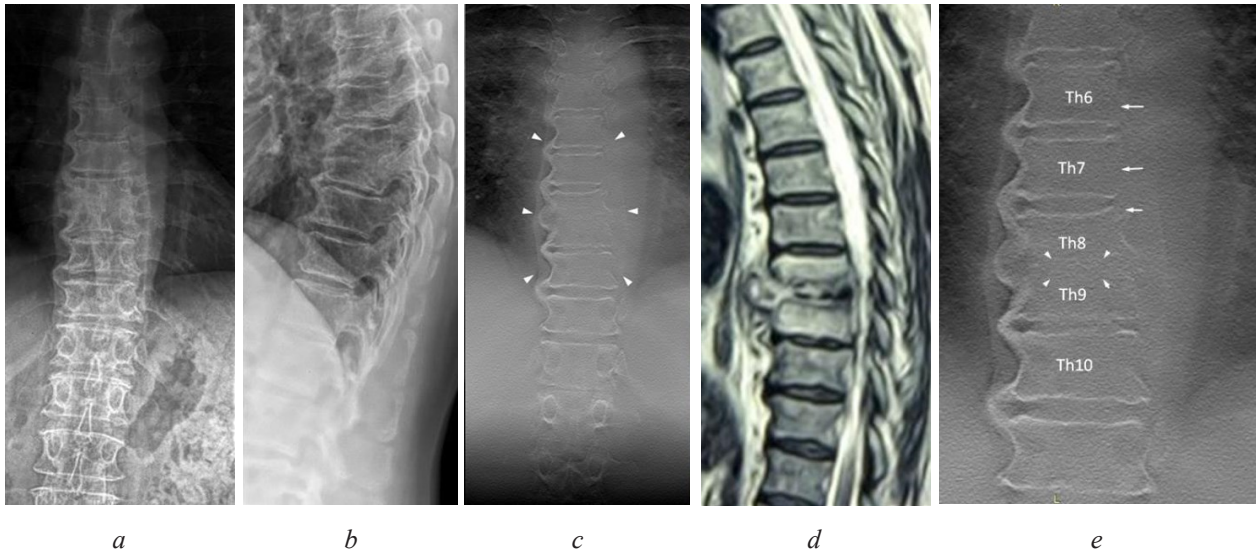
Digital tomosynthesis allowed detecting a small paravertebral abscess and more accurately estimating the length of abscesses, as compared to the spine radiography. MRI has advantages in the diagnosis of the spread of epidural abscess and in the evaluation of vertebral channel stenosis.

In the case of 1 patient (12.5 %), with the help of digital tomosynthesis of thoracic cavity, in addition to spondylitis in Th12-L1, miliary dissemination in lungs (size of nodules from points to 2 mm) and decay were revealed. Due to the possibility of research at different depths, it was clearly established segmental localization of the cavity of decay (in S6 right pulmonary subpleural) (**Fig. 3**).

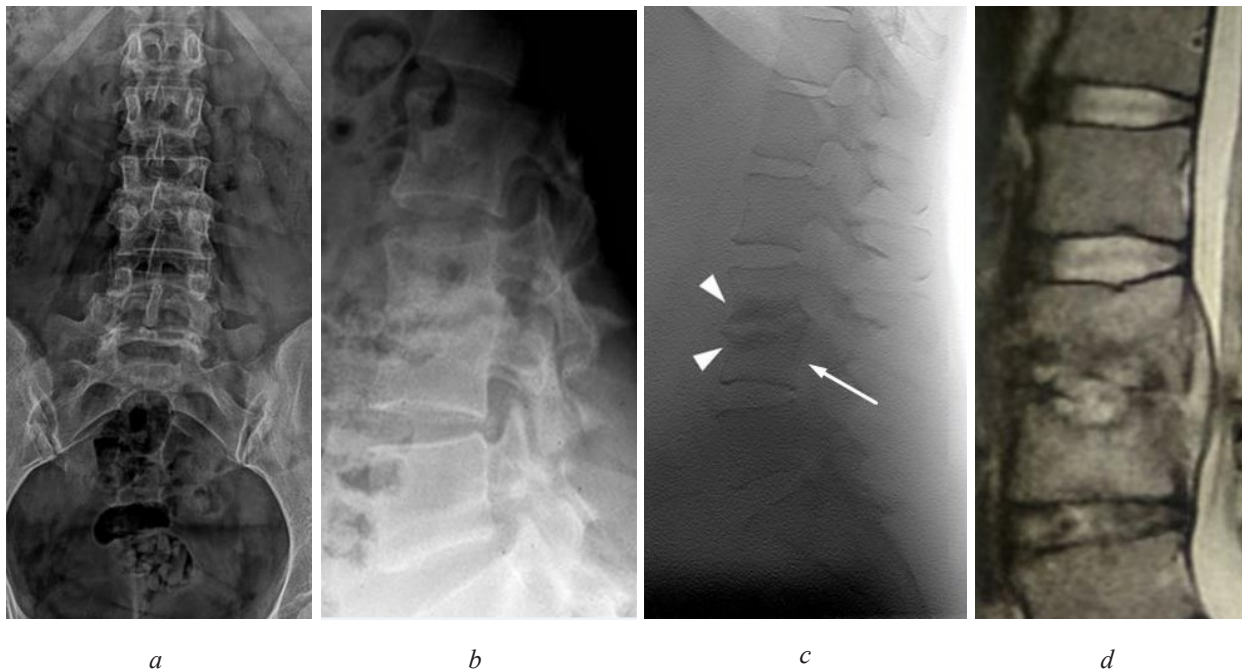
The advantage of DT was a clear visualization of different parts of the spine without an exaggerated effect throughout the depth (**Fig. 4**). It made possible to more accurately assess the state of articular facets, their integrity, the presence of erosions or osteophyte formation, or normal appearance (**Fig. 5**). Evaluation of small joints of the spine on the radiograph 25 % (n=2), DT 87.5 % (n=7), CT 100 % (n=8).

Limitations of the DT method: the image of the thoracic spine was more precise and diagnostically informative, as opposed to the image of the lumbar spine. Obviously, this is due to the need to select and optimize scan modes properly (kV, mAs).

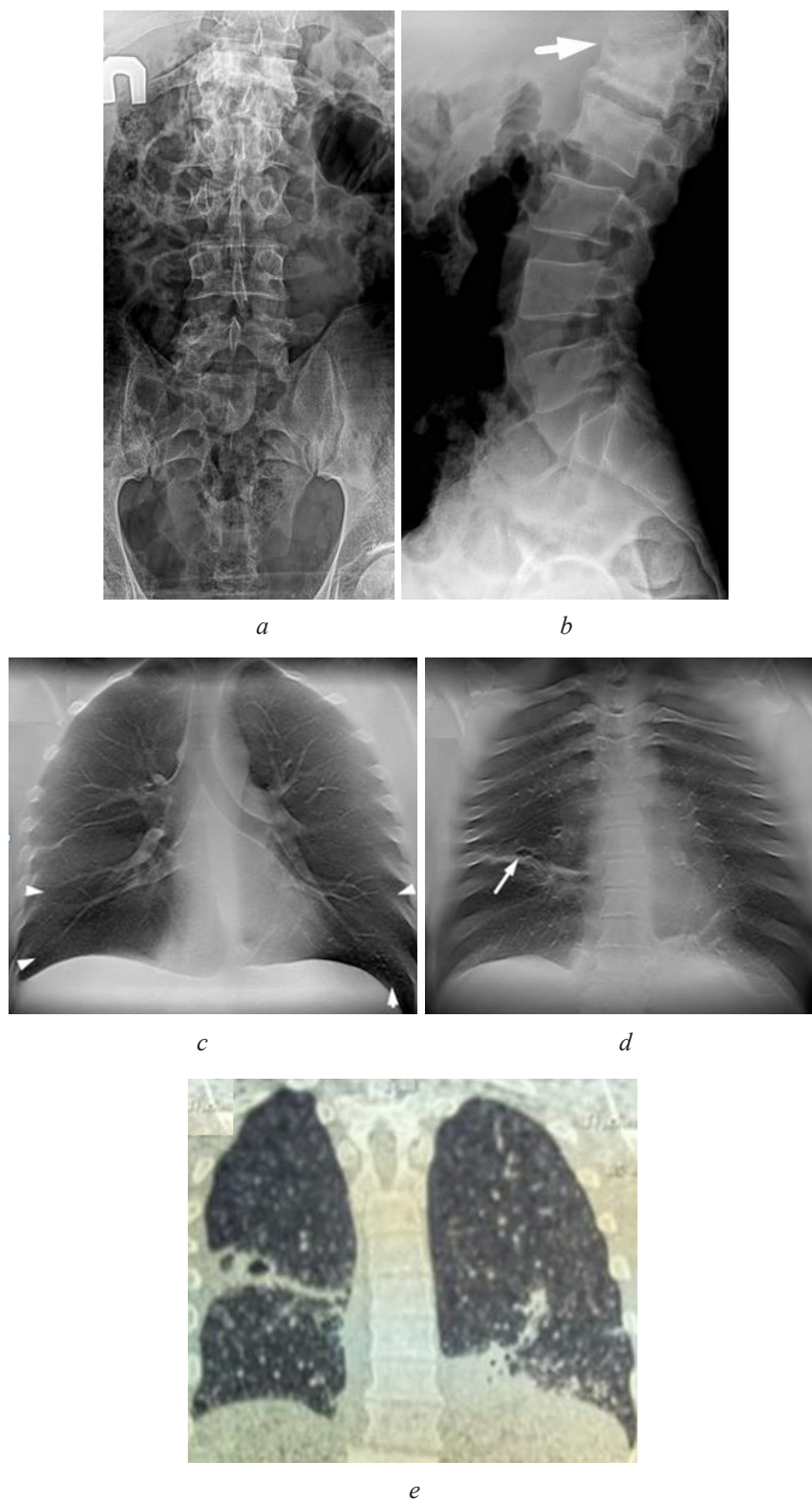
## Clinical case reports:



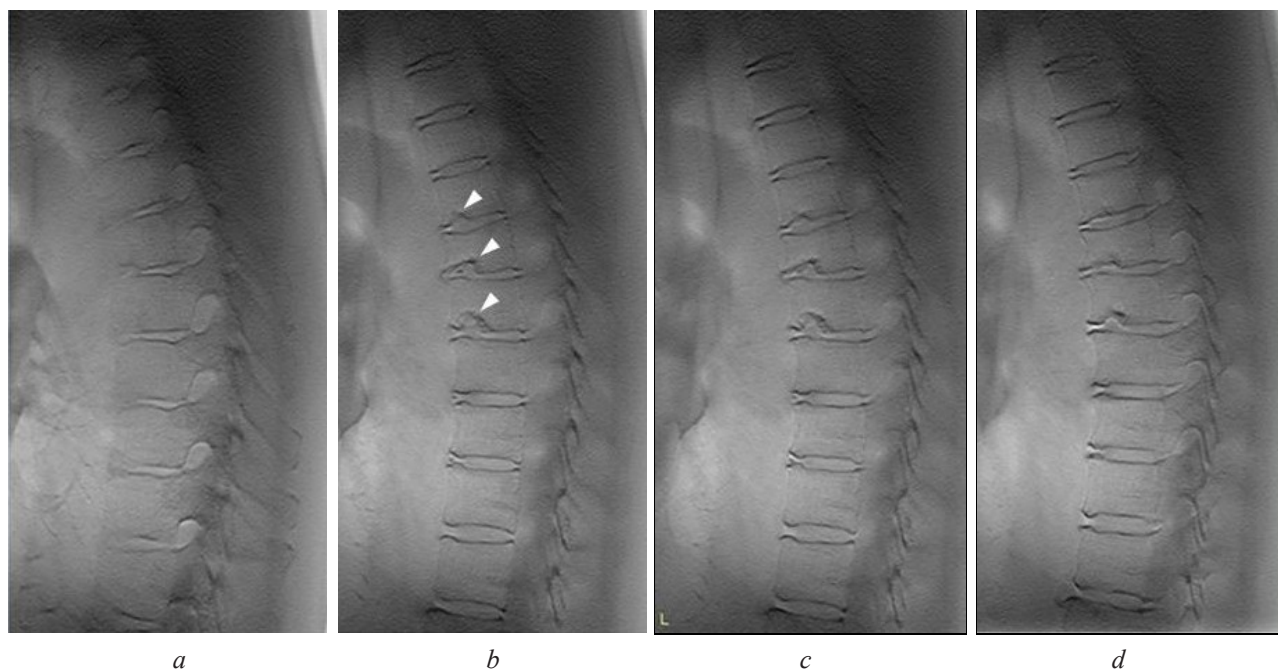
**Fig. 1.** Female, 63 y.o., with tuberculous spondylitis Th8–Th9: *a* – digital X-ray of the spine, direct projection; *b* – digital X-ray of the spine, lateral projection; *c* – digital tomosynthesis (arrowheads marked with paravertebral abscess); *d* – MRT T2W sag; *e* – enlarged digital tomogram Th6–Th10 (the arrowheads indicate the destroyed Th8–Th9 end plates through a disk, the arrows denote the destruction of the cortical layer and the corners on the left lateral surface of Th7 and Th6 vertebrae, subligamentous spread)



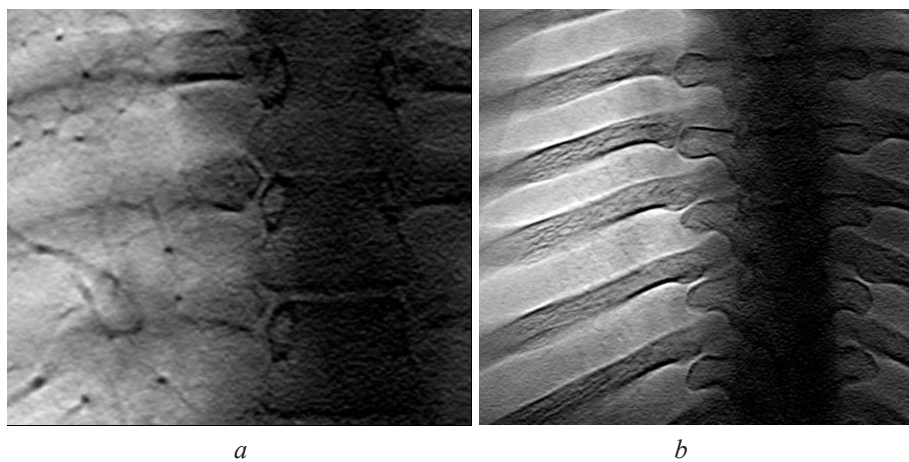
**Fig. 2.** Male, 40 y.o., with tuberculous spondylitis L3–L4: *a* – digital X-ray of the spine, direct projection; *b* – digital X-ray of the spine, lateral projection; *c* – digital tomosynthesis of the spine (the heads of the arrows indicate the destroyed end plates of the vertebrae L3–L4 with increased subchondral sclerosis and decrease the height of the intervertebral disc, arrow – subligamentous abscess); *d* – MRI T2W sag.



**Fig. 3.** Male, 39 y.o., with tuberculous spondylitis Th12-L1 and pulmonary tuberculosis: *a* – digital X-ray of the spine in the direct projection; *b* – digital X-ray of the spine in the lateral projection (the arrow marked the affected segment of the spine); *c* – digital tomosynthesis of the chest (the heads of the arrows are marked by the miliar dissemination of the lungs); *d* – digital tomosynthesis of the chest (the arrow is the cavitation in S6); *e* – CT image



**Fig. 4.** Female, 53 y.o., with thoracic osteochondrosis. Digital tomosynthesis of the thoracic spine in lateral projection: *a* – right parasagittal view; *b* – right sagittal view (the heads of the arrows are marked by multiple cartilage nodes of Shmorl, no bone destruction); *c* – left sagittal view; *d* – left parasagittal view



**Fig. 5.** Female, 25 y.o. Digital tomosynthesis of the thoracic spine, normal appearance costovertebral joints: *a* – rib's neck and tubercle, processus transversus; *b* – rib's head

## 5. Conclusions

1. Digital tomosynthesis of the spine is a new promising diagnostic tool by which you can obtain qualitative spine images in direct or lateral projections, in the form of numerical thin sections with no exaggeration effect.

2. DT can be detected through inter-disc and subligamentous lesions, accompanied by bone destruction and formation of paravertebral abscesses. DT provides better visualization of the small joints of the spine and the ability to evaluate each anatomical element of the vertebra at different depths.

3. The DT results are comparable to CT data for detecting bone destruction at lower radiation load levels, indicating the prospect of using DT in the absence or replacement of CT, as well as for multiple control during treatment.

4. DT can detect pulmonary manifestation of tuberculosis, even miliar foci, detect and localize cavitation.

5. The DT method needs to be finalized to obtain better quality images by optimally selecting the parameters of the survey.

---

### References

- [1] Holka, G. G., Vesnin, V. V., Fadeev, O. G., Burlaka, V. V., Oliynyk, A. O., Garkusha, M. A. (2017). Zagalni pryncypy diagnostyky tuberkulosnogo spondylitu. *Travma*, 8 (3). Available at: <http://www.mif-ua.com/archive/article/44806>
- [2] Skoura, E., Zumla, A., Bomanji, J. (2015). Imaging in tuberculosis. *International Journal of Infectious Diseases*, 32, 87–93. doi: <http://doi.org/10.1016/j.ijid.2014.12.007>
- [3] Chen, C.-H., Chen, Y.-M., Lee, C.-W., Chang, Y.-J., Cheng, C.-Y., Hung, J.-K. (2016). Early diagnosis of spinal tuberculosis. *Journal of the Formosan Medical Association*, 115 (10), 825–836. doi: <http://doi.org/10.1016/j.jfma.2016.07.001>
- [4] Jung, N.-Y., Jee, W.-H., Ha, K.-Y., Park, C.-K., Byun, J.-Y. (2004). Discrimination of Tuberculous Spondylitis from Pyogenic Spondylitis on MRI. *American Journal of Roentgenology*, 182 (6), 1405–1410. doi: <http://doi.org/10.2214/ajr.182.6.1821405>
- [5] Dobbins, J. T., Godfrey, D. J. (2003). Digital x-ray tomosynthesis: current state of the art and clinical potential. *Physics in Medicine and Biology*, 48 (19), 65–106. doi: <http://doi.org/10.1088/0031-9155/48/19/r01>
- [6] Shutikhina, I. V., Tsybul'skaya, Y. A., Smerdin, S. V., Selyukova, N. V., Baturin, O. V., Kokov, L. S. (2016). Capabilities of Combined Application of Multislice Linear Digital X-ray Tomography and Ultrasound Examination in Diagnosing Spinal Tuberculous Lesion. *Sovremennye Tehnologii v Medicine*, 8 (4), 82–91. doi: <http://doi.org/10.17691/stm2016.8.4.11>
- [7] Machida, H., Yuhara, T., Tamura, M., Ishikawa, T., Tate, E., Ueno, E. et. al. (2016). Whole-Body Clinical Applications of Digital Tomosynthesis. *RadioGraphics*, 36 (3), 735–750. doi: <http://doi.org/10.1148/rg.2016150184>
- [8] Ha, A. S., Lee, A. Y., Hippe, D. S., Chou, S.-H. S., Chew, F. S. (2015). Digital Tomosynthesis to Evaluate Fracture Healing: Prospective Comparison With Radiography and CT. *American Journal of Roentgenology*, 205 (1), 136–141. doi: <http://doi.org/10.2214/ajr.14.13833>
- [9] Jiao, D., Yang, H.-S., Yang, D., Tian, W., Wang, H., Ji, H. (2016). Application of digital tomosynthesis in diagnosing spinal tuberculosis. *Clinical Imaging*, 40 (3), 461–464. doi: <http://doi.org/10.1016/j.clinimag.2015.11.003>
- [10] Dykan, I. M., Bozhok, S. M., Gurando, A. V., Kozarenko, T. M. (2017). Cyfrovyyi tomosyntezy u diagnostyky zakhvoruvan grudnykh zaloz. *Health Of Woman*, 8 (124), 108–115.
- [11] Sharma, G., Ghode, R. (2016). Tubercular Spondylitis: Prospective Comparative Imaging Analysis on Conventional Radiograph and MRI. *International Journal of Anatomy, Radiology and Surgery*, 5 (3), 41–46.
- [12] Rivas-Garcia, A., Sarria-Estrada, S., Torrents-Odin, C., Casas-Gomila, L., Franquet, E. (2012). Imaging findings of Pott's disease. *European Spine Journal*, 22 (4), 567–578. doi: <http://doi.org/10.1007/s00586-012-2333-9>
- [13] Simoni, P., Gérard, L., Kaiser, M.-J., Ribbens, C., Rinkin, C., Malaise, O., Malaise, M. (2015). Use of Tomosynthesis for Detection of Bone Erosions of the Foot in Patients With Established Rheumatoid Arthritis: Comparison With Radiography and CT. *American Journal of Roentgenology*, 205 (2), 364–370. doi: <http://doi.org/10.2214/ajr.14.14120>
- [14] Joo, Y. B., Kim, T.-H., Park, J., Joo, K. B., Song, Y., Lee, S. (2016). Digital tomosynthesis as a new diagnostic tool for evaluation of spine damage in patients with ankylosing spondylitis. *Rheumatology International*, 37 (2), 207–212. doi: <http://doi.org/10.1007/s00296-016-3627-8>

- [15] Sechopoulos, I. (2013). A review of breast tomosynthesis. Part II. Image reconstruction, processing and analysis, and advanced applications. *Medical Physics*, 40 (1), 014302. doi: <http://doi.org/10.1118/1.4770281>
- [16] Siu, A. L. (2016). Screening for Breast Cancer: U.S. Preventive Services Task Force Recommendation Statement. *Annals of Internal Medicine*, 164 (4), 279–296. doi: <http://doi.org/10.7326/m15-2886>
- [17] Lang, K., Andersson, I., Zackrisson, S. (2014). Breast cancer detection in digital breast tomosynthesis and digital mammography – a side-by-side review of discrepant cases. *The British Journal of Radiology*, 87 (1040), 20140080. doi: <http://doi.org/10.1259/bjr.20140080>
- [18] Xia, Q. (2007). Dedicated Computed Tomography of the Breast: Image Processing and Its Impact on Breast Mass Detectability. 4.
- [19] Smith, A. P., Niklason, L., Ren, B., Wu, T., Ruth, C., Jing, Z.; Astley, S., Brady, M., Rose, C., Zwiggelaar, R. (Eds.) (2006). Lesion Visibility in Low Dose Tomosynthesis. *Digital mammography: 8th international workshop, IWDM 2006*. Manchester, New York: Springer, 160–166. doi: [http://doi.org/10.1007/11783237\\_23](http://doi.org/10.1007/11783237_23)
- [20] US Food and Drug Administration (2011). Selenia Dimensions 3D System – P080003.
- [21] Dobbins, J. T., McAdams, H. P. (2009). Chest tomosynthesis: Technical principles and clinical update. *European Journal of Radiology*, 72 (2), 244–251. doi: <http://doi.org/10.1016/j.ejrad.2009.05.054>
- [22] Bertolaccini, L., Viti, A., Tavella, C., Priotto, R., Ghirardo, D., Grosso, M., Terzi, A. (2015). Lung cancer detection with digital chest tomosynthesis: first round results from the SOS observational study. *Annals of Translational Medicine*, 3 (5), 67. doi: <http://doi.org/10.3978/j.issn.2305-5839.2015.03.41>