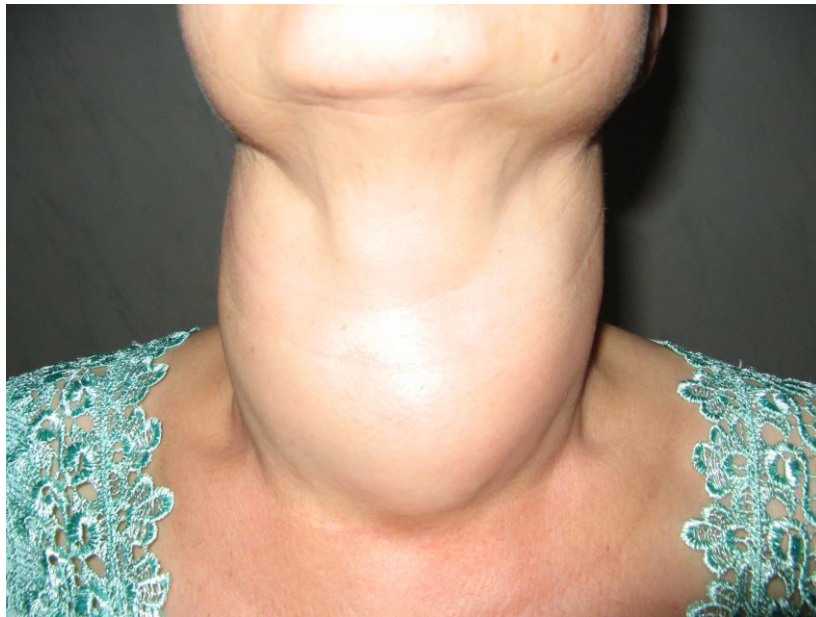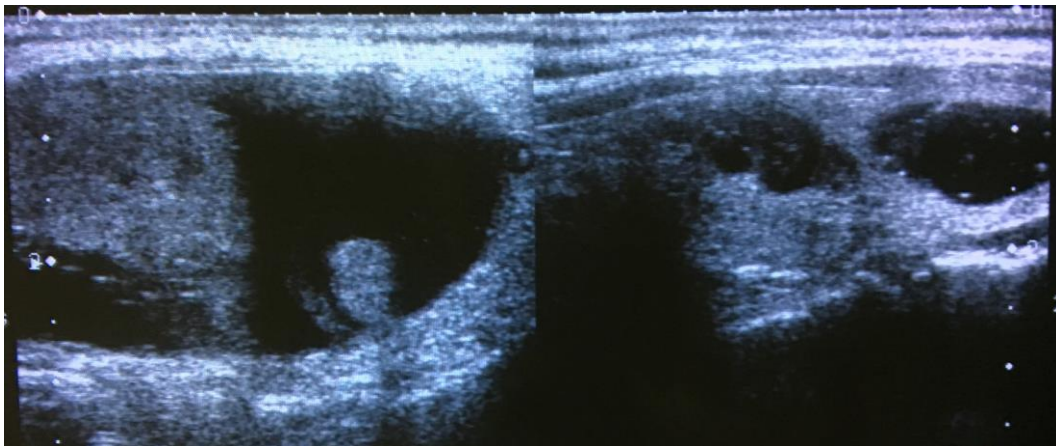
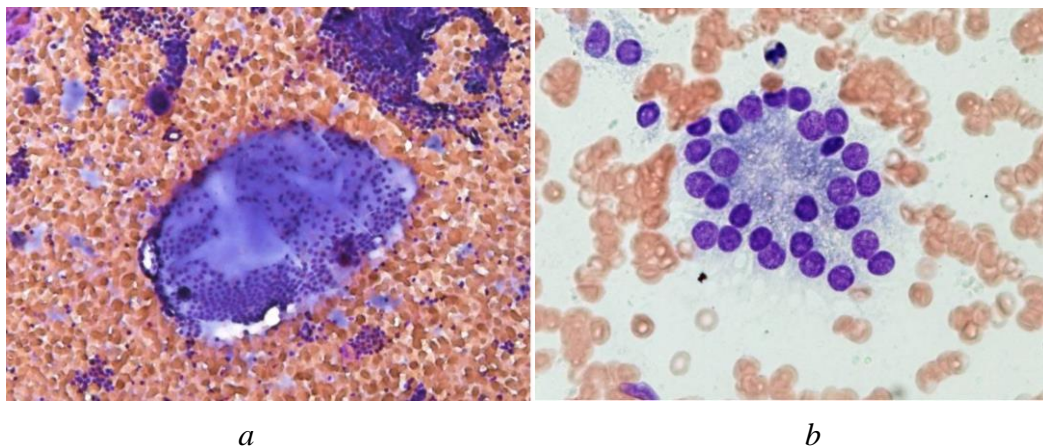




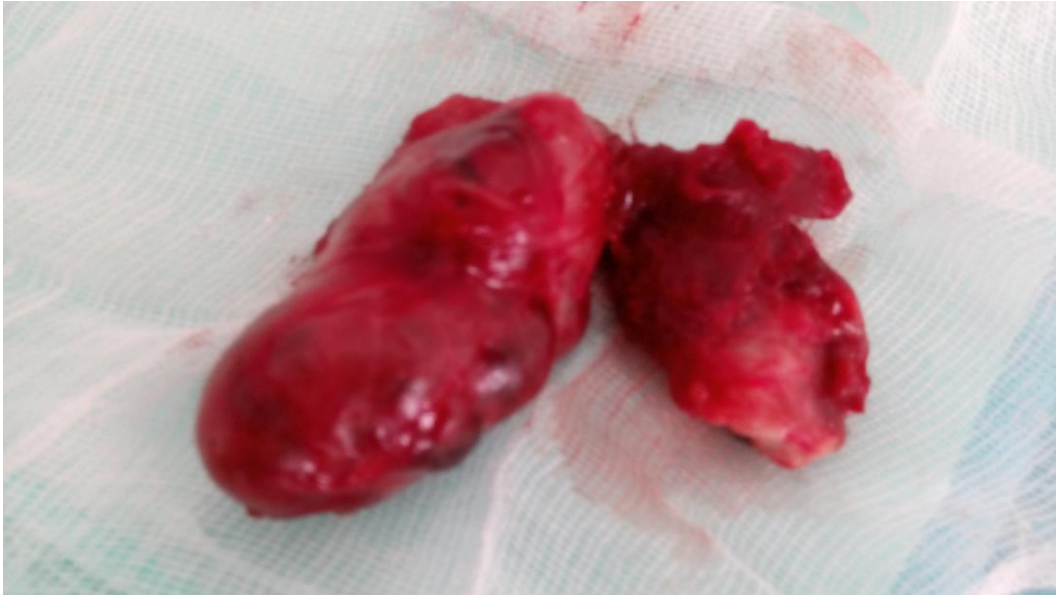**Fig. 1.** The patient with the multinodular goiter, grade 2, euthyroid state



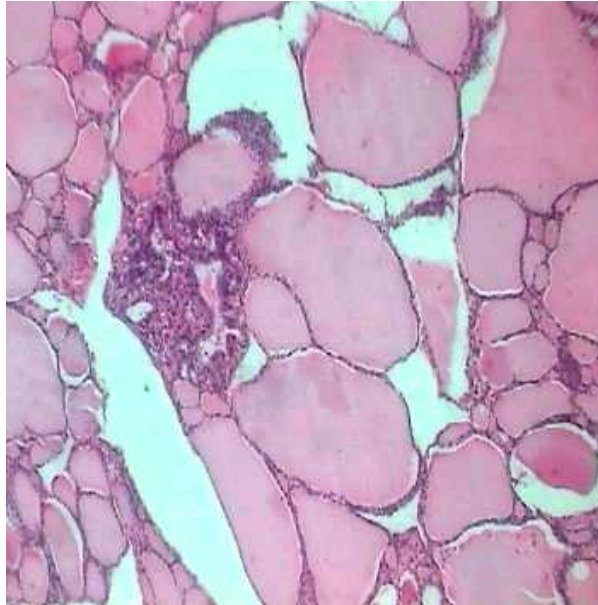
**Fig. 2.** Ultrasound examination of the thyroid gland



**Fig. 3 (a, b)** The cytogram corresponds to the diagnosis of nodular goiter



**Fig. 4.** Gross specimen of the resected thyroid gland



**Fig. 5.** Histogram. The nodular micro-macrofollicular colloid goiter with secondary changes, microfocal chronic lymphomatoid thyroiditis.  
The postoperative period was uneventful, with no complications