



Research Article

The Effect of Sulfated Glycosaminoglycans Extracted from *Acanthaster planci* on Full Thickness Excision Wound Healing in Animal Model

Nur Afiqah Bahrom^{1*}, K.N.S. Sirajudeen², George, W. Yip³ and Farid C. Ghazali¹

¹Biomedical Sciences Department, School of Health Sciences, Universiti Sains Malaysia, 16150, Kubang Kerian, Kelantan, Malaysia.

²Chemical Pathology Department, School of Medical Sciences, Universiti Sains Malaysia, 16150, Kubang Kerian, Kelantan, Malaysia.

³Yong Loo Lin School of Medicine, National University of Singapore, MD10, 4 Medical Drive, 117597, Singapore.

Abstract: In this study, sulfated glycosaminoglycans (GAGs) was extracted from *Acanthaster planci* and its wound healing effects was assessed. Macroscopic examination revealed significant ($p < 0.05$) contraction percentage (%) of wound on each observation (Day 1, Day 6 and Day 12) as compared to control group. Microscopic evaluations using light microscope, scanning, and transmission electron microscope showed that sulfated GAGs from *A. planci* enhanced epithelial cells migration and fibroblasts proliferation, and stimulate dense organisation of collagen fibers on the 12th day of observation, significantly ($p < 0.05$) compared to control group. The microscopic study concluded that the second-intention excisional wound healing occurs faster in the GAGs treated group as compared to the saline-treated control group, while microscopical study using light microscope, scanning and transmission electron microscope revealed that the GAGs treated group have a significant effect in enhanced epithelization formation, fibroblasts proliferation and collagen fibers organization parameters as compared to the control group.

Keywords: Sulfated Glycosaminoglycans; *Acanthaster planci*; Starfish; Microscopy; Wound healing.

1. Introduction

Glycosaminoglycans (GAGs), a complex polysaccharide structure consists of repeating disaccharide units that are inert and naturally located in a chemical composition within the connective tissue extracellular matrix and various soft basic tissues in humans and animals [1]. These compounds are imperially essential in the maintenance of proper elastic integrity within tissues and have become therapeutically beneficial in the acceleration of normal wound healing [2]. The structural function of GAGs in the wound healing cascade was also complemented by its physiological functions such as the involvement of cell proliferation (Hocking *et al.*, 1998), cellular differentiation, migration and adhesion [3] and prevention of blood coagulation within the endothelial vascular space [4]. *Per se*, the existence of GAGs thus plays a significant contributing role in harnessing wound healing pathophysiology.

Acanthaster planci is a starfish that belongs to the phylum Echinoderm. The crude toxin extracted from its

venom glands exhibits many diverse biological activities, that includes edema-formation presentation, histamine-releasing activities from mast cells [5] and cardiovascular vasodilating actions [6]. Homogenized biomass of *A. planci* was also found to have the properties to inhibit the growth of MCF-7 breast cancer cells by inducing apoptosis activities [7]. Moreover, despite various investigations conducted on *A. planci*, none have been able to relate its actual wound healing dynamic process, especially as revealed under various microscopy techniques. Therefore, we have investigated the dynamic effects of GAGs extracted from the integument wall of *A. planci* on full thickness dermal wound rat model by various microscopic techniques.

2. Methodology

2.1 Extraction of GAGs

Fresh sample of *A. planci* were harvested from Perhentian Island in the state of Terengganu under the supervision of Marine Park Malaysia Department.

*Corresponding author:

E-mail: nurafiqahbahrom@gmail.com.

Voucher specimen was prepared and registered as PPSK / USM/ 6171139-0611-APLC. The invertebrates were rinsed and their spines were dissected out using a scalpel and forceps given the intention to highly venomous potential. The integumental wall of the body part was utilized as previous studies revealed that the integument of *A. planici* is composed of collagen [8], which are closely associated as fibrils contained GAGs that are covalently associated with collagen constituents [9]. GAGs were also successfully extracted from the integument of other echinoderms, which are *Stichopus hermanni* and *Stichopus vastus* [10]. GAGs extraction from the *A. planici* was conducted via modification of Ledin *et al.*, method [11] adapted from Staatz *et al.*, [12]. 20mg of freeze-dried integument was homogenized in 0.1ml phosphate buffer saline (PBS). 0.5ml protease buffer containing 0.8mg/ml unspecific protease was added to the homogenate. The sample was incubated in a water bath at 55°C for 16 hours. After that, the protease was inactivated by heating at 90°C for 5 minutes and continued with an addition of 0.5ml, 1M MgCl₂ to each sample to achieve a final concentration of 2mM. After that, 0.5µl of benzonase was added and the sample was incubated again in a water bath at 37°C for 2 hours. After 2 hours, the benzene was inactivated *via* heating at 96°C for a 2 minute period. Then, 0.5ml of 4M NaCl was added to the sample to achieve a final concentration of 0.1M NaCl. Following this, the sample was then centrifuged at 15,000 rpm for 10 minutes. Finally, the supernatant which was the extracted GAGs from the *A. planici*'s integument was collected into a 2.0ml microcentrifuge tube and stored at -20°C until used. The quantification analysis was done using Blyscan™ Sulfated Glycosaminoglycan Assay kit (Bicolor, 7 U.K.) in accordance with the manufacturer's protocol.

2.2 Experimental study

Excisional wound was created at the dorsal part of the Sprague-Dawley rats (n=6) [Animal Ethics No. approval: USM / Animal Ethics Approval /2011/(71)(341)] using standard 6mm diameter biopsy punch and 20µl of 1µg/mg [13] of the extracted sulfated GAGs concentration was topically applied for 12 days daily to the wound for the treatment group while the phosphate buffer solution (PBS) will be topically applied on the wound for the control group. Each rat was placed in individual cages with the base of its floor was covered by wool wood bedding. The animal was monitored and provided with food pellets and tap water daily. The observation period for the wound was observed on day 1, 6 and 12 and this was followed by macroscopical analysis. The wound contraction percentage (%) was calculated according to below formulation [14]:

$$\text{Percentage of wound contraction (\%)} = \left[\frac{(A_{\text{Day 0}} - A_{\text{Day X}})}{A_{\text{Day 0}}} \right] \times 100$$

Where Day *x* = Day 1; Day 6; Day 12.

All the rats were sacrificed on day 12 for microscopic analysis. The tissues biopsied on day 12 were processed and viewed under Olympus BX 41 with EF-N Plan Objective attached with ColourView 12 camera and Analysis Imager software for light microscope (LM) analysis. While for the scanning electron microscope (SEM) and transmission electron (TEM) observation, Leo Supra 50 VP Field Emission equipped with Oxford INCA 400 energy dispersive microanalysis system and Phillips CM12 with Docu Version 3.2 image analysis were used, respectively. Statistical analysis of one-way ANOVA (parametric test) or Kruskal-Wallis (nonparametric test) with post-hoc comparison were used to compare wound contraction percentage (%) and score of wound morphology parameters between treatment and control groups. Statistical significance was accepted at a level of P<0.05.

3. Results and discussion

The macroscopic study was conducted to determine the wound contraction event that occurs during the excision-open wound repair, influenced by the sulfated GAGs from the integumental part of *A. planici*. Macroscopic analysis is a useful combination to microscopical study, which can evaluate the pathognomonic quantitative progress of wound repair [12]. On Day 12, the wound treated with the extracted GAGs showed that it was completely close with almost no sign of scar present in the treatment group. But the control wound group topically applied with PBS revealed that the wound was still not fully closed with unequal recovery (Fig. 1). The median score of the contraction data (Table 1) seems to indicate that, sulfated GAGs from the *A. planici* triggers significant (P<0.05) acceleration on wound contraction rate on the three observation days (day 1, 6 and 12) as compared to control group. These findings seem to suggest that sulfated GAGs extracted from the echinoderm did take part in escalating the early wound closure process. This is confirmed by previous studies that show the presence of GAGs aid in the acceleration of wound closure [15][16].

Table 1. Comparison of median (IqR) scores for wound contraction percentage (%) on Day 1, Day 6 and Day 12 between treatment group and control group.

Day	Groups	Median (IqR)	P*
Day 1	Treatment group (Sulfated GAGs from the <i>A. planici</i>)	8.33 (0.42)	<0.05; P=0.002
	Control group (PBS)	-	
Day 6	Treatment group (Sulfated GAGs from the <i>A. planici</i>)	34.17 (5.84)	<0.05; P=0.003
	Control group (PBS)	8.33 (2.08)	
Day 12	Treatment group (Sulfated GAGs from the <i>A. planici</i>)	75.00 (2.92)	<0.05; P=0.004
	Control group (PBS)	29.17 (14.58)	

*Kruskal-Wallis test, p-value of <0.05 as significant at 95% CI; (IqR) = Interquartile range

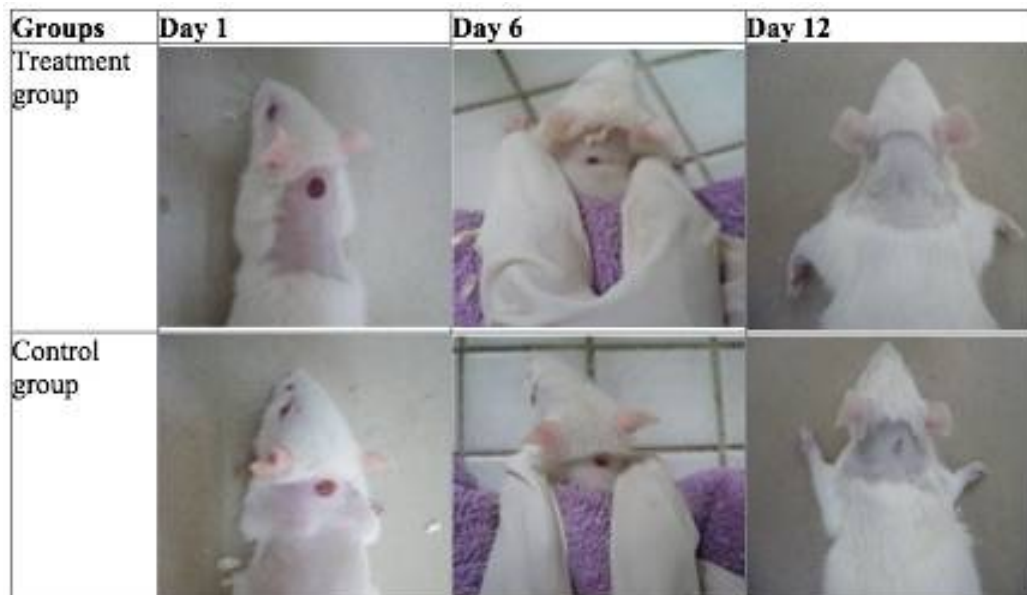


Fig. 1. Representative macroscopic images of the excision wound healing on Day 1, Day 6 and Day 12 for treatment group and control group on Sprague-Dawley rat.

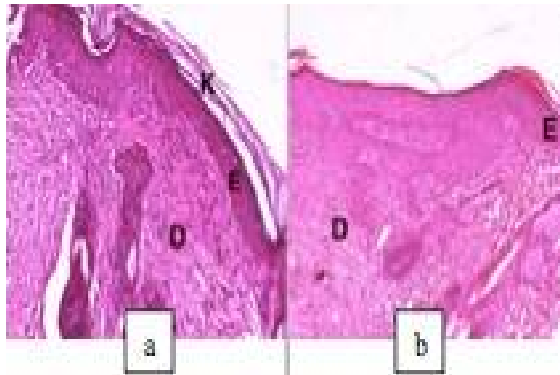
Majority of investigations using TEM and SEM were performed on individual aspects of wound healing [17]. Therefore, this study has put an effort to combine the three elemental microscopic approaches, which consists of LM, TEM, and SEM to study the wound healing process as a whole. These three microscopic techniques evidently are a more balanced approach and demonstrated a more comparative, as well as these techniques complemented each other [18]. For microscopic study, the semi-quantitative analysis have been applied on LM, where more direct comparison can be made possible and the differences between sulfated GAGs treatment groups and the control group were easily highlighted [19]. The semi-quantitative scoring system was based on the qualitative and quantitative aspects where the quantitative score were evaluated by the percentage (%) of parameters presenting the specific qualitative features of wound healing [20]. LM permits one to visualize cell outlines and large cell surface structures but limited to a resolution of about $0.2\mu\text{m}$ [21]. TEM, on the other hand, permits smaller structures to be resolved and reveals many fine details of the morphology of the cell surface, but only very small portions of tissue can be examined at a time. While SEM enables to visualize large portions of tissue at sufficiently high resolution to see many details but permits only the surfaces [21]. Therefore, it is critically important to correlate the observations made with these three techniques. For microscopic evaluations in this wound healing study, histomorphological features observation on 12th day have been explored and analysed. The 12th day wound healing was chosen because, on this day, the wound healing covered the events of epithelization, proliferation of fibroblasts and remodeling by collagen organisation [22].

Figs. 2a-2d (Fig. 2: Representative microscopic images of rat tissues from treatment and control group for various histomorphological features on Day 12) illustrated the LM and SEM microscopic images of epithelial cells migration in the sulfated GAGs treatment and control group. Both tissues treated with sulfated GAGs from *A. planici* (Fig. 2a-2c) revealed well-defined epithelization build up and the epithelial cell migration is completely bridging the wound with continuous keratinization formation with distinct and continuous layers of epidermal and dermal. Meanwhile, the control group (Fig. 2b-2d) demonstrated in distinct layers between epidermal and dermal with intermittent epidermal and keratin layer appearance found on Day 12. Biostatistical test revealed that the group treated with sulfated GAGs from *A. planici* have significant differences ($P < 0.05$) of epithelial cells migration medians compared to control group (Table 2). It is suggested that sulfated GAGs triggered the migration of the epidermal cells by well-structured build up of keratinized epithelial layers [22]. Epithelization was one of the main processes in wound healing to ensure successful repair [23]. Since the formation of keratin layers occurred in the sulfated GAGs treated wound, but not in the control group, it is indicated that the sulfated GAGs have stimulated highly mitotic activities in the epithelial layers. Previous studies had approved that topical application of sulfated GAGs to the wound site induced changes in wound healing kinetics (contraction and epithelialization) compared to spontaneous healing in untreated wounds or control group [24] and played a considerable role in epidermal cells proliferation and migration [25]. Thus, this strengthens the results of this study to confirm the positive role of sulfated GAGs in epithelization process.

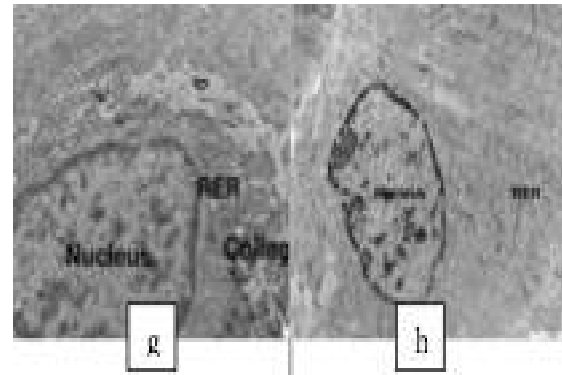
Table 2. Comparison of median (IqR) scores for various histomorphological features between treatment group and control group on the 12th day.

Histomorphological features	Groups	Median (IqR)	P*
Epithelization	Treatment group of sulfated GAGs	4.00(0.01)	<0.05;
	Control group (PBS)	3.35(0.09)	P=0.003
Fibroblasts proliferation	Treatment group of sulfated GAGs	3.02(0.42)	<0.05;
	Control group (PBS)	1.85(0.15)	P=0.004
Collagen fibers organisation	Treatment group of sulfated GAGs	3.35(0.09)	<0.05;
	Control group (PBS)	2.07(0.18)	P=0.004


*Kruskal-Wallis test, P value of <0.05 as significant at 95% CI; (IqR)=Interquartile range; NS = not significant



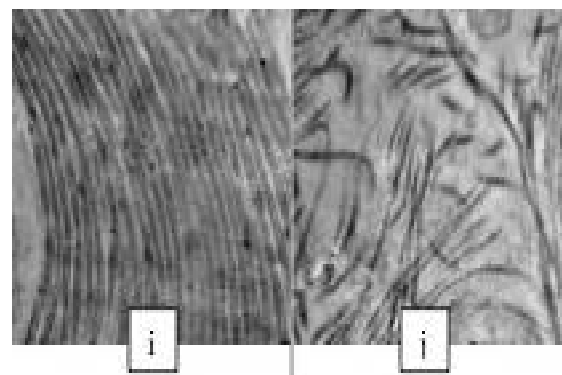
Figs. 2a & 2b. Light microscope (LM) image of epithelization formation in the treatment group of sulfated GAGs (Fig. 2a) and control group (Fig. 2b) on the 12th day (H&E stain, 10x).



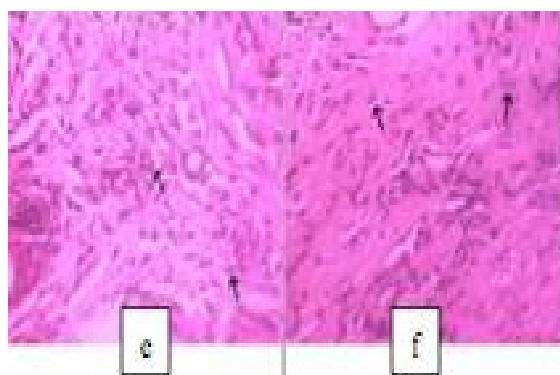
Figs. 2g & 2h. TEM image of a fibroblast for the treatment group of sulfated GAGs (Fig. 2g) and control group (Fig. 2h) (1562x, 1000nm scale bar). *RER = reticuloendothelial ribosomes.




Figs. 2c & 2d: SEM image of epithelization formation in the treatment group of sulfated GAGs (Fig. 2c) and control group (Fig. 2d) on the 12th day (350x, 7mm WD). *D = dermis; E = epidermis; K= keratin.



Figs. 2i & 2j. TEM image of collagen fibers organisation for the treatment group of sulfated GAGs (Fig. 2i) and control group (Fig. 2j) (500nm scale bar).



Figs. 2e & 2f: LM image of fibroblasts proliferation (arrows) in the treatment group of sulfated GAGs (Fig. 2e) and control group (Fig. 2f) on the 12th day (H&E stain, 40x).



Figs. 2k & 2l. SEM image of collagen fibers organisation in the treatment group of sulfated GAGs (Fig. 2k) and control group (Fig. 2l) (500x, 8mm WD).

Table 3. TEM evaluations of various histomorphological features of treatment and control group on the 12th day.

Histomorphological features	Group		n ^a
	Treatment group (sulfated GAGs from <i>A. planci</i>)	Control group (PBS)	
Fibroblasts	+++	++	6
Collagen	+++	++	6

Noted: + slight; ++ moderate; +++ intense;

^aEvaluation of 6 samples together for each group

Histomorphological feature of fibroblasts proliferation can be seen in Figs. 2e-2h (Fig. 2). Fig. 2e demonstrated tissue that was treated with sulfated GAGs from the *A. planci*, revealed a high proliferation number of fibroblasts that appeared as spindle-shaped of a flat cell with intense distribution in the granulation tissue. This fibroblast cell could be the one that is actively secreting protein or collagen due to its large nuclei and relatively pale stained. This appearance is a result of the activity of the DNA in the synthetic process which produces new molecules for the extracellular matrix [26]. Meanwhile, in control tissue (Fig. 2f), it is clearly shown that the low number of fibroblast moderately diffused with large gaps between each fibroblast, within the granulation tissue. TEM images of sulfated GAGs treatment group (Fig. 2g) revealed the presence of these two elements; rER organelles and collagen fibers which showed that high production of collagen fibers by numerous number of RER had occurred in the cytoplasm of these cells. This is a characteristic of an active fibroblast cell [27]. However, in the control group (Fig. 2h), the fibroblast was shown to have less-differentiated cytoplasm that lacks distinct presence of collagen fibers instead of having numerous amounts of rER organelles reside inside the cell. Result in Table 2 showed significant ($P < 0.05$) median score of fibroblasts proliferation of sulfated GAGs treatment group as compared to control group, while Table 3, data showed that fibroblasts distributed intensely in the treatment group and moderately distributed in control group. Therefore, the fibroblasts proliferation findings from semi-quantitative data and TEM evaluations were complemented well, as revealed that sulfated GAGs treatment group from *A. planci* showed an increase in fibroblasts proliferation on the 12th day of healing as compared to the control group treated with PBS. Fibroblast plays an important role in the synthesis of collagen, where the rER in the fibroblast is the vital site for collagen synthesis [27]. This study has confirmed that the sulfated GAGs of *A. planci* influence the invasive migration of fibroblasts during wound repair. Previous research has correlated well with this study, through the *in-vitro* of transmigration of normal adult human dermal fibroblasts from a collagen matrix into a fibrin gel, which required a cell surface of chondroitin sulfate (CS) and dermatan sulfate (DS) [29]. It has been shown that these sulfated GAGs (CS/DS) side chains are critical for adherence of fibroblasts to fibronectin [29],

as fibronectin provides a conduit for fibroblast migration [30].

The last histomorphological feature of wound healing in this study is collagen fibers organisation. Statistical results (Table 2) showed significant differences ($P < 0.05$) occurred in the collagen fibers organisation medians score between treatment groups of sulfated GAGs from *A. planci* as compared to control group. TEM micrograph showed a dense composition and well-organized arrangement of collagen fibrils in the treatment group of sulfated GAGs from the *A. planci* (Fig. 2i). Meanwhile, in the control group (Fig. 2j), the collagen fibrils were loosely arranged in an irregular manner and presented with large gaps between each fibril unit. TEM evaluation from Table 3 showed an intense distribution of collagen fibers in the sulfated GAGs treatment group from the *A. planci*, while moderate organisations discovered in control group. The SEM study of collagen fibers organization has also been assessed to compliment the ultrastructural findings from TEM and the light microscopic study. The collagen fibers in the SEM photomicrograph (Fig. 2k) appeared dense, compact and in well-organized manners in a sulfated GAGs treatment group with no interstitial space between each fibril unit. In the remodeling phase of wound healing, collagen is remodeled and realigned along tension lines. This process is often disrupted, leading to delayed wound healing [31] as seen in control tissue. Fibroblasts were said to be responsible for an assemblage of collagen fibers into sheets like formation as seen in the SEM photomicrograph of sulfated GAGs treated tissue [32]. Meanwhile, the collagen fibers in Fig. 2l appeared loosed with large interstitial space between each fibril unit in the control group. These results suggest that by the end of 12th day observation, sulfated GAGs treated on treatment group enhanced the remodelling phase of collagen fibrils. The positive promotion of sulfated GAGs from the *A. planci* treatment group in collagen fibers organisation during wound healing in this study was well-correlated with the finding from [33], which topically applied CS-GAGs on wound bed and showed positive wound healing contraction by the end of the observations day. Therefore, it was proven that sulfated GAGs from the *A. planci* have a positive influence on the collagenisation process and are imperially essential in the maintenance of proper elastic integrity within tissues, thus have become therapeutically beneficial in the acceleration of normal wound healing.

4. Conclusions

The presence of *A. planci* sulfated glycosaminoglycans in improving wound healing in terms of time management is beneficial. Being a biowastage source itself, this crown-of-thorns invertebrate biomass is indeed an entity that is worth further investigated for tangible health-related bio-product significant for wound management.

Acknowledgments

This work was supported by the Ministry of Higher Education (Fundamental Grant Research Scheme) under Grant [number 203/PPSK/6171139] and the researchers greatly appreciate the technical assistance support from Mr. Hasbullah, Mr. Muhammad Kamil, Mrs. Nur Hanim and Mrs. Norazita from School of Health Sciences, Universiti Sains Malaysia.

References

- [1]. Yamada, S., Sugahara, K. & Ozbek, S. (2011). Evolution of glycosaminoglycans: comparative biochemical study. *Commun. Integr. Biol.*, 4(2): 150-158.
- [2]. Gallo, R.L. & Bernfield, M. (1996). Proteoglycans and their role in wound repair. In: Clark, R.A.F. (Ed.). *The Molecular and Cellular Biology of Wound Repair*, 2nd ed., Plenum, New York.
- [3]. Hocking, A.M., Shinomura, T. & McQuillan, D.J. (1998). Leucine-rich repeat glycoproteins of the extracellular matrix. *Matrix Biol.*, 17: 1-19.
- [4]. Parkinson, J.F., Koyama, T., Bang, N.Y. & Preissner, K.T. (1992). Thrombomodulin: an anticoagulant cell surface proteoglycan with physiologically relevant glycosaminoglycan moiety. *Advances in Experimental Medicine and Biology*, 313: 177-188.
- [5]. Shiomi, K., Nagai, K., Yamanaka, H. & Kikuchi, T. (1989). Inhibitory effect of anti-inflammatory agents on the cutaneous capillary leakage induced by six marine venoms. *Nippon Suisan Gakkaishi*, 55: 131-134.
- [6]. Shiroma, N., Noguchi, K., Matsuzaki, T., Ojiri, Y., Hirayama, K., Sakanashi, M. (1994). Haemodynamic and haematologic effects of *Acanthaster planci* venom in dogs. *Toxicon*, 32: 1217-1225.
- [7]. Mutee, A.F., Salhimi, S.M., Ghazali, F.C., Al-Hassan, F.M., Lim, C.P., Ibrahim, K. & Asmawi, M.Z. (2012). Apoptosis induced in human breast cancer cell line by *Acanthaster planci* starfish extract compared to Tamoxifen. *African Journal of Pharmacy and Pharmacology*, 6(3): 129-134.
- [8]. Tan, C.C., Karim, A.A., Latiff, A.A., Gan, C.Y., Ghazali, F.C. (2013). Extraction and characterization of pepsin-solubilized collagen from the body wall of crown-of-thorns Starfish (*Acanthaster planci*). *International Food Research Journal*, 20(6): 3013-3020.
- [9]. Trotter, J.A., Lyons-Levy, G., Luna, D., Koob, T.J., Keene, D.R. & Atkinson, M.A.L. (1996). Stiparin: A glycoprotein from sea cucumber dermis that aggregates collagen fibrils. *Matrix Biology*, 15: 99-110.
- [10]. Masre, S.F., Yip, G.W., Sirajudeen, K.N.S and Ghazali, F.C. (2011). Quantitative analysis of sulphated glycosaminoglycans content of Malaysian sea cucumber *Stichopus hermanni* and *Stichopus vastus*. *Natural Product Research*, 26(7):684-9.
- [11]. Ledin, J., Staatz, W., Li, J.P., Gotte, M., Selleck, S., Kjellén, L. & Spillmann, D. (2004). Heparan sulfate structure in mice with genetically modified heparan sulfate production. *J. Biol. Chem.*, 279(41): 42732-42741.
- [12]. Staatz, W.D., Toyoda, H., Kinoshita-Toyoda, A., Chhor, K. and Selleck, S.B. (2001). Analysis of proteoglycans and glycosaminoglycans from *Drosophila*. In: Iozzo R.V. (eds) *Proteoglycan Protocols. Methods in Molecular Biology™*, Vol. 171. Humana Press Inc., New Jersey, pp. 41-52.
- [13]. Zou, X.H., Foong, W.C., Cao, T., Bay, B.H., Ouyang, H.W. and Yip, G.W. (2004). Chondroitin sulfate in palatal wound healing. *Journal of Dental Research*, 83(11): 880-885.
- [14]. Sardari, K., Dehgan, M.M., Mohri, M., Emami, M.R., Mirshahi, A., Maleki, M., Barjasteh, M.N. & Aslani, M.R. (2006). Macroscopic aspects of wound healing (contraction and epithelialisation) after topical administration of allicin in dogs. *Comparative Clinical Pathology*, 15: 231-235.
- [15]. Cross, S.E., Naylor, I.L., Coleman, R.A. & Teo, T.C. (1995). An experimental model to investigate the dynamics of wound contraction. *British Journal of Plastic Surgery*, 48: 189-197.
- [16]. Olczyk, P., Mencner, Ł. and Komosińska-Vashev, K. (2014). The Role of the Extracellular Matrix Components in Cutaneous Wound Healing. *BioMed Research International*. Article ID 747584, <http://dx.doi.org/10.1155/2014/747584>.
- [17]. Mulder, G.D., Patt, L.M., Sanders, L., Rosenstock, J., Altman, M.I., Hanley, M.E., Duncan, G.W. (1994). Enhanced healing of ulcers in patients with diabetes by topical treatment with glycyl-L-histidyl-L-lysine copper. *Wound Repair and Regeneration*, 2: 259-269.
- [18]. Croft, C.B. & Tarin, D. (1970). Ultrastructural studies of wound healing in mouse skin. I. Epithelial behaviour. *Journal of Anatomy*, 106: 63-77.
- [19]. Holbrook, K.A. & Odland, G.F. (1975). The fine structure of developing human epidermis: light, scanning and transmission electron microscopy of the periderm. *Journal of Investigative Dermatology*, 65: 16-38.
- [20]. Piaggese, A., Viacava, P., Rizzo, L., Naccarato, G., Baccetti, F., Romanelli, M., Zampa, V. & Del Prato, S. (2003). Semiquantitative analysis of the histopathological features of the neuropathic foot ulcer: effects of pressure relief. *Diabetes Care*, 26 (11): 3123-3128.
- [21]. Rajabi, M.A. and Rajabi, F. (2007). The effect of estrogen on wound healing in rats. *Pakistan Journal of Medical Sciences*, 23(3): 349-352.
- [22]. Bell, P.B., Revel, J.P. (1980). Scanning electron microscope application to cells and tissues in culture. In: Hodges, G.M. and Hallows, R.C.

- (Eds), Biomedical Research Application of Scanning Electron Microscopy. Academic Press, London. pp. 1-65.
- [23]. Braiman-Wiksman, L., Solomonik, I., Spira, R., Tennenbaum, T. (2007). Novel insights into wound healing sequence of events. *Toxicologic Pathology*, 35(6): 767-79.
- [24]. Escámez, M.J., García, M., Larcher, F., Meana, A., Muñoz, E., Jorcano, J.L., Del Río, M. (2004). An *in vivo* model of wound healing in genetically modified skin-humanized mice. *Journal of Investigative Dermatology*, 123: 1182-1191.
- [25]. Sarkar, A. (2008). The effect of Stromal cell Derived Factor-1 (SDF-1) and collagen-GAG (Glycosaminoglycan) scaffold on skin wound healing. Thesis, Massachusetts Institute of Technology, Dept. of Mechanical Engineering. pp 155-160.
- [26]. Ojeh, N., Hiilesvuo, K., Wärrä, A., Salmivirta, M., Henttinen, T. & Määttä, A. (2008). Ectopic expression of syndecan-1 in basal epidermis affects keratinocyte proliferation and wound re-epithelialization. *Journal of Investigative Dermatology*, 128: 26-34.
- [27]. Priest, R.E. (1972). Cellular replication and specialized function of fibroblasts. *Journal of Investigative Dermatology*, 59: 35-39.
- [28]. Deodhar, A.K. & Rana, R.E. (1997). Surgical physiology of wound healing: a review. *Journal of Postgraduate Medicine*, 43: 52-6.
- [29]. Clark, R.A., Lin, F., Greiling, D., An, J. & Couchman, J.R. (2004). Fibroblast invasive migration into fibronectin/fibrin gels requires a previously uncharacterized dermatan sulfate-CD44 proteoglycan. *Journal of Investigative Dermatology*, 122: 266-277.
- [30]. Faassen, A.E., Schragar, J.A., Klein, D.J., Oegema, T.R., Couchman, J.R. & McCarthy, J.B. (1992). A cell surface chondroitin sulfate proteoglycan, immunologically related to CD44 is involved in type I collagen-mediated melanoma cell motility and invasion. *Journal of Cell Biology*, 116: 521-531.
- [31]. Greiling, D. & Clark, R.A. (1997). Fibronectin provides a conduit for fibroblast transmigration from collagenous stroma into fibrin clot provisional matrix. *Journal of Cell Science*, 110: 861-870.
- [32]. Shivananda Nayak, B., Sivachandra Raju, S., Orette, F.A. & Chalapathi Rao, A.V. (2007). Effects of *Hibiscus rosa sinensis* L (Malvaceae) on Wound Healing Activity: A Preclinical Study in a Sprague Dawley Rat. *The International Journal of Lower Extremity Wounds*, 6(2): 76-81. <https://doi.org/10.1177/1534734607302840>.
- [33]. Alberts, B., Bray, D., Hopkin, K., Johnson, A., Lewis, J., Raff, M., Roberts, K. and Walter, P. (2013). Essential Cell Biology. Fourth edition. Garland Science, Taylor & Francis Group, New York. pp. 689-690.
- [34]. Kirker, K.R. (2003). Glycosaminoglycan hydrogels for wound healing. Dissertation for Thesis (Ph.D.), Dept. of Bioengineering, University of Utah, Salt Lake City, UT.