

## Signet-Ring Cell Carcinoma of the Ampulla of Vater

Lianda Siregar\*, Imelda M Loho\*, Agus Sudiro Waspodo\*, Dwi Sri Rejeki\*\*, Fajar Firsyada\*\*\*, Rahmanandika Swadari\*, Getty Inash Nandika\*, Muhammad Iqbal Siregar\*

\*Department of Gastroenterology and Hepatology, Dharmais National Cancer Center Hospital, Jakarta

\*\*Department of Anatomical Pathology, Dharmais National Cancer Center Hospital, Jakarta

\*\*\*Department of Surgery, Dharmais National Cancer Center Hospital, Jakarta

### Corresponding author:

Lianda Siregar. Department of Gastroenterology and Hepatology, Dharmais National Cancer Center Hospital. Jl. Let. Jend. S. Parman Kav. 84-86 Jakarta Indonesia. Phone/facsimile: +62-21-5681570. E-mail: liandadr\_siregar@yahoo.com

### ABSTRACT

Signet-ring cell carcinoma (SRCC) of the ampulla of Vater is a very rare case and only 28 cases have been reported in the English literature. Herein, we report a 59-year-old woman with SRCC of the ampulla of Vater. She developed symptoms of obstructive jaundice at early stage of disease and underwent pylorus-preserving Whipple procedure as definitive treatment. Histopathology examination showed numerous tumor cells with intracytoplasmic mucin and eccentric nuclei. Her tumor has already invaded the serosa of duodenum, but no infiltration to the stomach, pancreas, and lymphovascular structure. Her surgical margins and regional lymph nodes were free of tumor. She was diagnosed with T2N0M0 (stage IB) SRCC of the ampulla of Vater. No adjuvant treatment was given and she has been doing well for five months after surgery.

**Keywords:** Signet ring cell carcinoma, ampulla of Vater, pylorus-preserving Whipple procedure

### ABSTRAK

Signet-ring cell carcinoma (SRCC) ampulla Vater merupakan kasus yang sangat jarang dan baru 28 kasus yang dilaporkan dalam literatur berbahasa Inggris. Kami melaporkan kasus seorang wanita berusia 59 tahun dengan SRCC ampulla Vater stadium awal yang memberikan gejala ikterus obstruktif dan menjalani prosedur Whipple dengan tetap mempertahankan pilorus. Pemeriksaan histopatologi menunjukkan adanya sebaran sel tumor dengan musin intrasitoplasmik dan nukleus eksentrik, serta invasi tumor pada lapisan serosa duodenum, namun tidak ditemukan adanya infiltrasi ke lambung, pankreas, dan jaringan limfovaskuler. Tepi sayatan dan kelenjar getah bening regional bebas dari sel tumor sehingga disimpulkan bahwa pasien ini menderita SRCC stadium IB (T2N0M0). Pasien tidak diberikan terapi ajuvan dan kondisinya masih baik hingga lima bulan pasca operasi.

**Kata kunci:** Signet ring cell carcinoma, ampulla Vater, prosedur Whipple dengan mempertahankan pilorus

## INTRODUCTION

Carcinomas of the papilla of Vater represent the second largest proportion of periampullary carcinomas, which include ampullary carcinoma and carcinomas of the pancreas, the distal bile duct, and the periampullary duodenum.<sup>1</sup> Most patients manifest symptoms early in the course of their disease due to biliary obstruction. Therefore, their resection rate at diagnosis is considerably high, i.e. 62-96%.<sup>2</sup>

The pathogenesis of carcinomas of the ampulla of Vater is special. The ampulla of Vater is a valve organ which includes the border between two different types of mucosa. The intestinal mucosa of the ampuloduodenum adjoins the mucosa of the ampullo-pancreatico-biliary duct (the common channel).<sup>3</sup> This area is exposed to three different kind of juices, i.e. pancreatic juice, bile, and gastric juice and three different epithelial types can be found here. Therefore, this area has the potency to transform into malignancy. Most ampullary carcinomas are usually well-differentiated adenocarcinomas. Signet-ring cell carcinoma (SRCC) of the ampulla of Vater is very rare and no specific guidelines about their management are available.<sup>4,5</sup>

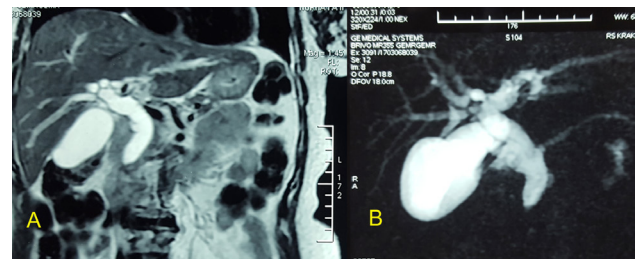
Here, we present a case of SRCC of the ampulla of Vater, which is successfully managed with pylorus-preserving pancreaticoduodenectomy (Whipple procedure).

## Case Report

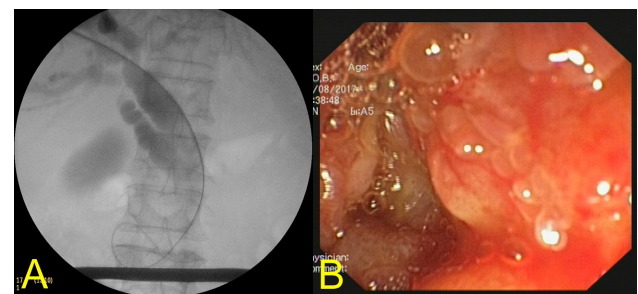
A 59-year-old woman was referred to our hospital for further management of her obstructive jaundice. She had a five-month-long history of nausea and three-month-long history of jaundice. Magnetic resonance imaging (MRI) and magnetic resonance cholangio pancreatography (MRCP) revealed dilated common bile duct, common hepatic duct, and intrahepatic duct, with enlargement of the gall bladder and hepatomegaly, but without any visible mass lesion (Figure 1). Gastroduodenoscopy showed moderate-to-severe duodenitis at the bulbar part. Histopathologic sample from duodenum showed a small part of gland had changed into tumor mass, which might mimic signet ring cell carcinoma.

She was referred to our hospital for further management. On physical examination, she looked icteric without other remarkable findings. Laboratory examination showed decreased haemoglobin level (9.8 g/dL), increased white blood cells count (12800/ $\mu$ L), increased platelet count (881000/ $\mu$ L), increased

carbohydrate antigen (CA) 19-9 level (68.72 U/ mL), and increased total bilirubin 11.07 mg/dL with predominant direct bilirubin 9.8 mg/dL. Endoscopic retrograde cholangiopancreatography (ERCP) showed a swollen ampulla with erosive and erythematous mucosa along the duodenal bulb to the second part of duodenum (Figure 2A). Biliary cannulation was difficult to perform so we placed a percutaneous transhepatic biliary drainage (PTBD) tube using a 22-G Chiba needle and a 6-French dilator to gain access to the common bile duct. A 0.035-inch hydrophilic guide-wire was advanced through the stenosis into the duodenum, which was then exchanged for a 0.035-inch stiff guide-wire. Finally, an 8.5-French drainage catheter was inserted alongside the guidewire into the narrow segment. The outer part of the drainage catheter was connected to a urine bag so the bile could flow to the duodenum and to the drainage bag. Percutaneous transhepatic cholangiogram showed dilated common bile duct, common hepatic duct, intrahepatic ducts, and enlarged gall bladder (Figure 2B). One month later, the patient underwent a pylorus-preserving pancreaticoduodenectomy (Whipple procedure) and



**Figure 1.** Magnetic resonance imaging (MRI) (Figure 1A) and magnetic resonance cholangio-pancreatography (MRCP) (Figure 1B) showed dilatation of common bile duct, common hepatic duct, and intrahepatic duct, with enlargement of gall bladder, but without dilatation of pancreatic duct. No visible mass lesion could be determined in these pictures.

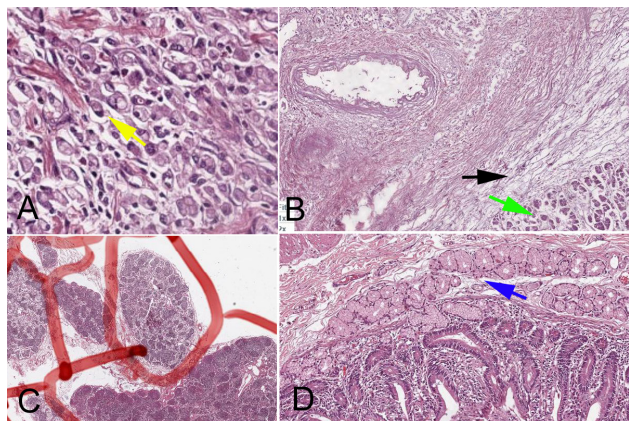


**Figure 2A.** Endoscopic retrograde cholangiopancreatography (ERCP) showed a swollen ampulla with a reddish and erosive mucosa. 2B. Percutaneous transhepatic cholangiogram, performed during placement of percutaneous transhepatic biliary drainage (PTBD) catheter, showed dilated common bile duct, common hepatic duct, intrahepatic ducts, and enlarged gall bladder.

she has been doing well five months after surgery.

### Pathological Findings

The resection specimen showed a 2.5 x 1.5 x 2 cm thickening area of duodenum around the orifice of the ampulla of Vater. Histologically, the thickening part contained simple columnar epithelial cells with hyperplastic goblet cells and diffusely distributed signet-ring cells containing intracytoplasmic mucin with eccentric nuclei (Figure 3A). The tumor infiltrated the duodenal serosa (Figure 3B), but the pancreas, stomach (Figure 3D), and surgical margins were free of tumor. No lymphovascular invasion was present within the tumor. Of the nine common bile duct lymph nodes, none was positive for metastatic tumor cells (Figure 3C). According to American Joint Committee on Cancer TNM classification, this patient was diagnosed as T2N0M0 (stage 1B).<sup>6</sup> The patient was not given



**Figure 3A.** Signet-ring tumor cells showed intracytoplasmic mucin that displaces nucleus to one side (yellow arrow signs) **B.** Tumor cells (green arrow) infiltrated the duodenal serosa (black arrow), but no tumor cells were found in the pancreas. **C.** None of the regional lymph nodes was positive for tumor cells. **D.** No tumor cells were found in the gastric mucosa (blue arrow).

adjuvant treatment and remained well during three-month follow up.

### DISCUSSION

Signet-ring cell carcinoma (SRCC) usually occurs in the gastrointestinal tract, especially in the stomach, and SRCC of the ampulla of Vater is extremely rare. In a tertiary hospital in China, of all 162 patients treated with ampullary carcinomas over five-year period, only eight cases (4.9%) were identified as SRCC.<sup>7,8</sup> Signet-ring cell carcinoma is characterized by the presence of typical signet-ring cells, i.e. cells that contain mucins that displace the nucleus to one side.<sup>9</sup> When this morphologic change presents in more than 50% of tumor cells, it is defined as SRCC.<sup>9</sup> Signet-ring cell carcinomas

share identical morphology despite different primary site of origin, therefore in unknown primary cases, immunohistochemical profiling may help in the workup.

According to Wen et al, SRCC of the ampulla of Vater may be categorized into four subtypes: intestinal-type, pancreaticobiliary-type, gastric, and mixed types (composed of intestinal mucosa lining and pancreaticobiliary epithelium).<sup>8</sup> This classification is based on immunohistochemistry methods, using cytokeratin (CK) and mucin (MUC) immunohistochemical staining. Patients with intestinal-type ampullary SRC had a better prognosis compared with the pancreatobiliary type. Furthermore, gastric differentiation in ampullary SRC of intestinal type or pancreatobiliary type, demonstrated worse prognosis than others. Coexpression of the E-cadherin/ $\beta$ -catenin complex is also a marker of poor prognosis. The findings of Wen et al give highlights to the origin of SRCC of the ampulla of Vater. In 1982, Blundell et al hypothesized that SRCC arose from the presence of gastric metaplasia in the ampulla of Vater. Using immunohistochemical staining with antibodies to cytokeratins and mucins, Zhou et al also proposed that SRCC were histogenetically related to intestinal mucosa.<sup>8,10,11</sup>

Confirming a diagnosis of ampullary neoplasms can be challenging. Patients may present with obstructive jaundice without any evidence of mass lesion in abdominal CT scan or endoscopy. Serum CA 19-9 is elevated in 86.4% of ampullary carcinoma patients.<sup>12</sup> Endoscopic ultrasound may help to find mass lesion obstructing the biliary system. During the diagnostic workup, it is difficult to distinguish between primary ampullary carcinoma and the more common periampullary tumors, such as pancreatic, duodenum, and bile duct carcinomas. To complicate further, there are no specific guidelines for diagnosis of ampullary neoplasms. Usually, ampullary neoplasms are incorporated into the guidelines of biliary tract or pancreatic carcinomas.<sup>13</sup> From a surgical point of view, the distinction is not essential because if a malignant lesion is suspected in that area, the patients will undergo the same procedure (pancreaticoduodenectomy or Whipple procedure). However, ampullary and periampullary tumors have different prognosis.

There is no specific guideline regarding treatment of ampullary carcinoma. Due to their location, the size of ampullary carcinomas is often small at the time of diagnosis and tumor resection is the mainstay of treatment.<sup>14</sup> Predictors of survival in ampullary SRCC have not been elaborated due to the small number

of cases. Signet ring cell carcinoma of the stomach carries a poor prognosis, with five-year survival rate only 16.2%. In contrary, based on previously reported cases, the follow-up period of resected patients with SRCC of the ampulla of Vater varied from 6 to 134 months.<sup>4</sup> The worst follow-up period was in patients with primary tumor invading pancreas (T3) or peripancreatic tissue (T4), regional lymph node metastasis, or distant metastasis.<sup>4,5,8,15,16,17</sup> In patients with periampullary adenocarcinoma, pancreatobiliary type differentiation, regional lymph node involvement, and vessel involvement are independent adverse predictors of survival.<sup>18</sup> Our patient was diagnosed as T2N0M0 (stage IB) so we did not plan to give adjuvant treatment, such as chemotherapy or radiotherapy, and she still performed well five months after surgery. Pre-operative biliary drainage with PTBD was performed in our patient approximately one month before surgery to manage her symptoms of jaundice and improve her quality of life while waiting for surgery.

## CONCLUSION

We presented a very rare case of SRCC of the ampulla of Vater, with invasion to the wall of duodenum. No specific treatment guidelines are available. Although several cases have been reported previously, the prognosis after resection in early stage cancer is not clear.

## Statement of Ethics

Informed consent was obtained for this case report.

## Disclosure Statement

The authors declare that there is no conflict of interest regarding the publication of this paper.

## REFERENCES

1. Yeo CJ, Sohn TA, Cameron JL, Hruban RH, Lillmoed KD, Pitt HA. Periampullary adenocarcinoma: analysis of 5-year survivors. *Ann Surg* 1998;227:821-31.
2. Talamini MA, Moesinger RC, Pitt HA, Sohn TA, Hruban RH, Lillmoed KD, et al. Adenocarcinoma of the ampulla of Vater. A 28-year experience. *Ann Surg* 1997;225:590-9:9-600.
3. Kimura W, Futakawa N, Zhao B. Neoplastic diseases of the papilla of Vater. *J hepatobiliary Pancreat surg* 2004;11:223-31.
4. Wakasugi M, Tanemura M, Furukawa K, Murata M, Miyazaki M, Oshita M, et al. Signet ring cell carcinoma of the ampulla of vater: Report of a case and a review of the literature. *Int J Surgery Case Rep* 2015;12:108-11.
5. Acharya MN, Panagiotopoulos N, Cohen P, Ahmad R, Jiao LR. Poorly-differentiated signet-ring cell carcinoma of the ampulla of Vater: report of a rare malignancy. *JOP* 2013;14:190-4.
6. Edge SB, Byrd DR, Compton CC, Fritz AG, Greene FL, Trotti A. *AJCC cancer staging manual*. 7th ed. France: Springer; 2010.
7. Henson DE, Dittus C, Younes M, Nguyen H, Albores-Saavedra J. Differential trends in the intestinal and diffuse types of gastric carcinoma in the United States, 1973-2000: increase in the signet ring cell type. *Arch Pathol Lab Med* 2004;128:765-70.
8. Wen X, Wu W, Wang B, Yao H, Teng X. Signet ring cell carcinoma of the ampulla of Vater: Immunophenotype and differentiation. *Oncology letters* 2014;8:1687-92.
9. Minh DN, Brian P, Ping W, Wendy LF. Mucin Profiles in Signet-ring Cell Carcinoma. *Arch Pathol Lab Med* 2006;130:799-804.
10. Blundell CR, Kanun CS, Earnest DL. Biliary obstruction by heterotopic gastric mucosa at the ampulla of Vater. *Am J Gastroenterol* 1982;77:111-4.
11. Zhou H, Schaefer N, Wolff M, Fischer HP. Carcinoma of the Ampulla of Vater: comparative histologic/immunohistochemical classification and follow-up. *The Am J Surg Pathol* 2004;28:875-82.
12. Chen YF, Mai CR, Tie ZJ, Feng ZT, Zhang J, Lu XH, et al. The diagnostic significance of carbohydrate antigen CA 19-9 in serum and pancreatic juice in pancreatic carcinoma. *Chi Med J* 1989;102:333-7.
13. Guidelines for the management of patients with pancreatic cancer periampullary and ampullary carcinomas. *Gut* 2005;54:v1-v16.
14. Beger HG, Treitschke F, Gansauge F, Harada N, Hiki N, Mattfeldt T. Tumor of the ampulla of Vater: experience with local or radical resection in 171 consecutively treated patients. *Arch Surg* 1999;134:526-32.
15. Tseng LJ, Jao YT, Mo LR. Signet ring cell carcinoma of major papilla. *Gastrointest endosc* 2002;56:733.
16. Gao JM, Tang SS, Fu W, Fan R. Signet-ring cell carcinoma of ampulla of Vater: contrast-enhanced ultrasound findings. *World J Gastroenterol* 2009;15:888-91.
17. Maekawa H, Sakurada M, Orita H, Sato K. Signet-ring cell carcinoma co-existing with adenocarcinoma of the ampulla of vater. A case report. *JOP* 2011;12:162-6.
18. Westgaard A, Tafjord S, Farstad IN, Cvancarova M, Eide TJ, Mathisen O, et al. Pancreatobiliary versus intestinal histologic type of differentiation is an independent prognostic factor in resected periampullary adenocarcinoma. *BMC Cancer* 2008;8:170.