

Case Report: A 31-year-old Post Cesarean Section Women with Intrahepatic Cholestasis of Pregnancy and Post Partum Bell's Palsy

Syifa Mustika, RC Tarigan

Division of Gastroentero-hepatology, Department of Internal Medicine
Faculty of Medicine, Universitas Brawijaya/Dr. Saiful Anwar Hospital, Malang

Corresponding author:

Syifa Mustika. Division of Gastroentero-hepatology, Department of Internal Medicine, Dr. Saiful Anwar Hospital. Jl. Jaksa Agung Suprpto No. 2 Malang Indonesia. Phone/facsimile: +62-341-348265. E-mail: drtika_78@yahoo.com.

ABSTRACT

Intrahepatic cholestasis of pregnancy (ICP) is cholestasis condition characterized by pruritus, elevated serum aminotransferase and bile acid levels with onset in the second or third trimester of pregnancy. Estimated of ICP prevalence only 0.001% to 0.3%. Bell's Palsy is a neurological disorder that causes facial muscles on one side of the face to suddenly weaken or become paralyzed. Bell's Palsy is more common in young adults, older people, diabetics and pregnant women. A 31-year-old women with major complaint is yellow eyes. She got itching in all over the body. Patient was in second pregnancy with gestational age was 39-40 weeks. She suffered from unable to close her eyelid or blink. Patient was diagnosed with cholestasis intrahepatal in pregnancy and Bell's palsy post partum. Diagnosis was established concluded from anamnesis, physical examination and hepar biopsy. The result of a liver biopsy showed intrahepatic cholestasis. From Fibroscan examination was visible with F2 category or Moderate Fibrosis. The main management of this patient is cesarean section with ursodeoxycholic acid (UDCA) and corticosteroid therapy. Patient was administrated with antiviral therapy for her Bell's Palsy condition. After 1 week hospitalization, patient was discharged with improvement of her major complaint.

Keywords: intrahepatic cholestasis of pregnancy, post partum Bell's palsy

ABSTRAK

Kolestasis Intrahepatik dalam kehamilan (KIK) adalah kondisi kolestasis yang ditandai oleh pruritus, peningkatan serum aminotransferase dan kadar asam empedu dengan onset pada trimester kedua atau ketiga kehamilan. Perkiraan prevalensi KIK hanya 0,001% hingga 0,3%. Bell's Palsy adalah gangguan saraf yang menyebabkan otot-otot wajah di satu sisi wajah tiba-tiba melemah atau menjadi lumpuh. Bell's Palsy lebih sering terjadi pada orang dewasa muda, orang tua, penderita diabetes dan wanita hamil. Seorang wanita 31 tahun dengan keluhan utama adalah mata kuning dan gatal di seluruh tubuh pada kehamilan kedua dengan usia kehamilan adalah 39-40 minggu. Pasien juga mengeluh tidak bisa menutup kelopak matanya atau berkedip. Diagnosis kolestasis intrahepatik pada kehamilan dan post partum Bell's palsy ditegakkan dari anamnesis, pemeriksaan fisik dan biopsi hati yang menunjukkan kolestasis intrahepatik. Pemeriksaan Fibroscan menunjukkan hasil F2 atau fibrosis sedang. Manajemen utama pasien ini adalah seksio sesaria dengan ursodeoxycholic acid (UDCA) dan terapi kortikosteroid. Pasien mendapatkan terapi antivirus untuk kondisi Bell's Palsy-nya. Setelah 1 minggu dirawat di rumah sakit, pasien dipulangkan dengan perbaikan kondisi.

Kata kunci: kolestasis intrahepatik kehamilan, post partum Bell's palsy

INTRODUCTION

Intrahepatic cholestasis of pregnancy (ICP) is a cholestasis condition characterized by pruritus, elevated serum aminotransferase and bile acid levels with onset in the second or third trimester of pregnancy, and improvement of spontaneous signs and symptoms within two to three weeks after delivery. In the first description of ICP in 1883, Ahlfeld described pruritus and jaundice that occurred in the mother during the last trimester of pregnancy and disappeared after childbirth.^{1,2} Estimates of ICP prevalence in the United States are 0.001% to 0.32%, Chilean 4.0%, UK 0.7%, and Scandinavia 1.0% to 2.0%. As for ICP, the prevalence of the disease varies according to ethnicity, and this is indicated by the prevalence in the UK (0.6% Caucasian, 1.5% Pakistanis, 1.2% South Asians). In the United States, the prevalence of ICP 5.6% in Hispanics.³

Pruritus is a major clinical symptom of ICP. Pruritus may be mild and tolerable for some patients, but may also be severe and have a serious impact. This may be very disturbing to the quality of life of patients who cause sleep deprivation, psychological suffering and even thoughts of suicide. Usually occurs in the third trimester, after 30 weeks of gestation, but rare and uncommon cases develop before that age.^{4,5,6} Mild Jaundice with conjugated bilirubin serum levels occurs only occasionally in 10 to 15% of cases.^{4,7} Jaundice usually develops 1-4 weeks after onset of pruritus, but can sometimes be an early symptom.^{8,9} Subclinical steatorrhea may be seen simultaneously with fat malabsorption, which can lead to vitamin K deficiency resulting in prolonged prothrombin time and postpartum hemorrhage.^{10,11} Higher incidence of gallstones and cholecystitis develops 4x in women with a history of ICP (as well as in families with a history of ICP) than in the normal population.¹² Abdominal pain, malaise and other constitutional symptoms are rare. The major biochemical changes are increased serum bile acid and elevated aminotransferase levels.¹³ Total bile acid levels may increase 10-100 times above the normal range and higher rates of fetal complications are observed with rates of maternal bile acids exceeding 40 $\mu\text{mol/L}$.^{14,17,18,20} The serum aminotransferase level makes it possible to improve ICP patients after starting UDCA treatment compared with fasting serum bile acid levels initially increased due to elevated serum levels of ursodeoxycholic acid (UDCA). The maternal prognosis improves and symptoms resolve rapidly after delivery, accompanied by normalized serum liver and bilirubin tests.²² If persistent abnormalities are found, prompt reconsideration of underlying chronic liver diseases

such as primary biliary cirrhosis, primary sclerosis cholangitis, or chronic hepatitis C may all be associated with pruritic development late in pregnancy.^{24,25}

Bell's Palsy is a neurological disorder that causes facial muscles on one side of the face to suddenly weaken or become paralyzed. The eye-closing muscles control the tear glands, while controlling one of the salivary glands and the flavor in front of the tongue are all controlled by the facial nerve. When damage or trauma is caused to the facial nerve, it usually affects only one side of the face.²⁶ Electrochemical signals sent from the brain to these muscles run along the facial nerve. If the facial nerve is disturbed, no signal can penetrate these muscles and depending on how many nerve fibers are in the involved facial nerve, half the affected face experiences muscle weakness or paralysis and this is what is known as Bell's Palsy.²⁶ People with Bell's Palsy are distracted by normal facial actions and functions such as closing their eyes, eating, smiling and uttering their utterance. Other symptoms present include eye tearing, loss of taste, unclear speech, sensitivity to sound, facial paralysis and saliva. This condition occurs suddenly, and usually peaks within 48 hours.²⁷ Bell's Palsy affects about 40,000 people in the United States each year. Bell's Palsy is more common in young adults, older people, diabetics and pregnant women. Children are not immune to it but they tend to recover very well. Generally there are no other medical risks associated with this condition but the development of Bell's Palsy during pregnancy can be attributed to the development preeclampsia.²⁷

CASE ILLUSTRATION

A 31-year-old Post Cesarean Section Women complained of yellow eyes since 3 days ago. Patients also complained of itching all over the body. Complaints of itching all over the body appear along with the appearance of yellow body and yellow eyes. She was pregnant with gestational age was 39-40 weeks when she admission to the hospital. She had normal labor when she had her first pregnancy and she didn't complaint yellow eyes or yellow body when she got first pregnancy. From Physical examination, we found icteric sclerae and anemia conjunctiva with decrease of haemoglobin level (9.3 g/dL) and hiperbilirubinemia mainly direct (9.16 mg/dL). Increase of transaminase level happened with AST/ALT level (199/105U/L). Increase of ureum and creatinin level was 103.90/5.45 mg/dL or azotemia renal. Hypoglicemia was happened. Hypoalbuminemia with 2.38 mg/dL happened too. Prolonged APTT level with 56.70 (control 25).

Patient was initial diagnosis with Gravid trimester 3 with increased transaminase azotemia+ hypoglycemia + prolonged APTT suspect dt Intrahepatic cholestasis of pregnancy differential diagnosis with AFLP and HELLP syndrome. At initial therapy, patient administrated with immediately Cesarean section. Patient was given oxygenation, D20 % 100 cc, UDCA 250 mg and FFP Transfusion. Patient was planning diagnosis with Hepar biopsy and Fibroscan. After Cesarean section, patient administrated with giving metilprednisolone 62.5 mg intravenous a day. At second day post partum, patient complaint with her mouth had deviation to the left side. And her left eye couldn't close and and wink. From neurology status, there was Parese N VII D LMN type house bruckmann 4. Patient was diagnosed with Bell's Palsy Partum.

Patient administrated with acyclovir 500 mg and B6 vitamin 25 mg. Metilprednisolone intravenous continued until seven days. After 7 days, patient was in stable condition and without any complaint. Patient was planned for hepar biopsy and fibroscan. Result from Pathology Anatomy was cholestasis intrahepatal. It showed fibrosis periportal appearance. The diagnosis of cholestasis intrahepatal in pregnancy was established. Patient got fibroscan and the result was 8 kpA which is means moderate fibrosis in cholestasis liver.

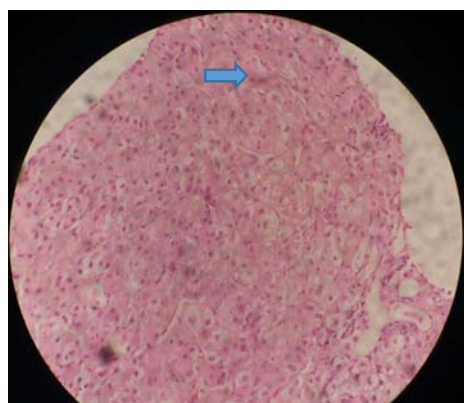


Figure 1. Result From pathology anatomy: cholestasis Intrahepatal. Fibrosis periportal appearance

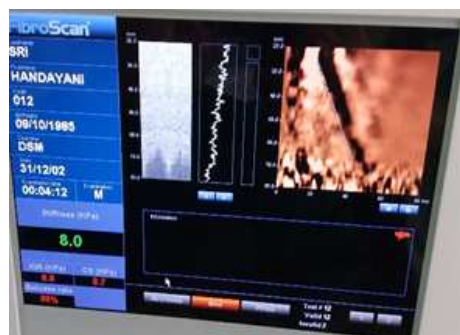

Figure 2. Result of Fibroscan: moderate fibrosis

DISCUSSION

Intrahepatic cholestasis of pregnancy (ICP) is a cholestatic disorder characterized by pruritus, elevated serum aminotransferase and bile acid levels with onset in the second or third trimester of pregnancy. Jaundice usually develops 1-4 weeks after onset of pruritus, but it can sometimes be an early symptom. The etiology that causes ICP can not be understood. Suspected genetic, hormonal, and environmental factors contribute to the pathogenesis of ICP. Suspected mutations in the hepatocellular phospholipid transporter ABCB4 (MDR3), which mediates the secretion of phosphatidylcholine (lecithine) into bile, is thought to be 15% in the case of ICP. Thomas Et al mentions estrogen plays an important role in the incidence of ICP. ICP usually occurs at the end of the trimester when estrogen levels reach maximum levels. This is supported by the tendency of patients using oral contraceptive estrogen. Progesterone also contributes to the pathogenesis of ICP. Patients with ICP were significantly elevated plasma levels of mono or disulfated progesterone metabolites. Some estrogen, glucuronide, and progesterone sulfate metabolites are known to cause cholestasis. In this case, the initial onset of this condition is form of a yellow eyes followed by itching at all over the body. Patients were grvida in the third trimester. Laboratory results showed increased bilirubin, especially direct bilirubin and increased serum aminotransferase that showing signs of cholestasis.

Thomas et al says hydrophilic bile acid ursodeoxycholic acid (UDCA) is the most effective therapy in ICP. An open randomized parallel study, 84 patients with symptomatic ICP were randomly assigned to UDCA compared with 14 days of cholestyramine. The pruritus symptoms disappeared significantly with UDCA administration and also found to decrease effectively from levels of SGOT/SGPT and bile acid levels. A double blind placebo controlled trial comparing UDCA administration (1 g/day for 3 weeks) and dexamethasone (12 mg per day for 1 week) in 130 women with ICP significantly improved serum aspartate aminotransferase (AST)/alanine aminotransferase (ALT) and bilirubin levels on UDCA administration. UDCA appears to have a tolerant impact on pregnant women and no adverse effects on mothers and babies born. UDCA provides an improvement on the canalular expression of a protein transporter, MRP2 or bile salt exporter that reduces the incidence of cholestasis. In this patient, UDCA 250 mg tablet and methylprednisolone 62.5 mg intravenous were administered.

The maternal prognosis improves and symptoms resolve rapidly after delivery, accompanied by normalized serum liver and bilirubin tests. Delivery is recommended at 37-38 weeks' gestation. In this patient, after delivery in case, sectio caesarea, patient got improvement. Komal et al mentioned that cholestasis in histopathology was characterized by bile pigment in hepatic green liver parenchyma, degeneration of hepatocytes, bile duct proliferation seen from epithelial cell proliferation and presence of periportal neutrophils. Patient got hepar biopsy for established the diagnosis of cholestasis intrahepatal in Pregnancy. The result biopsy is: (1) Hepatocytes are cloudy degeneration; (2) Appearing bile pigment to cytoplasm and canalysis, vague appearance of periortal fibrosis and piecemeal necrosis; (3) Conclusion: cholestasis intrahepatal; fibrosis periportal appearance.

Liver fibrosis as occurs in other organs depends on various factors. The main factor is the extracellular matrix of the organ. Extracellular matrix is a structure that can change shape and structure that channel the power/impact from the outside to the heart. The second factor is the urgings that occur in the liver. The greater the pressure that occurs in the liver, the more fibrosis will occur. The third factor is pressure inside the organs, if blood or other flow comes in and out of the organ, the stiffness/fibrosis will depend on the resistance of the liver to the flow. The fourth factor and important factor is the effect of viscosity/ensity that affects the time constant when fibrosis is examined. And this effect is related to frequency. When the soft heart is with the low frequency it gets, it will become denser with high frequency. Fibroscan is a modality for assessing the magnitude of fibrosis (density or scar tissue of the liver). The result of Fibroscan with normal value limit is 2-7 kPa. The mean normal value is 5.3 kPa With degrees of fibrosis divided by: (1) F0 which means no scarring; (2) F1 which means mild fibrosis; (3) F2 which means moderate fibrosis; (4) F3 which means severe fibrosis; (5) F4 which means cirrhosis or advanced fibrosis.

In this patient the result of fibroscan is 8 kPa for the fibrosis stage that means F2 category or moderate fibrosis in cholestasis liver. Bell's Palsy is more common in young adults, older people, diabetics and pregnant women. In this patient there was a sign of bell's palsy 2 days after the action sectio caesarea. Bell's Palsy causes palsy in the peripheral lower motor neurone area, with clinical manifestations of paralysis of the facial nerve with eye and mouth closure disorders and facial muscle movement disorders. A deficit in

the central UMN can also cause weakness in the face. Patients with facial palsy require careful examination. Grading scale House Brackmann is a documentation for facial palsy Patient suffered from Parese N VII D LMN type house bruckmann 4.

The goal of bell's palsy management is mainly due to HSV's rapid recovery and prevention of corneal complications. Therapy should begin immediately to prevent replication of the virus and prevent prolonged effects that damage the facial nerve. Bell's palsy can be effectively treated with corticosteroids within the first 7 days. A study suggests the benefit of steroid therapy is improvements in outcome obtained after corticostreoid administration within the first 72 hours. An antiviral therapy looks logical in Bell's Palsy due to the possible development of herpes virus. Aciclovir is an analogue nucleotide that inhibits the replication of viral DNA. In this patient, bell's palsy therapy was given Acyclovir 400 mg every 6 hour, Metilprednisolone 16 mg every 6 hour and B6 vitamin 25 mg a day.

Patients was in third trimester of pregnancy. Laboratory results showed increased bilirubin, especially direct bilirubin and increased serum aminotransferase that showing signs of cholestasis. Patient administrated with UDCA 250 mg every 8 hours and metilprednisolone intravenous 62.5 mg a day. After cesarean section, condition of patient was improved significantly. The diagnosis from the patient was established by hepar biopsy that showed cholestasis intrahepatal appearance. Patient got fibroscan and showed moderate fibrosis in cholestasis liver.

Patient was diagnosed as Bell's Palsy Post Partum after sectio caesarea operation. Patient was administrated with Acyclovir, metilprednisolone and B6 vitamin. And the condition of this patient was improved.

REFERENCES

1. Svanborg A. A study of recurrent jaundice in pregnancy. *Acta Obstet Gynecol Scand* 2007;33:434-44.
2. Thorling L. Jaundice in pregnancy; a clinical study. *Acta Med Scand Suppl* 2008;302:1-123.
3. Fisk NM, Bye WB, Storey GN. Maternal features of obstetric cholestasis: 20 years experience at King George V Hospital. *Aust N Z J Obstet Gynaecol* 2006;28:172-6.
4. Johnston WG, Baskett TF. Obstetric cholestasis. A 14 year review. *Am J Obstet Gynecol* 2001;133:299-301.
5. Kater RM, Mistilis SP. Obstetric cholestasis and pruritus of pregnancy. *Med J Aust* 2010:638-40.
6. Reyes H, Gonzalez MC, Ribalta J, Aburto H, Matus C, Schramm G, Katz R, Medina E. Prevalence of intrahepatic cholestasis of pregnancy in Chile. *Ann Intern Med* 2006;88:487-93.

7. Reyes H, Taboada G, Ribalta J. Prevalence of intrahepatic cholestasis of pregnancy in La Paz, Bolivia. *J Chronic Dis* 2005;32:499-504.
8. Steel R, Parker ML. Jaundice in pregnancy. *Med J Aust* 2004;1:461.
9. Eloranta ML, Heinonen S, Mononen T, Saarikoski S. Risk of obstetric cholestasis in sisters of index patients. *Clin Genet* 2001;60:42-5.
10. Gonzalez MC, Reyes H, Arrese M, Figueroa D, Lorca B, Andresen M, Segovia N, Molina C, Arce S. Intrahepatic cholestasis of pregnancy in twin pregnancies. *J Hepatol* 2007; 9:84-90.
11. Heinonen S, Kirkinen P. Pregnancy. Outcome with intrahepatic cholestasis. *Obstet Gynecol* 2004;94:189-93.
12. Jiang ZH, Qiu ZD, Liu WW, Liu YH, Wang QN, Miao HZ, et al. Intrahepatic cholestasis of pregnancy and its complications. Analysis of 100 cases in Chongqing area. *Chin Med J* 2008;99:957-60.
13. Laatikainen T, Ikonen E. Fetal prognosis in obstetric hepatosis. *Ann Chir Gynaecol Fenn* 2007;64:155-64.
14. Lo TK, Lau WL, Lam HS, Leung WC, Chin RK. Obstetric cholestasis in Hong Kong--local experience with eight consecutive cases. *Hong Kong Med J* 2007;13: 387-91.
15. Paternoster DM, Fabris F, Palù G, Santarossa C, Bracciante R, Snijders D, et al. Intra-hepatic cholestasis of pregnancy in hepatitis C virus infection. *Acta Obstet Gynecol Scand* 2002;81:99-103.
16. Perreau P, Rouchy R. Recurrent cholestatic jaundice of pregnancy. *J Gynecol Obstet* 2005;60:161-79.
17. Rath U, Bapat M, Rath P, Abraham P. Effect of liver disease on maternal and fetal outcome-a prospective study. *Indian J Gastroenterol* 2007;26:59-63.
18. Rioseco AJ, Ivankovic MB, Manzur A, Hamed F, Kato SR, Parer JT, et al. Intrahepatic cholestasis of pregnancy: a retrospective case-control study of perinatal outcome. *Am J Obstet Gynecol* 2004;170:890-5.
19. Roger D, Vaillant L, Fignon A, Pierre F, Bacq Y, Brechot JF, et al. Specific pruritic diseases of pregnancy. A prospective study of 3192 pregnant women. *Arch Dermatol* 2005;130:734-9.
20. Roncaglia N, Arreghini A, Locatelli A, Bellini P, Andreotti C, Ghidini A. Obstetric cholestasis: outcome with active management. *Eur J Obstet Gynecol Reprod Biol* 2002;100:167-70.
21. Wójcicka-Jagodzińska J, Kuczyńska-Sicińska J, Czajkowski K, Smolarczyk R. Carbohydrate metabolism in the course of intrahepatic cholestasis in pregnancy. *Am J Obstet Gynecol* 2007;161:959-64.
22. Abedin P, Weaver JB, Egginton E. Intrahepatic cholestasis of pregnancy: prevalence and ethnic distribution. *Ethn Health* 2008;4:35-7.
23. Berg B, Helm G, Petersohn L, Tryding N. Cholestasis of pregnancy. Clinical and laboratory studies. *Acta Obstet Gynecol Scand* 2006;65:107-13.
24. Brites D, Rodrigues CM, van-Zeller H, Brito A, Silva R. Relevance of serum bile acid profile in the diagnosis of intrahepatic cholestasis of pregnancy in an high incidence area: Portugal. *Eur J Obstet Gynecol Reprod Biol* 2004;80:31-8.
25. Glantz A, Marschall HU, Mattson LA. Intrahepatic cholestasis of pregnancy: relationships between bile acid levels and fetal complication rates. *Hepatology* 2004;40:467-74.
26. Brackmann DE, Fetterman BL. Cranial nerve VII: Facial nerve. In: Goetz GC, editor. *Textbook of clinical neurology*. Philadelphia: Saunders Elsevier; 2007.p.185-98.
27. Sullivan FM, Swan IR, Donnan PT, Morrison JM, Smith BH, McKinstry B, et al. Early treatment with prednisolone or acyclovir in Bell's palsy. *N Engl J Med* 2007;357:1598-607.
28. Komal A, Chan AW, Gonzalez RS, Mannan AA. Liver and intrahepatic bile ducts-nontumor Biliary tract disease. Cholestasis. *Pathology Outlines* 2012;x:x-x.