

Histoacryl Glue Injection for Treatment in Patient with Gastric Varices Non-cirrhotic Portal Hypertension

Jualita Heidy Saputri*, Budi Widodo**

*Department of Internal Medicine, Faculty of Medicine
Universitas Airlangga, Dr. Soetomo Hospital, Surabaya

** Division of Gastroentero-hepatology, Department of Internal Medicine
Faculty of Medicine, Universitas Airlangga/Dr. Soetomo Hospital, Surabaya

Corresponding author:

Budi Widodo. Division of Gastroentero-hepatology, Department of Internal Medicine, Dr. Soetomo General Hospital. Jl. Mayjen Prof. Dr. Moestopo No. 6-8 Surabaya Indonesia. Phone: +62-31-5501177; Facsimile: +62-31-5023865. E-mail: subdigestive@gmail.com

ABSTRACT

Upper gastrointestinal bleeding is differentiated based on clinical needs into variceal and non-variceal bleeding. The cause of varices bleeding is portal hypertension, both cirrhosis and non-cirrhosis. Gastric varices occur less than esophageal varices, but the morbidity and mortality rate are high. The following is case report of gastric non-cirrhotic variceal bleeding. The 19-year-old man had hematemesis melena with anemia. After hemodynamic stabilization, gastroesophageal type 2 varices (GOV 2) were found and definitive endoscopic obturation therapy was given by intravarices injection of diluted histoacryl. After the procedure, there were mild and transient side effects, as well as no re-bleeding until the 7th month.

Keywords: gastric varices, histoacryl, glue injection

ABSTRAK

Perdarahan saluran cerna bagian atas dibedakan berdasarkan keperluan klinik menjadi varises dan non-varises. Penyebab terjadinya varises adalah hipertensi portal baik sirosis maupun non-sirosis. Varises gaster lebih sedikit terjadi dibanding varises esofagus, namun tingkat morbiditas dan mortalitasnya tinggi. Berikut laporan kasus perdarahan varises gaster non-sirosis. Laki-laki 19 tahun mengalami hematemesis melena dengan anemia. Setelah stabilisasi hemodinamik didapatkan varises gaster esofagus tipe 2/GOV 2 dan diberikan terapi definitif endoskopi obturasi dengan injeksi intravarises histoacryl terdilusi. Setelah tindakan didapatkan efek samping ringan dan sementara serta tidak didapatkan perdarahan ulang hingga bulan ke7.

Kata kunci: varises gaster, histoacryl, injeksi perekat

INTRODUCTION

Upper gastrointestinal bleeding (UGB) is distinguished by variceal and non-variceal bleeding. Commonly reported causes of UGB are ulcers (31-67%), varices (6-39%), gastroduodenal erosion (2-18%), neoplasms (2-8%), and unidentified sources

(5-14%).^{1,2,3} UGB varices caused by rupture of varices due to portal hypertension (PHT) related to cirrhosis and non-cirrhosis varices which occur in the esophagus and gastric. Management is intended to reduce the occurrence of first/primary and recurrent/secondary variceal bleeding.

In non-cirrhotic portal hypertension (NCPHT), the rate of gastric varices is around 20%, with gastric variceal bleeding occurring only in 25% of patients, but the mortality rate is higher due to control of difficult bleeding, high rates of rebleeding, and the need for blood transfusion more massive.^{4,5,6,7} Gastric varices have large and fast blood flow so that bleeding is more profuse.⁸

Fast and adequate therapy is urgently needed. Endoscopic therapy is done to stop variceal bleeding and as primary and secondary prophylaxis. If endoscopic therapy failed, radiologic intervention or surgery is needed. The first line of gastric varices therapy is injection of cyanoacrylate in varices with the help of endoscopy as well as endoscopic ultrasonography (EUS).⁵ We present the case of non-cirrhotic portal hypertension patient with gastric varices which have bleeding.

CASE ILLUSTRATION

A 19-year-old man, with job as porter, came to the emergency room of Dr. Soetomo Hospital with complaints of defecation and black vomiting. Complaints were felt 1 day ago. Black stools petis-like 2 times, about half aqua glass each time he defecated. Black vomit 2 times, approximately 2 glasses of aqua each vomit, mixed with food. He felt weak and pounding. Seven days ago, patients have the same complaint. He had history of analgesic drug consumption 4 days previously.

On physical examination, there was severe illness, general condition looked weak, GCS 456. Blood pressure 110/60 mmHg, tachycardia (pulse 128 x/minute, regular rhythm, enough strength), conjunctival anemic, nasogastric tube (NGT) with no hematin production. Lien Schnuffer 1 Hacket 1, liver is not palpable, no ascites. The extremities are warm, dry, and red. There is no edema, nor palmar erythema and petechiae. From digital rectal examination, it was obtained grade 4 internal hemorrhoids, with black blood on the medical glove.

Laboratory tests found Hemoglobin (Hb) 5.3 g/dL, mean corpuscular volume (MCV) 101.6 fL, mean corpuscular hemoglobin (MCH) 33.7 pg, aspartate aminotransferase (AST) 43 U/L, alanine aminotransferase (ALT) 29 U/L, albumin 4.0 g/dL, total protein 7.1 g/dL, direct bilirubin 0.56 mg/dL, total bilirubin 1.3 mg/dL, partial thromboplastin time (PPT) 12.5 seconds (control 11.7 seconds), activated partial thromboplastin time (APTT) 26.4 seconds (control

24.5 seconds), Hepatitis B surface antigen (HBsAg) non-reactive (< 0.002). In abdominal ultrasound, there are no visible liver parenchymal abnormalities, splenomegaly with decreased portal flow and dilated portal veins.

Diagnosis of the patient is hematemesis melena ec suspect of variceal bleeding in non-variceal bleeding with anemia. Patient was planned for endoscopy, protein electrophoresis, hepatitis C virus markers, and fibroscan. Patient was treated with transient fasting, NGT (+), Asering infusion 21 drops per minute, Lansoprazole bolus injection of 2 ampoules continued with continuously 6 mg/hr, transfusion of packed red blood cells (PRC) 1 colf/day until Hb > 8 gr/dL. Vital signs was also monitored.

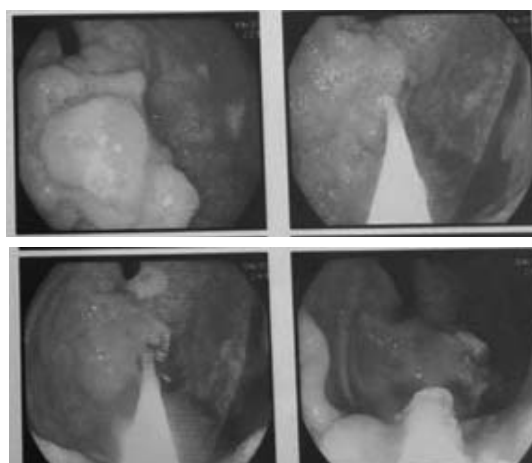


Figure 1. Endoscopic image of GOV 2 gastric varices

The serum protein electrophoresis result showed no abnormalities. Fibroscan obtained 11.2 Kpa. Non-reactive anti-HCV was found. Gastroscopy was done with result of grade 2 esophageal varices and fundus variance (GOV 2) accompanied by congestive gastropathy. Patient was given histoacryl intra-varices injection in fundal varices.

Post-injection, patient was evaluated and there were no complaints of chest pain, tightness, or bleeding

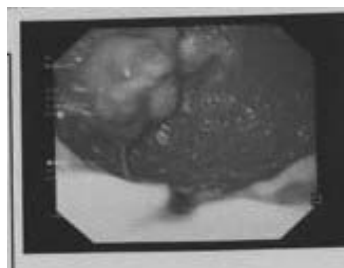

Figure 2. Endoscopic image of post injection of histoacryl intra-varices

found. Patient was given additional therapy in the form of oral Propranolol 3 x 10 mg and Lactulose 1 x 15 mL, the patient was treated as outpatient. One week later, when repeated gastroscopy evaluation was done, esophageal varices and fundal varices were reduced. During follow up to the patient in 1 month and 7 months post-procedure, no complaint was found.

DISCUSSION

Upper gastrointestinal bleeding related to varices is caused by rupture of varices in PHT both in cirrhosis and non-cirrhosis. The diagnostic criteria for non-cirrhosis PHT according to the Asia Pacific Association for the Study of the Liver (APASL) are moderate to severe splenomegaly; portal hypertension, varices, and/or collateral; spleno-portal axis and patent hepatic vein on Doppler ultrasound; normal or near normal liver function tests; normal or near normal hepatic venous pressure gradient; liver histology without signs of cirrhosis or liver abnormalities. In addition, there are additional criteria in the form of no sign of liver chronicity; no decompensation after variceal bleeding except transient transient ascites; no hepatitis B or C virus markers; there was no known etiology of portal vein with peripheral thinning and hyperechoic periportal area.⁹

In PHT without signs of hepatic parenchymal dysfunction, there can be found non-cirrhotic portal fibrosis (NCPF, hepatic vein and patent portal vein) and extra hepatic portal vein obstruction. Biopsy confirmation is needed to exclude the possibility of hepatic cirrhosis, which can now be replaced by a fibroscan examination.^{10,11} From the anamnesis of patients, history of vomiting of blood and black stool without swelling in the stomach or legs can be found. From the physical examination splenomegaly without ascites and palmar erythema can be found. Ultrasound examination revealed splenomegaly with portal vein dilation and decreased portal flow, non-reactive HBsAg, non-reactive Anti-HCV, and unknown etiology of liver disease, fibroscan 11.2 kPa but cannot be interpreted.

According to APASL, around 10-30% of all cases of variceal bleeding are caused by NCPF. It is often occurs in young men in the third to fourth decades and low socioeconomic groups.⁹ This is in accordance with the patient's condition, a 19-year-old male with job as a porter.

The classification of gastric varices according to Sarin is distinguished by location and esophageal

involvement. Gastroesophageal type 1 varices (GOV1) involves the esophagus that extends to gastric minor curvatura, 2-5 cm below the gastroesophageal border. Gastroesophageal type 2 varices (GOV2) involves the esophagus until the gastric fundus. Isolated gastric varices type 1 (IGV1) does not involve the esophagus, varices in the gastric fundus. Isolated gastric varices 2 (IGV2) ectopic varices in the antrum, body and around the pylorus. The prevalence of GOV1 is 75%, GOV2 is 21%, IGV1 is less than 2%, and IGV2 is 4%. The incidence of variceal bleeding was highest in GOV2 and IGV2 types. In addition, gastric varices are divided into primary (without a history of endoscopic therapy) and secondary (with a history of endoscopic therapy).^{5,6} In the patient, it was found GOV2 and primary varices. Gastric varices include submucosa under the gastric mucosa and the muscularis layer, relatively thicker than the esophagus so that bleeding is more difficult to control and difficult to distinguish from gastric rugae. Gastric varices get vascularization from the left gastric vein, gastrosplenic shunt, posterior gastric vein, and short gastric vein making it difficult for bleeding control.^{5,7,12,13}

Management of therapy for gastric varices patients includes intensive care, hemodynamic stabilization, treating acute bleeding, preventing recurrent bleeding, and primary and secondary prophylaxis. Hemodynamic stabilization was performed in patient with crystalloid fluid (0.9% NaCl infusion) and packed red cell/PRC transfusion until hemoglobin levels ≥ 8 gr/dL. The use of somatostatin or vasopressin can still be used in the case of GOV1 which treated as esophageal varices. The use of beta blockers can reduce the incidence of recurrent bleeding. Patients get propranolol with the aim of reducing portal vein pressure to prevent rebleeding. The use of balloon tamponade, Linton-Nachlas tube, is as an intermediary therapy towards definitive therapy. This tamponade is maximally used for 24 hours in massive bleeding conditions, unstable hemodynamics, and blood-covered endoscopic visual field.^{5,6,13}

Definitive therapy of gastric varices includes endoscopic therapy, radiological intervention therapy, or surgical therapy. Endoscopic therapy is divided into endoscopic sclerotherapy (EVS), endoscopic obturation (EVO), and endoscopic ligation (EVL). EVS uses sclerosic materials such as oleic ethanolamine, pure alcohol, or tetradecyl sulfate which causes endothelial damage, thrombosis and varices sclerosis. EVS has a high rate of rebleeding so it is not used as first-line therapy in gastric varices. Intra-varices

thrombin injection uses both bovine and human (more widely used because of fewer side effects than bovine). Thrombin injection converts fibrinogen to fibrin and initiates platelet aggregation so that gastric variceal bleeding stops. Radiological intervention therapy is differentiated into transjugular intrahepatic portosystemic shunt (TIPS), ballon-occluded retrograde transvenous obliteration (B-RTO), and ballon-occluded endoscopic injection sclerotherapy. Radiological interventions are performed when endoscopic therapy has been given but refractory bleeding occurs. If the radiological intervention is still not able to stop variceal bleeding, surgery can be taken both selectively and selectively (involvement of hepatic blood flow).^{5,6,13,14} In the patient, definitive therapy selected is the obturation endoscopic therapy of GOV2-related.

EVO therapy uses n-butyl-2-cyanoacrylate (histoacryl) injection. Cyanoacrylate is a water-soluble monomer which undergoes rapid polymerization in the presence of ionic substances such as those present in blood. Cyanoacrylate is known as an agent of hemostatics. When cyanoacrylate mixes with blood it will solidify in 20 seconds and change varices into thrombosis, which then bleeding stop. This procedure is carried out by endoscopy or EUS. Lipiodol is an oil-soluble contrast agent that can slow the occurrence

of polymerization so that cyanoacrylate does not experience compaction too quickly when mixed with blood. In addition, the use of lipiodol has a contrast effect that can be detected through EUS (fluroscopy). Evaluate of thrombosis after injection is done by pressing the density of varices that have been injected with the end of the endoscope. EVO is a therapeutic choice for gastric varices which experience acute bleeding as well as secondary prophylaxis. 90% of cases undergo hemostasis. EVS can undergo hemostasis in 62% of cases and EVL in 40% of cases. The incidence of rebleeding in histoacryl injection reaches 15% while the other modalities reach 22-25%. Repetition of cyanoacrylate injection can be done in 4 weeks. Repeated bleeding events were evaluated in 1 month, 3 months, 1 year, up to 2 years for the first injection post-treatment.^{5,6,7,15,16} Injections 1-3 times is needed to achieve varices obliteration.^{8,17,18} In the patient, 1.2 mL histoacryl and lipidol (0.5 mL cyanoacrylate: 0.7 mL lipiodol) were intra-varices injected through an endoscopic guide. Evaluation was carried out 1 week post-procedure, the size of varices was reduced so that repeated histoacryl injection was not needed as secondary prophylaxis. Evaluation of endoscopy was carried out again 2 months post-procedure with the size of the varices shrinking and reinjection will be

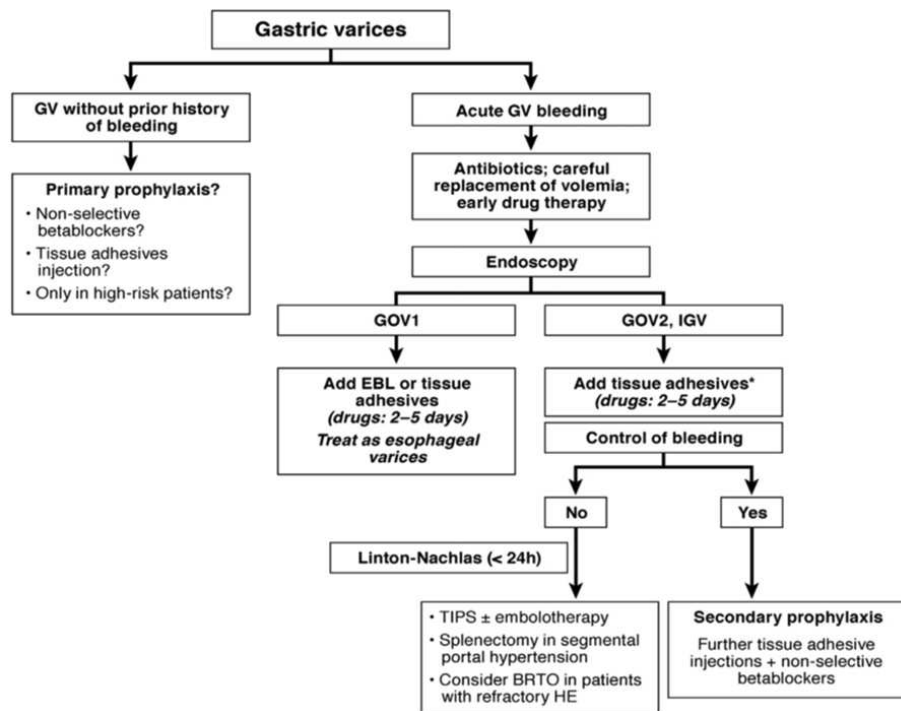


Figure 5. Gastric varices management algorithm¹²

carried out as secondary prophylaxis, but because the ingredients were not in the pharmacy, the procedure was delayed. Endoscopic evaluation in the 7th month post-procedure showed that the size of varices was reduced and there were no bleeding complaints.

Side effects of procedure which can occur are fever (33%) and temporary and mild abdominal pain (17%). In patients, chest and abdominal pain occurred post injection histoacryl. Complaints improved with analgetic administration. Complaints occur mildly and temporarily. Occasional side effects include emboli (0.7%) in cerebral, pulmonary, and splenic. In addition complications can also occur in the form of rebleeding (less than 15%), gastric ulceration (0.1%), visceral fistulae, sepsis (1.3%), and death (10%).^{5,6,13,17,19,20,21}

In conclusion, case of gastric varices have been reported in patient with non-cirrhotic portal hypertension who experience acute bleeding. The definitive therapy used is EVO with intra-varices injection with histoacryl with an endoscopic guide. Patients experienced mild and transient side effects of chest and abdominal pain which can be treated with analgesics. Endoscopic evaluation is carried out at 1 week, 2 months, and 7 months post-procedure. The size of varices was found to be smaller and there was no rebleeding.

REFERENCES

- Alwi, Salim, Hidayat, Kurniawan, Tahaparty. Prosedur di bidang ilmu penyakit dalam, panduan praktik klinis. Jakarta: Interna Publ 2015.p.80-85, 96-99.
- Laine, Loren. Gastrointestinal bleeding. In: Kasper D, Fauci A, Hauser S, eds. Harrisons principles of internal medicine 19th. USA: McGraw-Hill 2015.p.278-9.
- Pangestu, Adi. Buku Ajar Ilmu Penyakit Dalam.4th ed. Jakarta: PAPDI.2016.p.447-2.
- Choksi V, Chokshi B, Chu A, Mandale D, Wolfson DL, Kaplan S, et al. Gastric varices in absence of splenic vein thrombosis: a rare entity of idiopathic non-cirrhotic portal hypertension. *Cur Eus* 2017;9:e1179.
- Ryan, Stockbrugger, Ryan. A Pathophysiologic, Gastroenterologic, and Radiologic Approach to the management of Gastric Varices. *Am Gastroenterol Assoc* 2004;126:1175-89.
- Song, Louis. 2012. Management of Gastric Varices. *Clin Liver Dis* 2012;1:158-62.
- Chang, Hou, Liao, Chen, Lin, Lee, Lee. Management of Acute Gastric Varices Bleeding. *J Chin Med Assoc* 2013;76:539-46.
- Sarin, Mishra. Endoscopic therapy for gastric varices. *Clin Liver Dis* 2010;14:263-79.
- Khanna R, Sarin SK. Non-cirrhotic portal hypertension – diagnosis and management. *J Hepatol* 2014;60:1011-25.
- Kim SU, Seo YS, Cheong JY, Kim MY, Kim JK, Um SH. Factors that affect the diagnostic accuracy of liver fibrosis measurement by fibroscan in patients with chronic Hepatitis B. *Aliment Pharmacol Ther* 2010;32:498-505.
- Bissonnette J, Rautou PE, Valla DC. Idiopathic non-cirrhotic portal hypertension: an update. *Presse Med* 2015;10:1009-15.
- Arakawa, Masuzaki, Okuda. Pathomorphology of Esophageal and Gastric Varices. *Seminars in Liver Disease* 2002;22:73-82.
- Pagan, Barrufet, Cardenas, dan Escorsell. Management of gastric varices. *Clin Gastroenterol Hepatol* 2014;12:919-28.
- Franchis. Expanding Consensus in Portal Hypertension, Report of the Baveno VI Consensus Workshop: Stratifying Risk and Individualizing Care for Portal Hypertension. *J Hepatol* 2015;63:743-52.
- Bathia, Vikram. Endoscopic ultrasound (EUS) for esophageal and gastric varices: how can it improve the outcomes and reduce complications of glue injection. *J Clin Exp Hepatol* 2012;2:70-4.
- Goyal, Sharma. Bleeding after glue injection in gastric varices. *Gastroenterology* 2012;142:e1-e2.
- Saraswati, Verna. Gluing Gastric Varices in 2012: Lessons Learnt Over 25 Years. *J Clin Exp Hepatol* 2012;2:55-69.
- Ang, Seewald, Soehendra. Ebdotherapy of gastric fundal varices: intravariceal injection of N-Butyl-2-Cyanoacrylate. Elsevier GmbH 2013;157-159.
- Prabhu, Kamath. Current staging and diagnosis of gastroesophageal varices. *Clin Liver Dis* 2010;14:195-208.
- Mishra, Sharma, Kumar, Sarin. Primary prophylaxis of gastric variceal bleeding comparing Cyanoacrylate injection and Beta-blockers: a randomised controlled trial. *J Hepatol* 2011;54:1161-7.
- Sarin, Kumar. Endoscopic treatment of gastric varices. *Clin Liver Dis* 2014;18:809-27.