

# Intralesion Triamcinolon Injection Therapy on Esophageal Stricture as Side Effect of Long Term Use Biphosphonate

Arles, Yoanda Silvia

Department of Internal Medicine, Awal Bros Hospital, Pekanbaru

## Corresponding author:

Arles. Department of Internal Medicine, Awal Bros Hospital. Jl. Jendral Sudirman No. 117 Pekanbaru Indonesia. Phone: +62-761-47333; facsimile: +62-761-47222. E-mail: arles\_sppd@yahoo.com

## ABSTRACT

Systemic Lupus Erythematosus (SLE) is a chronic inflammatory disease that affect almost any organ system. Patient with SLE is at risk of osteoporosis. Biphosphonate is one of osteoporosis treatments. However, esophageal stricture (ES) caused by continuous esophageal inflammation as a result of long-term use Biphosphonate can occur. Intralesion Triamcinolone Injection (ITI) becomes one of ES therapy by inhibiting inflammatory response to injury and decrease subsequent collagen formation. ITI inhibits transcription of matrix protein genes, including fibronectin and procollagen. It also reduces the synthesis of  $\alpha_2$ -macroglobulin, an inhibitor of collagenase activity. A 43 year old woman was diagnosed with SLE. She was treated with Risedronic Acid (bisphosphonate class) 35 mg once a week. After 8 months, She started complaining difficulty to swallow. Symptom was getting worse 6 months later. One-third distal ES with inflammation process was found with endoscopy. ITI 150 mg was given in inflammation area. She was scheduled to follow up after 7 days for re-endoscopy. Endoscopy showed that inflammation process had been improved. Six months later, she had again complained difficulty to swallow and we found that she still consumed Risedronic Acid. ITI 150 mg was given because inflammation and ES was found with endoscopy. After 7 days, endoscopy showed that there was no ES and inflammation process had been improved. She was advised to stop Risedronic Acid consumption.

**Keywords:** Intralesion Triamcinolone injection, esophageal stricture, systemic lupus erythematosus (SLE), Biphosphonate

## ABSTRAK

Sistemik lupus eritematus (SLE) adalah penyakit inflamasi kronik yang berefek pada hampir semua sistem organ. Pasien dengan SLE beresiko osteoporosis. Bipozonat adalah salah satu pengobatan osteoporosis. Striktur esofagus (SE) dapat terjadi disebabkan oleh peradangan esofagus hasil dari penggunaan Bipozonat jangka panjang. Injeksi Triamsinolon Intralesi (ITI) menjadi salah satu pengobatan SE dengan menghambat respon inflamasi terhadap cedera dan menurunkan pembentukan kolagen. ITI menghambat transkripsi gen matriks protein yang terdiri atas fibronektin dan prokolagen. ITI juga menurunkan sistesis  $\alpha_2$ -macroglobulin, penghambat aktivitas kolagenase. Pasien wanita 43 tahun didiagnosis dengan SLE. Pasien tersebut diberikan Asam Risedonat (golongan Bipozonat) 35 mg sekali seminggu. Setelah 8 bulan, pasien mengeluhkan kesulitan menelan. Gejala memburuk 6 bulan kemudian. Sepertiga distal SE dengan proses inflamasi ditemukan melalui endoskopi. ITI 150 mg diberikan pada daerah inflamasi. Pasien dijadwalkan untuk datang 7 hari kemudian untuk endoskopi kembali. Endoskopi menunjukkan proses inflamasi membaik. Enam bulan kemudian pasien kembali mengeluhkan kesulitan menelan dan diketahui pasien masih mengkonsumsi asam risedonat. ITI 150 mg kembali diberikan karena SE ditemukan pada endoskopi. Setelah 7 hari kemudian, hasil endoskopi menunjukkan tidak ada lagi SE dan proses inflamasi membaik. Pasien kemudian disarankan untuk berhenti mengkonsumsi asam risedonat.

**Kata kunci:** injeksi Triamsinolon intralesi, striktur esofagus, SLE, Bipozonat

## INTRODUCTION

Systemic Lupus Erythematosus (SLE) is a chronic inflammatory disease that can affect almost any organ system. More than 90% of cases of SLE, occur in woman, frequently starting at childbearing age. Patient with SLE is at risk of osteoporosis through several factors; the inflammatory disease itself and disease related to comorbidity and its treatment (such as corticosteroid). Biphosphonate is one of class agents used to treat osteoporosis which inhibits bone resorption that is impacting bone mineral density increase. However, biphosphonate is a local irritant to the gastrointestinal tract and esophagitis. Moreover, esophageal stricture was reported as side effect of biphosphonate. As triamcinolone has inhibitory effect on inflammatory process and decrease subsequent

collagen formation, triamcinolone to treat esophageal stricture has been applied.

## CASE ILLUSTRATION

A 43 year old woman was diagnosed with SLE and due to osteoporosis, She was treated with Risedronic Acid (bisphosphonate group) 35 mg once a week. After 8 months of treatment, She started complaining difficulty to swallow. There is no history of tobacco, alcohol and NSAID use before and she was hemodynamically stable. 6 months later, the symptom was getting worse and one-third distal esophagus stricture with inflammation process was found with endoscopy. Intralesion triamcinolone injection 150 mg was given in inflammation area. She was scheduled to follow up after 7 days for re-endoscopy. The endoscopy

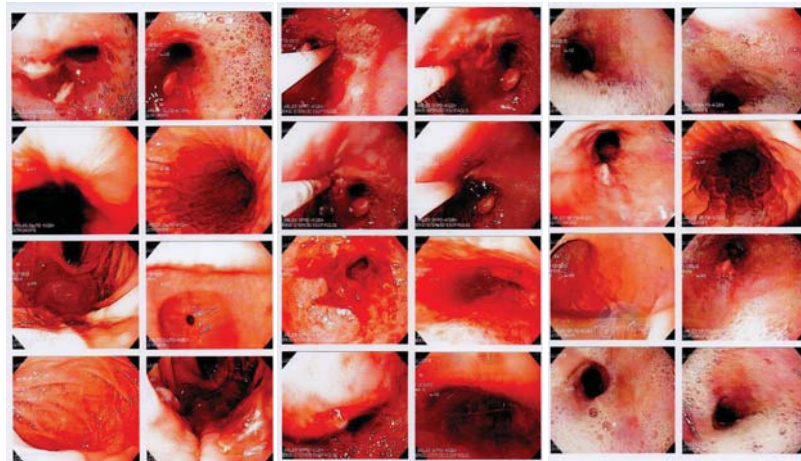


Figure 1. Endoscopy result (December 2015): one third distal esophageal stricture with inflammation process (left) First intralesion triamcinolone injection was given (middle) inflammation had been improved (right)

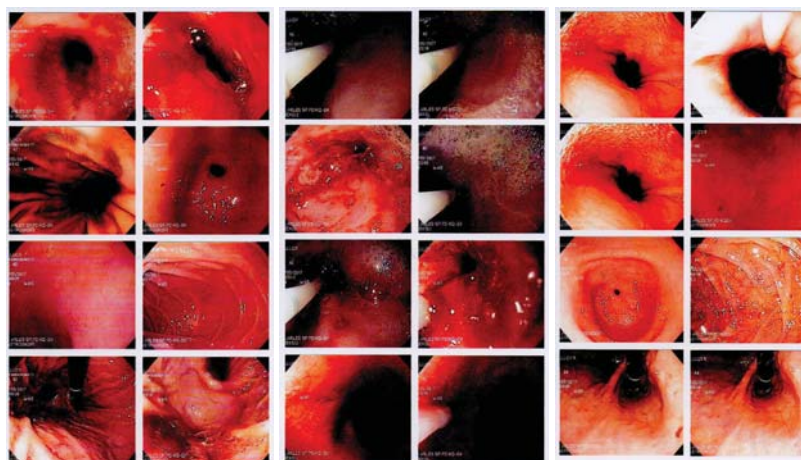


Figure 2. Endoscopy result (May 2017): one third distal esophageal stricture with inflammation process (left) second intralesion triamcinolone injection was given (middle) there is no stricture and inflammation had been improved (right)

results after the re-examination showed that the inflammation process in esophagus was getting better with triamcinolone injection.

Six months later, she had again complained difficulty to swallow and we found that she still consumed Risedronic Acid. Intralesion Triamcinolone Injection 150 mg was given because inflammation and Esophageal stricture was found with endoscopy. After 7 days, endoscopy showed that there was no stricture esophageal found and inflammation process had been improved. She was advised to stop Risedronic Acid consumption.

## DISCUSSION

Osteoporosis is a systemic skeletal disorder characterised by low bone mass and microarchitectural deterioration of bone tissue, with a consequent increase in bone fragility and susceptibility to fracture. Etiology of osteoporosis in SLE patient are disease activity, reduced sunlight exposure that result abnormal vitamin D metabolism, and glucocorticoids and cytotoxic drugs for treatment ovarian dysfunction may have detrimental effect on bone mineral density.<sup>1</sup>

Bisphosphonate is used as osteoporosis treatment. Bisphosphonate increases bone density by selectively suppress osteoclast activity with relative preservation (at least initially) of osteoblast activity. However, because of there is GIT site effect, the use of bisphosphonate must be thorough. The association

between bisphosphonate and esophageal may result in adverse effects such as acute esophagitis caused by direct contact of drug with esophageal mucosa. Esophageal stricture caused by continuous esophageal inflammation as a result of long-term use can also be occurred.<sup>2,3,4</sup>

Biphosphonate attenuated the hydrophobic surface barrier of the stomach, which normally protects the mucosa from injury by luminal acid and thereby cause mucosal injury. Phosphatidylcholine is one of the phospholipids responsible for the hydrophobic properties of the bilayer. Phosphatidylcholine has demonstrated an ability to protect GI cells from irritating agents. Both bisphosphonates and Phosphatidylcholine are similar in size and molecular structures. When bisphosphonates bind, this prevents Phosphatidylcholine or other protective phospholipids from binding and producing the hydrophobic barrier that protects the epithelial lining from gastric acid.<sup>5</sup>

Esophageal stricture form as the result of injury of esophageal wall with the subsequent development of scar tissue and secondary tissue contraction. The pathogenesis of all benign esophageal strictures except congenital stricture is transmural cellular injury; the inflammation that ensues leads to collagen deposition and fibrosis and ultimately cause a cicatricial narrowing of the lumen. Treatment strategies of benign stricture is to: (1) Establish patency of esophageal lumen; (2) Disrupt and displace the fibrotic tissue of strictures

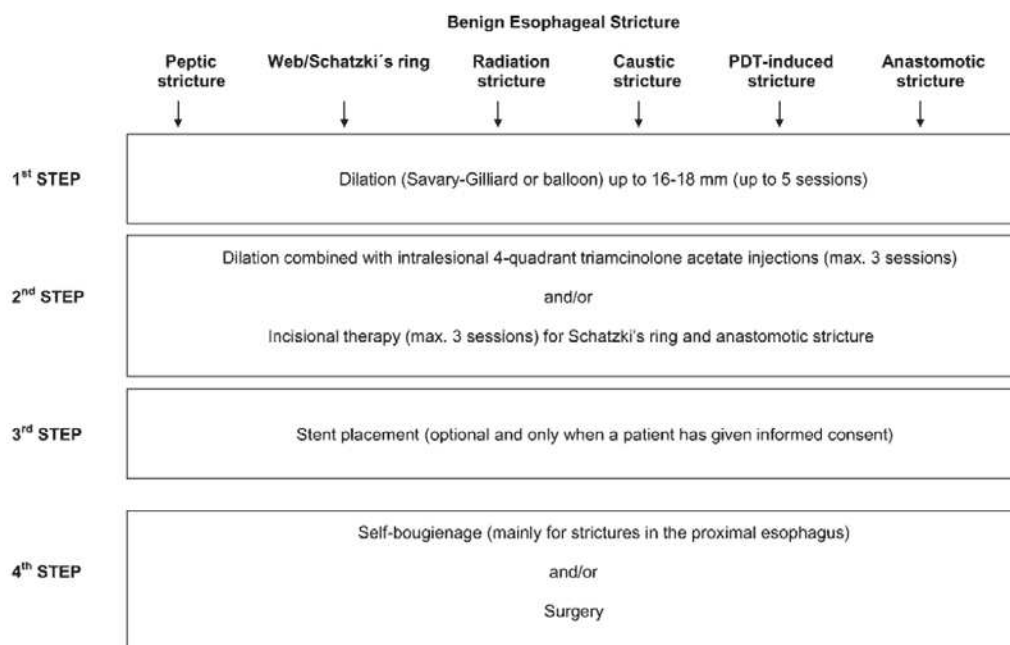


Figure 3. Treatment Algorithm of Esophageal Stricture (Siersema, 2009)

to restore a satisfactory diameter of the lumen; (3) Minimize or prevent reorganization of the fibrotic tissue; (4) Minimize or prevent ongoing cellular injury.<sup>6</sup>

Treatment of esophageal strictures aims to relieve symptoms of dysphagia, with avoidance of complications and prevention of recurrences. The first step in managing a benign esophageal stricture is balloon or Savary-Gilliard dilation, preferably to 16 mm or to 18 mm. The recommendation to perform at least 5 dilations to the maximum diameter before deciding to switch to an alternative treatment is usually attempted. this treatment management is recommended to be performed in dilation frequencies of once per week or even twice per week.<sup>7</sup>

After maximum dilation, the next step in the management of a refractory benign esophageal stricture is to combine dilation with intralesional steroid. Adding steroid injection to endoscopic dilation into stricture has been reported to prevent stricture recurrence. Stent placement is a treatment option to consider when an adequate luminal diameter has not been established with previous treatment modalities or when the stricture still recurs within a short time interval. An alternative treatment option is to teach the patient self-bougienage using Maloney dilators. This is not a commonly performed practice, but self-bougienage is safe and effective when patients have sufficiently learned the technique, and this can be useful in selected patients who are not afraid of performing the procedure. Ballon Dilation is not performed in these patient as it increases the risk of esophageal perforation.<sup>7,8</sup>

On the basis of successful injection treatment for dermatologic scars such as keloids and burn scars, intralesional injection of corticosteroids has been practiced in refractory esophageal strictures of various etiologies for the last 40 years. It has been shown that triamcinolone inhibits inflammatory response to injury and decrease subsequent collagen formation. Intralesional triamcinolon injections inhibit esophageal stricture formation by interfering with collagen synthesis, fibrosis, and chronic scarring processes. Triamcinolone inhibits the transcription of matrix protein genes, including fibronectin and procollagen. It also reduces the synthesis of  $\alpha$ 2-macroglobulin, an inhibitor of collagenase activity.<sup>4,9,10</sup>

## REFERENCES

1. Sen D, Keen RW. Osteoporosis in systemic lupus erythematosus: prevention and treatment. *Sage Journals* 2001;10:227-32.
2. Drake MT, Clarke BL, Kosla S. Bisphosphonates: mechanism of action and role in clinical practice. *Mayo Clin Proc* 2008;83:1032-45.

3. Paul AK, Seetheraman M. Esophageal stricture associated with alendronate use. *CMAJ* 2011;183:E429.
4. Altintas E, Kacar S, Tunc B, et al. Intralesion steroid injection in benign esophageal strictures resistant to Bougie dilation. *J Gastroenterol Hepatol* 2004;19:1388-91.
5. Khapra AP, Rose S. Drug injury in the upper gastrointestinal tract: effect of Aledronate. *gastrointestinal endoscopy clinics of North America*. 2006.
6. Groth SS, Odell DD, Luketich JD. Esophageal strictures refractory to endoscopic dilatation. *Gastrointest Surg* 2015;x:xx-xx.
7. Siersema PD, Wijkerslooth LRH. Dilation of refractory benign esophageal stricture. *Gastrointest Endosc* 2009;70:1000-12.
8. Petra GA, Beckel V, Siersema PD. Refractory esophageal stricture: what to do when dilation fails. *Curr Treat Options Gastroenterol* 2015;13:47-58.
9. Kochhar R, Poornachandra KS. Intralesional steroid injection therapy in the management of resistant gastrointestinal strictures. *World J Gastrointest Endosc* 2010;2:61-8.
10. Ramage JJ, Rumalla A, Baron TH, et al. A prospective, randomized, double blind, Placebo-controlled trial of endoscopic steroid injection therapy for recalcitrant esophageal peptic strictures. *Am J Gastroenterol* 2005;100:2419-25.