

Etiological Causes of Intrahepatic and Extrahepatic Bile Duct Dilatation

Yunfu Lv, Wan Yee Lau, Haiying Wu, Shunwu Chang, NingLiu, Yejuan Li, Jie Deng

Abstract— This study aims to review the causes of intrahepatic and extrahepatic bile duct dilatation. Based on review of medical literature, a scientific classification of the causes is proposed. Intrahepatic and extrahepatic bile duct dilatation can be divided into two categories: congenital and acquired. The former includes the five classical Todani's congenital types. The latter can be sub-classified according to the underlying pathogenesis, the relationship with bile duct lumen/wall/extralumen, or intrabiliary pressure.

Index Terms— Bile duct dilatation; etiologic classification; diagnosis.

I. INTRODUCTION

In modern medicine, the bile duct is considered as an important organ, rather than simply a duct [1]. The condition of the bile duct, directly or indirectly, affects the function of the liver and other vital organs. The normal common bile duct measures <8 mm in diameter in adults, 1 mm in newborns, <3 mm in infants, and <5 mm in children. A common bile duct diameter ≥ 8 mm at its widest point in adult is considered as common bile duct dilatation. A diameter of 8-12 mm is called mild, 12-16 mm moderate, 16-20 mm severe, and >20 mm extremely severe dilatation.

The common hepatic duct with the left and right hepatic ducts, the sectional bile ducts, and segmental bile ducts are called level-1, -2, and -3 bile ducts, respectively. The biliary tree exhibits a dendritic distribution [2]. Normally, the diameter of the right hepatic duct is 3.5 mm and the left hepatic duct 3.3 mm. When the diameter of the left or right hepatic duct exceeds the normal range, and/or with widening of the level-2 and -3 bile ducts, the condition is called intrahepatic bile duct dilatation. An intrahepatic bile duct diameter of 5 mm is called mild, 5-9 mm moderate, and >9 mm severe dilatation.

Intrahepatic and extrahepatic bile duct dilatation is common in clinical practice [3]. In addition to congenital and acquired factors like bile duct stones, parasites, and bile duct wall tumor, there are other uncommon causes of intrahepatic and extrahepatic bile duct dilatation. A comprehensive understanding of intrahepatic and extrahepatic bile duct

dilatation is necessary. In general, extrahepatic bile duct dilatation occurs before intrahepatic bile duct dilatation. However, hilar or intrahepatic lesions can cause intrahepatic bile duct dilatation without any extrahepatic bile duct dilatation. In this review, the causes of intrahepatic and extrahepatic bile duct dilatation are classified based on their etiological causes.

II. CLASSIFICATION AND ETIOLOGICAL DIAGNOSIS

Intrahepatic and extrahepatic bile duct dilatation can be divided into two categories: congenital and acquired.

A. Congenital intrahepatic and extrahepatic bile duct dilatation (cyst) is a rare congenital malformation [4, 5]. It was first described by a German Abraham Vater in 1713, then a British Todd in 1817, and an American Douglas in 1852. Subsequently, reports came from many other countries. In 1958, Alonso-Lej and his associates from America classified congenital common bile duct dilatation into three types: - cystic dilatation of common bile duct, diverticulum of common bile duct, and cyst of the terminal common bile duct [6]. A French Caroli described in 1959 multiple cystic dilatation in the intrahepatic bile duct (called Caroli's disease) [7, 8], Flanigan in 1965 added two more types: - the type with both intrahepatic and extrahepatic bile duct dilatation, and the type with intrahepatic but no extrahepatic bile duct dilatation, to the original three types to propose a total of five types [9]. In 1977, Todani and his associates [10] modified the classification by Alonso-Lej to include the types described by Caroli and Flanigan (Figure 1). This classification is still recognized and used by international counterparts today.

B. Acquired intrahepatic and extrahepatic bile duct dilatation is also known as postnatal or secondary intrahepatic and extrahepatic bile duct dilatation. It is caused by diseases or acquired conditions.

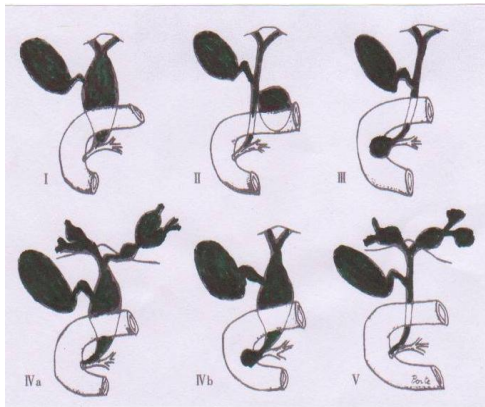
There is no universally accepted classification of acquired intrahepatic and extrahepatic bile duct dilatation. A classification can provide a better understanding of this category of bile duct dilatation.

- i. According to the underlying pathogenesis which include
 - (a) calculus-related dilatation (36%, including bile duct stones, Mirizzi syndrome, and chronic

Yunfu Lv¹, Wan Yee Lau^{1,2}, Haiying Wu¹, Shunwu Chang¹, NingLiu¹, Department of Surgery, the People's Hospital of Hainan Province, Haikou 570311, China.

Wan Yee Lau², Faculty of Medicine, The Chinese University of Hong Kong, Shatin, Hong Kong SAR, China.

Yejuan Li³, Jie Deng³, Hainan University, No. 58, Renmin Avenue, Haikou, Hainan Province, 570228, China



cholecystitis with impacted stone at Hartmann's pouch); (b) compensatory

- I Cystic dilatation
- II diverticulum-like dilatation
- III Cyst of terminal common bile duct
- IVa. Dilatation of both intrahepatic and extrahepatic bile ducts
- IVb. Multiple dilatation of extrahepatic bile ducts
- V Multiple cysts in intrahepatic bile ducts (Caroli's disease)

Figure 1. Todani's modification of Alonso-Lej's classification of bile duct cysts (selected from the book translated by Li Yang and Wang Yi [11])



Figure 2. Proximal bile duct dilatation and bile reflux caused by obstruction of the lower end of bile duct and increased pressure in the bile duct

dilatation (6%, including post-cholecystectomy dilatation, chronic atrophic cholecystitis); (c) parasites-related dilatation (4%, including bile duct ascariasis, bile duct Fasciolopsis, bile duct schistosomiasis, clonorchis sinensis, and hepatic

echinococcosis); (d) inflammatory dilatation (5%, including cholangitis, constrictive papillitis); (e) tumor-related dilatation (24%, including cholangiocarcinoma, periampullary carcinoma, duodenal papillary carcinoma, and gallbladder carcinoma); (f) extrinsic compression pressure-related dilatation (21%, including pancreatic head carcinoma, tumor metastasis around the bile duct, chronic pancreatitis or pancreatic head cyst, peribiliary aneurysm, duodenal bulb ulcers, and parapapillary diverticulitis); (g) injury-related dilatation (2%, including bile duct stricture, and bilioenteric anastomotic stricture); and (h) others (2%, including bile duct bleeding, Oddi's sphincter dysfunction, duodenal obstruction, and ectopic pancreas).

ii. It can be divided into four types according to the relationship with the bile duct lumen/wall/extralumen:

(1) In the lumen: Dilatation is caused by obstruction resulting from stones [12], parasites and other foreign bodies within the bile duct and bile duct parasites [13].

(2) In the bile duct wall: Dilatation is caused by bile duct wall lesions, bile duct injury, or destruction of normal tissue structure of bile duct wall due to inflammation, resulting in stenosis at the lesion site. It includes bile duct polyps, bile duct adenoma [14], bile duct cancer, bile duct papilloma, ductal dilatation caused by ectopic pancreas, chronic cholangitis, periampullary carcinoma, duodenal papillary carcinoma [15], gallbladder carcinoma invasion of bile ducts, bile duct wall hemangioma, bile duct injury, and bilioenteric anastomotic stricture.

(3) Extrinsic compression: Dilatation is caused by compression or traction of the bile duct wall by external lesions. It is commonly found in patients with acute and chronic pancreatitis, pancreatic pseudocyst, pancreatic head carcinoma, parapapillary diverticulum, bile duct compression by metastatic carcinoma, polycystic liver disease [20, 21], duodenal postbulbar ulcer, or peribiliary aneurysm [22].

(4) Other factors: It includes post-cholecystectomy bile duct dilatation [23], and bile duct dilatation caused by other rare causes.

iii. It can be divided into six types according to intrabiliary pressure:

(1) Increase in intrabiliary pressure-related dilatation: Dilatation is caused by increased pressure in the bile duct (Figure 2) due to distal bile duct obstruction from any cause [24, 25] resulting in proximal bile duct dilatation and obstructive jaundice [26]. This type of dilatation is commonly found in patients with bile duct cystadenoma and cystadenocarcinoma [27, 28], sand-like stones, conical stones, impacted stones, tumors, bile duct diaphragm, or ectopic pancreas.

(2) Expansion-related dilatation: It is the gradual dilatation of the bile duct during stone formation and expansion without obstructive jaundice (Figures 3-5). In this case, there are many formed stones or parasites within the bile duct lumen. The bile can flow through the gaps between the

stones or parasites into the duodenum. Bile duct pressure is not high or just slightly increased, but below the obstructive jaundice threshold of 20 mmHg = 2.94 kpa^[29]. Common bile duct dilatation reported in the literature mostly fall into this type.

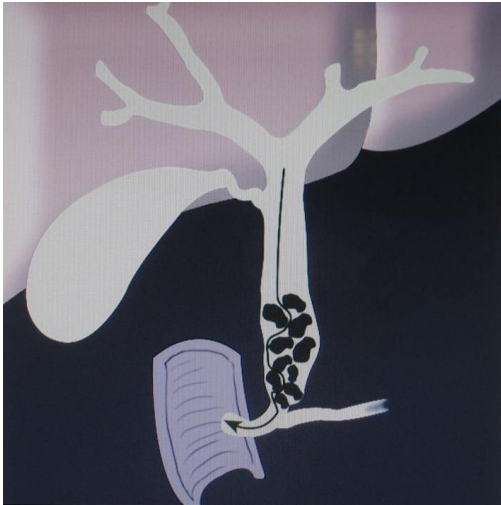

Figure 3. Bile duct dilatation caused by stones in the common bile duct, with bile flowing through the gaps, no high bile duct pressure, and no jaundice

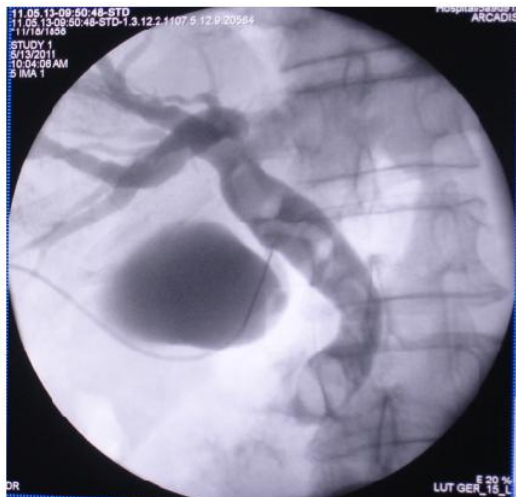



Figure 4. Intranoperative cholangiography revealed that a common bile duct filled with stones had a diameter of 20 mm, but no jaundice was present

(3) Compressive dilatation: It is the dilatation of the proximal bile duct caused by compression of the distal bile duct with bile duct pressure varying at different levels, and fluctuating jaundice is present clinically. This type of dilatation is commonly found in patients with a stone acting as a ball valve in the lower end of the common bile duct, sloughing tumors in the bile duct, pancreaticoduodenal aneurysm, acute and chronic pancreatitis [30], pancreatic cysts (Figure 6).



(4) Infectious dilatation: Dilatation is caused by increased bile duct pressure (normal pressure in remission) or bile duct
Figure 5. A common bile duct filled with stones had a diameter of 25 mm, but no jaundice was present

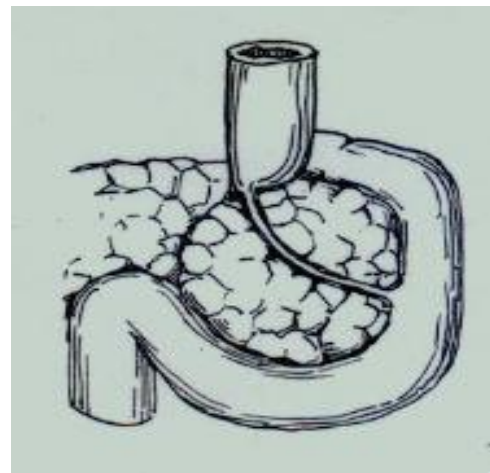

Figure 6. Intrapaneatic bile duct was compressed into a line by cyst of the head of pancreas

wall thickening as a result of poor drainage of bile due to repeated infections of bile duct. This type of dilatation is commonly found in patients with sphincter of Oddi dysfunction, bile duct infection, or pyogenic cholangitis.

(5) Compensatory dilatation: Patients may experience compensatory dilatation of common bile duct after cholecystectomy because the gallbladder bile pool disappears and the buffer storage function is lost. However, these patients seldom undergo investigations without symptoms. Therefore, it is difficult to know the exact number of cases. Chronic atrophic cholecystitis can also cause compensatory bile duct dilatation as a result of lost buffer storage function due to inelastic gallbladder wall.

(6) Adhesive dilatation: After bile duct surgery, adhesion of tissues can cause traction of the bile duct wall, which can lead to bile tract compression (Figure 7) or angulation (Figure 8) in serious cases, thus resulting in proximal bile duct dilatation. This type of dilatation is

commonly found in patients who have had several bile duct surgeries and T-tube drainage

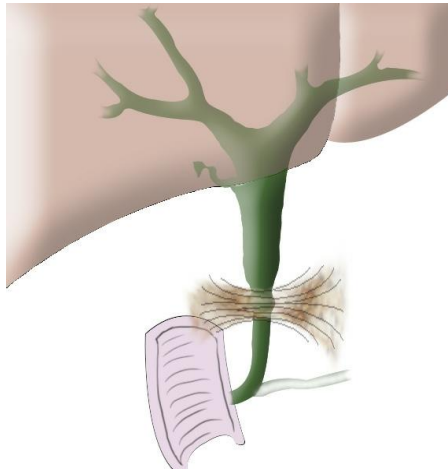
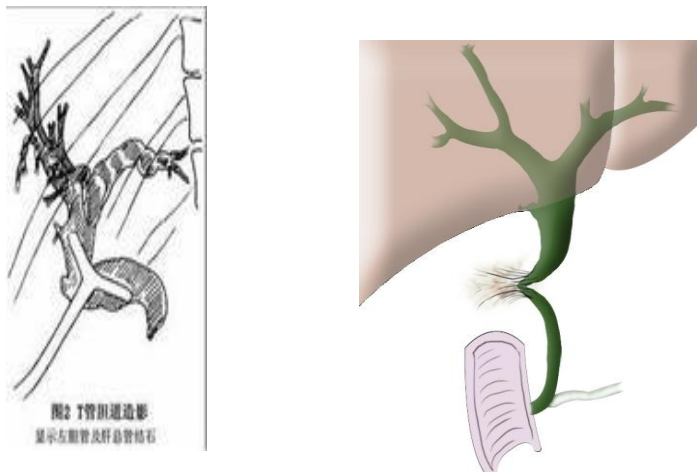


Figure 7. Proximal bile duct dilatation caused by bile duct adhesion and compression after repeated surgery



A. Insertion of T-tube into bile duct B. Adhesion and angulation of bile duct after removal of T-tube

Figure 8. Adhesion and deformation of bile duct after insertion of T-tube

III. CONCLUSION

For more than 60 causes of intrahepatic and extrahepatic bile duct dilatation listed in this paper, they can be divided into the congenital and acquired categories. The latter category can further be sub-classified according to the pathogenesis, relationship with bile duct wall or intrabiliary ductal pressure.

ACKNOWLEDGMENT

This project is funded by the key clinical specialty construction projects of China.

REFERENCES

- [1] Wong ZQ. Development direction of hepatobiliary surgery. *Journal of Surgery Concepts & Practice*, 2011, 16 (4): 329-31.
- [2] Huang JF. *Hepatobiliary and Pancreatic Surgery*. 4th edition. Beijing: People's Health Publishing House, 2010: 81.
- [3] Chaudhary A, Dhar P, Sachdev A, Kumar N, Vij JC, Sarin SK, Broor SL, Sharma SS. Choledochal cysts - differences in children and adults. *Br J Surg*, 1996, Feb;83:186-8. PMID:8689160 [PubMed - indexed for MEDLINE]
- [4] Dowdy GS, Waldron GW, Brown WG. Surgical anatomy of the pancreato-biliary ductal system observations. *Arch Surg*, 1962, 84:229. PMID:13887616 [PubMed - indexed for MEDLINE]
- [5] Okada A, Hasegawa T, Oguchi Y, Nakamura T. Recent advances in pathophysiology and surgical treatment of congenital dilatation of the bile duct. *J Hepatobiliary Pancreat Surg*. 2002;9(3):342-51. PMID:12353145 [PubMed - indexed for MEDLINE]
- [6] Alonso Lej F, Revor WB, DJ. Congenital choledochal cyst, with a report of 2, and an analysis of 94 cases. *Surg Gynecol Obstet*, 1959; 108:1-30
- [7] Caroli J, Soupault R, Kossakowski J, et al. La dilatation congenitale des voies biliaires intrahepatiques. *Sem hop Paris*, 1958; 34:488-95
- [8] Han Xiaoyu, Lv yunfu. Research progress of Caroli's disease. *International Journal of Surgery*, 2010, 37(3):193-6.
- [9] Søreide K, Körner H, Havnen J, Søreide JA. Bile duct cysts in adults. *Br J Surg*. 2004 Dec;91(12):1538-48. PMID: 15549778 [PubMed - indexed for MEDLINE]
- [10] Todani T, Watanabe Y, Narusue M, Tabuchi K, Okajima K. Congenital bile duct cysts: Classification, operative procedures, and review of thirty-seven cases including cancer arising from choledochal cyst. *Am J Surg*, 889044 [PubMed- indexed for MEDLINE]
- [11] Li Y, Wang Y, chief translator. *Diagnosis and treatment of bile duct disease*. Beijing People's Health Publishing House, 2009, 243.
- [12] Kim JH, Kim YS, Kim DK, Ha MS, Lee YJ, Lee JJ, Lee SJ, Won IS, Ku YS, Kim YS, Kim JH.. Short-term Clinical Outcomes Based on Risk Factors of Recurrence after Removing Common Bile Duct Stones with Endoscopic Papillary Large Balloon Dilatation. *Clin Endosc*. 2011 Dec;44(2): 123-8. PMID:22741123 [PubMed]
- [13] Wei JN, Zhu JF. Clinical analysis of 148 cases of pediatric ascariasis. *Journal of Clinical Pediatric Surgery*, 2003, 2 (6): 416-8.
- [14] Koga F, Tanaka H, Takamatsu S, Baba S, Takihara H, Hasegawa A, Yanagihara E, Inoue T, Nakano T, Ueda C, Ono W. A case of very large intrahepatic bile duct adenoma followed for 7 years. *World J Clin Oncol*. 2012 Apr 10;3(4): 63-6. PMID:22574289 [PubMed] PMID:PMC3348183
- [15] Terada T. Non-invasive intraductal papillary neoplasms of the common bile duct: a clinicopathologic study of six cases. *Int J Clin Exp Pathol*; 2012;5(7):690-7.
- [16] Lu FY, Zhang XX, Dong YH. Chronic pancreatitis-induced compressed relative stenosis of the distal common bile duct. *HBPD Int*, 2006, 5(1):119-22.
- [17] Repiso A, Gómez-Rodríguez R, García-Vela A, Pérez-Grueso MJ, Martín R, Romero M, Carrobbles JM. Endosonographic examination of the common bile duct in patients with acute biliary pancreatitis. *Rev Esp Enferm Dig*. 2008 Jun;100(6):337-42. PMID:18752362 [PubMed - indexed for MEDLINE]
- [18] Sakai Y, Tsuyuguchi T, Ishihara T, Yukisawa S, Sugiyama H, Miyakawa K, Kuroda Y, Yamaguchi T, Ozawa S, Yokosuka O. Long-term prognosis of patients with endoscopically treated postoperative bile duct stricture and bile duct stricture due to chronic pancreatitis. *J Gastroenterol Hepatol*. 2009 Jul;24(7):1191-7. PMID:19682193 [PubMed - indexed for MEDLINE]
- [19] Lv Yunfu, Zhu Qinghua, Zhao Ge. The anatomicopathological classification of Terminal stenosis of common bile duct caused by chronic pancreatitis and its treatment. *Chinese Journal of General Surgery*, 2000, 15(7):417-9.
- [20] Everson G, Taylor M, Doctor R. Polycystic disease of the liver. *Hepatology*, 2004;40: 774-82.
- [21] Vauthey JN, Maddern GJ, Kolbinger P, Baer HU, Blumgart LH. Clinical experience with adult polycystic liver disease. *Br J Surg*, 1992;79: 562-5
- [22] Yu YH, Sohn JH, Kim TY, Jeong JY, Han DS, Jeon YC, Kim MY. Hepatic artery pseudoaneurysm caused by acute idiopathic

- pancreatitis. World J Gastroenterol. 2012 May 14;18(18):2291-4. PMID:22611325 [PubMed - indexed for MEDLINE]
- [23] Park SM, Kim WS, Bae IH, Kim JH, Ryu DH, Jang LC, Choi JW. Common bile duct dilatation after cholecystectomy: a one-year prospective study. J Korean Surg Soc. 2012 Aug;83(2):97-101. PMID:22880184 [PubMed]
- [24] Mallet-Guy P. Value of preoperative manometric and roentgenographic examination in the diagnosis of pathological changes and functional disturbances of the biliary tract. Surg Gynecol Obstet, 1952, 94:385-93.
- [25] Dan JS, Wang BH. Preclinical and Clinical Biliary Surgery. Beijing: People's Health Publishing House, 2003, 113-5.
- [26] Wang Bao-chun, LU Yun-fu, Han Xiao-yu. Etiology and classification of cholangiectasis: an analysis of 1098 cases. Zhonghua Gandan Waike Zazhi, 2011, 17(9):752~754
- [27] Ishak KG, Willis GW, Cummins SD, Bullock AA. Biliary cystadenoma and cystadenocarcinoma: report of 14 cases and review of the literature. Cancer, 1977, 39: 322-38.
- [28] Subramony C, Herrera GA, Turbat Herrera EA. Hepatobiliary cystadenoma. A study of five cases with reference to histogenesis. Arch Pathol Lab Med, 1993, 117: 1036-42.
- [30] LU Yun-fu, Wang Bao-chun, Gon Xiao-Guang, Han Xiao-Yu. Correlation among pressure, diameter, and jaundice in acute obstruction of the common bile duct. Zhonghua shiyan waike zazhi, 2011, 28(11):1851~1852
- [31] Aimoto T, Uchida E, Nakamura Y, Yamahatsu K, Matsushita A, Katsuno A, Cho K, Kawamoto M. Current surgical treatment for chronic pancreatitis. J Nippon Med Sch. 2011;78(6):352-9. PMID:22197867 [PubMed - indexed for MEDLINE]