

Nasolabial Pedicle Flap for Reconstruction of a More Distant Defect : A Case Report

Otei O. O, Ozinko M , Ekpo R, Egiehiokhin Isiwere, Amah P

Abstract—This is the management of a 38-year-old female trader. She had a road traffic accident with open fracture of the frontal bone and was received by the accident and emergency doctors and resuscitated before the plastic and orthopaedic surgeons were invited to take over the management. The orthopaedic team applied a neck collar and did investigations to rule out cervical spine injury. The plastic team later used a nasolabial flap to cover the open frontal bone fracture. The patient was satisfied with the outcome of surgery.

Index Terms— Nasolabial Flap, Delay Procedure, Open Fracture, Frontal Bone.

I. INTRODUCTION

The face is the part of the head between the ears and from the chin to the hairline. In bald people the hairline may recede but the extent of the face is taken to be at the expected limit of the hairline. The face is important in both sexes but the female sex is usually more interested in ensuring that the face is as perfect as possible. Reconstruction of defects of the face should therefore be done very carefully. There should be colour and texture match. Besides, scars should be small and preferably hidden along skin creases or contour lines. The choice of surgical procedure in our index patient, the nasolabial flap, has taken all these factors into consideration.

Case history and management: The patient is a 38-year-old trader and a known hypertensive controlled on oral hypoglycaemic agents. She was a front seat passenger in a saloon car that had head on collision with another saloon car. She lost consciousness for six hours and was brought to the accident and emergency department of the University of Calabar Teaching Hospital.

On examination, she was unconscious with a Glasgow Coma Scale of 10/15, the pulse rate was 92 beats per minute, the blood pressure was 150/90mmHg and the respiratory rate was 20 cycles per minute. There was an avulsion wound on the glabella area that measured 6cm by 4cm in the widest dimension with exposed, fractured bone that measures 3cm by 2cm and a laceration that extends from the wound upwards and laterally to the hairline. The left eyebrow was displaced upwards by about 2cm making the features of the face to be distorted.

Otei O. O, Division of Plastic Surgery, Department of Surgery University of Calabar Teaching Hospital, Calabar Cross River State, Nigeria.

Ozinko M, Division of Plastic Surgery, Department of Surgery. University of Calabar Teaching Hospital, Calabar Cross River State, Nigeria.

Ekpo R, Division of Plastic Surgery, Department of Surgery. University of Calabar Teaching Hospital, Calabar Cross River State, Nigeria.

Egiehiokhin Isiwere, Division of Plastic Surgery, Department of Surgery. University of Calabar Teaching Hospital, Calabar Cross River State, Nigeria.

Amah P, Department of Orthopaedics University of Calabar Teaching Hospital, Calabar Cross River State, Nigeria.

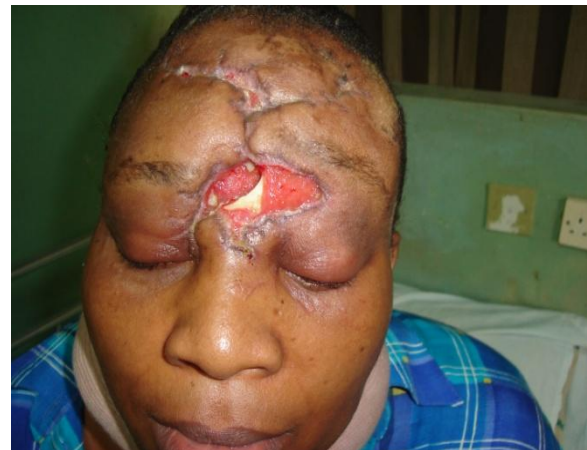

Fig. 1: Pre Operative Picture

The patient recovered consciousness after six hour from the time of accident.

Resuscitation with intravenous fluids, tetanus and antibiotic prophylaxis, haemostasis by gauze and crepe bandage dressing were done in accident and emergency department. Urgent packed cell volume was 30% and urinalysis was unremarkable.

The plastic and orthopaedic surgeons were invited to see the patient. The latter placed a cervical collar on the patient and ordered x-rays of the cervical spine and the chest. The results of x-rays were unremarkable. The plastic surgeons planned to cover the exposed bone with a nasolabial flap.

Reconstruction: The reconstruction was done in three stages namely-

1. Delay procedure.
2. Raising the flap.
3. Flap division and inset.

The delay procedure is necessary because this flap is not normally used to cover defects as distant as the glabellar area^{2,4,5}. This procedure exposes the flap to relative ischaemia and reduces the likelihood of tip necrosis when the flap is raised.

The flap was a 3 cm breadth and 9 cm length of tissue. Two parallel incisions, 3cm apart, were made from the root of the left nasal ala along the nasolabial skin crease and continued lateral to the angle of the mouth with a length of 9 cm and deepened to the subcutaneous tissue. This piece of tissue (the flap) was left attached proximally and distally but an artery forceps was passed between the incisions and moved along the entire length of the flap to bluntly divide the musculocutaneous and septocutaneous vessels that supply the

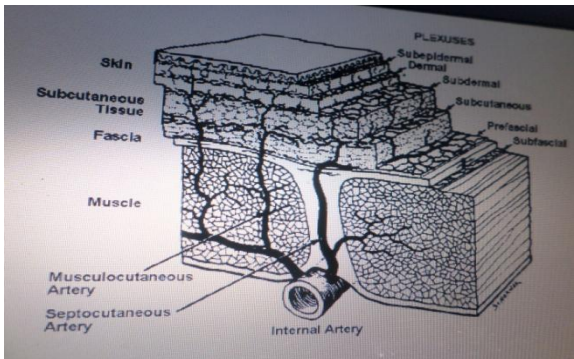


Fig. 2: Musculocutaneous and Septocutaneous Arteries.

Nylon 3/0 sutures were used to close the wounds and this completes the delay procedure.

II. RAISING THE FLAP

Ten days after the delay procedure, all the nylon stitches were removed and the distal end of the flap was divided. The divided end was brought up and sutured to the distal edge of the glabella wound. The flap donor site was closed directly using nylon 3/0 sutures.

III. FLAP DIVISION AND INSET

Two weeks after raising the flap it was divided and used to cover the wound. The patient was discharged from hospital one week after flap division and inset. At the second post operative visit in three months the patient was satisfied with the result of surgery.

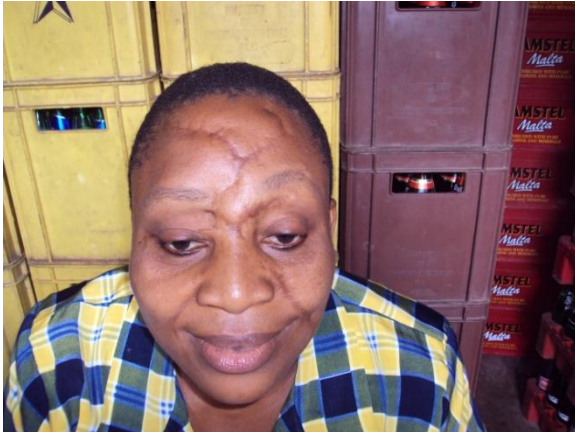

Fig.3: Post Operative Picture

IV. DISCUSSION

Reconstructive surgery of the face, especially in a woman, must be done with utmost care. In this situation the saying, 'from making our treatment worse than the disease, save us o! Lord', is very apt. It is necessary to use tissues with the same texture and colour. Scars should be minimal and if possible masked by skin creases. In our index patient the nasolabial fold was used to attempt to hide the scar. The flap donor site was closed directly; therefore there is minimal donor site morbidity. The breath of the flap was 3cm while the length was 9cm. Therefore the length/breath ratio is 3:1. This is a high ratio and there could be flap loss if an initial stage, flap delay, is not incorporated in the reconstruction 1,6. Flap delay exposes the flap tissues to selective ischaemia

which prepares the tissues to survive reduced blood supply during the raising, division and inset of the flap. Staged procedures may not be necessary where a one stage microvascular free flap can be done. The good blood supply of the tissues of the head and neck has further helped the flap to survive in spite of the high length/breath ratio. It is important to note that most authors believe that this flap can only be used to cover defects on the nose, eyelids and generally in areas less distant than the glabella area of the face^{3,7,9}.

V. CONCLUSION

The nasolabial flap is very useful for reconstruction of defects on the face around the eyelids and nose. Its use to cover lesions on the glabellar area makes it more useful in centres where microvascular free flaps are not available.

REFERENCES:

- [1] William M. Weathers MD1, Erik M. Wolfswinkel BS1, Huy Nguyen MD2, and James F Thorton MD, FACS2. Expanded uses for the nasolabial flap. *Semin Plast Surg.* 2013 May; 27(2):104-109.
- [2] Kroll S.S. Nasal alar reconstruction using the nasolabial turn over flap laparoscope. 1991; 101(10):1127-1131[PubMed].
- [3] Spear S.L, Kroll S.S, Romm S. A new twist to the nasolabial flap for reconstruction of lateral alar defects. *Plast. Reconstr Surg.* 1987;79(6): 915-920[PubMed].
- [4] Silistrel O K, Demirdover C, Ayhan M, Oztan Y, Gorgu M, Ulusal B G. Prefabricated nasolabial flap for reconstruction of full-thickness distal nasal defects. *Dermatol Surg.* 2005 May;31(5):546-52.
- [5] Bouhanna A, Bunt-Rodier C, Himy S, Talmat J C, Bollecker U, Glicksman J, Lutz J C, Kadoch V, Wilk A. Reconstruction of the nasal alar defect with the superiorly based nasolabial flap described by Buquet. *Ann Chir Plast Esthet* 2008 Jan; 53(3):272-7. Epub 2007.Aug.
- [6] Zilinsky I, Alcalay J, Jacobs D, Tamir J, Winkler E, Halk J, Orenstein A. The versatility of the nasolabial flap enhanced by the delay procedure. *Dermatol Surg* 2001Feb;27(2):161-4, PubMed:1107691.
- [7] Jovanovic M, Colic M, Rasulic L, Stojicic M, Malis M. Reconstruction of the alae nasi by folded nasolabial flaps. *Acta Chir lugosl.* 2007;54(2):29-32 Serbian.
- [8] Fujiwar M. One-stage reconstruction of an alar defect using a bilobed nasolabial – nasal tip flap based on the aesthetic subunits in orientals: A case report. *Aesth. Plast Surg.* 2004 Jan-Feb;28(1):13-6. Epub 2004, May 6, PMID 151 29364.
- [9] Rodman R D, Olshansky K. Anatomical alar reconstruction with staged nasolabial flap. *Ann Plast Surg* 1988 Mar 20(3):3285-91. PMID 3358623