

Cervical Laminoplasty with Polypropylene Mesh: Our Experience

Domenico Murrone, Bruno Romanelli, Aldo Ierardi, Gennaro Perrino

Abstract—Cervical laminoplasty was made to reduce the complications of the simple laminectomy. The main indication is degenerative cervical myelopathy with posterior compression to two or more levels. To simplify this procedure with more effectiveness, we conceived a cervical laminoplastica with polypropylene mesh, generally used in abdominoplasty, to provide more resistance during mechanisms of flexion-extension. **MATERIALS AND METHODS:** We analyzed 35 patients (27 males, 8 females) with degenerative cervical myelopathy who underwent surgical treatment at our institution between 2010 and 2015. **RESULTS AND DISCUSSION:** The main duration of surgery was about 90 minutes without intra or post-operative complications. Clinical and radiological follow-up was done at 1, 3 and 6 months, with cervical dynamic Rx and cervical RM at 1one year. There were no complications and 70% of the patients experienced a stable clinical improvement, while in 30% of patients stabilization of clinical deficits. The duration of the superior clinical to one year and the age > of 70 years the more meaningful negative prognostic indicators have appeared. **CONCLUSIONS:** A clinical history more than one year and the age elder than 70 years appear the main negative prognostic factors. The advantage of the laminoplasty is a smaller anatomical damage of the posterior elements without cervical instability, and use of polypropylene mesh provides more resistance during flexion-extension.

Index Terms— Cervical myelopathy; Laminectomy; Laminoplasty, Polypropylene.

I. INTRODUCTION

The surgical treatment of multilevel cervical myelopathy is controversial. Different surgical approaches were proposed and used: multilevel anterior discectomy, multilevel somatectomy, laminectomy with or without posterior fusion and/or arthrodesis and laminoplasty. In 1973 Oyama et al. [1] first described cervical laminoplasty as an alternative to laminectomy connected with many complications. The main indications of this technique are OPLL and degenerative cervical myelopathy with posterior compression to two or more levels [2]-[5].

II. MATERIALS AND METHODS

To simplify this procedure with more effectiveness, we conceived a cervical laminoplasty with use of polypropylene mesh (Fig.1), generally used in abdominoplasty, to provide more resistance during mechanisms of flexion-extension. Polypropylene helps reconstruction and reinforcement of the abdominal wall during surgery of inguinal and incisional hernias increasing muscular and fascial solidity.

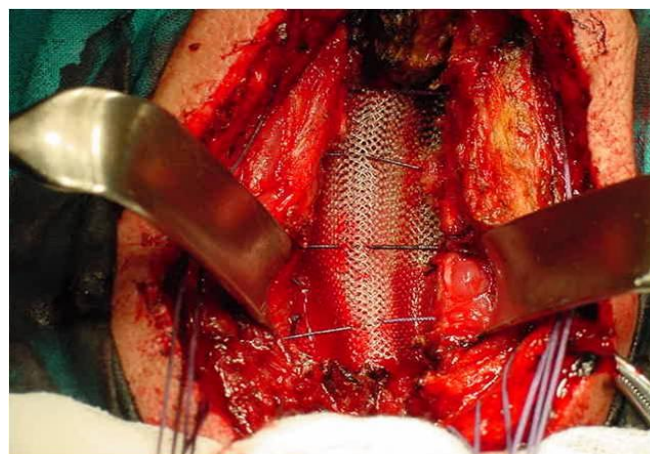

Figure 1: Intraoperative insertion of polypropylene mesh.

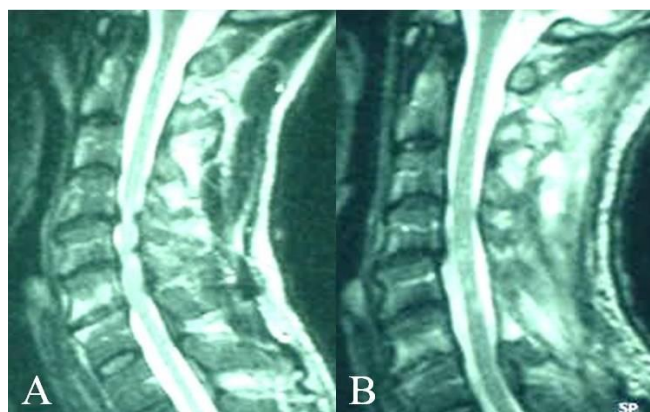


Figure 2: Pre-operative (A) and post-operative (B) sagittal T2 weighted magnetic resonance of cervical spine without contrast showing cervical myelopathy with posterior compression to two or more levels.

We analyzed 35 patients (27 males, 8 females) with degenerative cervical myelopathy who underwent surgical treatment at our institution between 2010 and 2015. All patients underwent pre-operative static and dynamic cervical radiography, cervical MRI without gadolinium and electromyography (Fig.2A). Three patients underwent previously a multilevel anterior discectomy.

III. RESULTS AND DISCUSSION

The main duration of surgery was about 90 minutes without intra or post-operative complications. Clinical and radiological follow-up was done at 1, 3 and 6 months, with cervical dynamic Rx and cervical RM at 1one year (Fig 2B, Fig. 3).

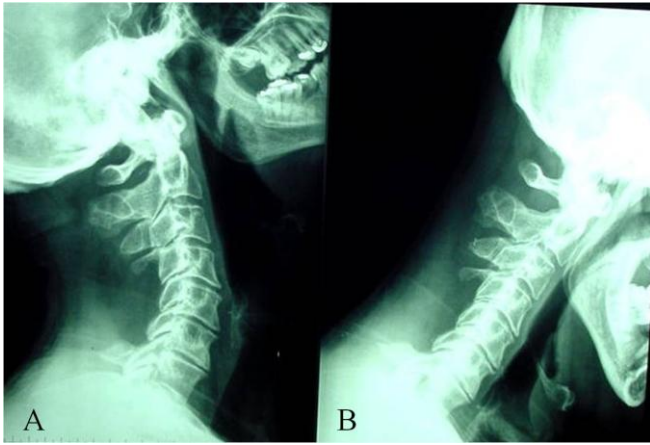


Figure 3: Post-operative dynamic cervical radiography during extension (A) and during flexion (B).

There were no complications and 70% of the patients experienced a stable clinical improvement, while in 30% of patients stabilization of clinical deficits. At two years we have not observed cases of spinal instability, kyphosis or progressive neurological deterioration. The simple cervical laminectomy, well tolerated especially in elderly patients, expose to late complications such as post-operative kyphosis and instability [6]-[8]. Kyphosis and instability of the cervical spine usually are related to simple laminectomy performed in young patients for other pathology (tumor) because of extended facet joint resection [9]. Clinically these complications occur as neurological deterioration after many weeks or months after surgery. Cervical laminoplasty was described by Oyama et al in 1973 to reduce complications related to the simple laminectomy. Cervical laminoplasty is a necessary complement to the simple laminectomy. The cervical canal is widened with repositioning of the lamina and spinous process [10]. Indications for laminoplasty are OPLL and degenerative cervical myelopathy with posterior compression to two or more levels. To overcome the limitations of the multilevel laminectomy different techniques of laminoplasty were proposed with the use of grafts and implants of various types: "open door", "tension band", "Z-Type", laminoplasty double door, etc. The main complications of laminoplasty are an inadequate expansion of the cervical canal (restenosis), C5 palsy, persistent neck pain, stiffness of the cervical spine for failure to preserve a normal cervical motility [11],[12]. In literature there is not agreement about which type of laminoplasty is the most advantageous [13, [14].

IV. CONCLUSIONS

Laminoplasty with polypropylene mesh seems to combine traditional laminectomy (simple technique with easy foraminotomy in case of radiculopathy and complete removal of the elements in case of cord compression) with the theoretical advantages of the laminoplasty (greater cervical stability) simplifying the surgical procedure and resetting the most common complications of simple laminoplasty. A clinical history more than one year and the age elder than 70 years appear the main negative prognostic factors. The advantage of the laminoplasty is a smaller anatomical damage

of the posterior elements without cervical instability, and use of polypropylene mesh provides more resistance during flexion-extension.

Consent

Written informed consent was obtained from the patients for publication of this case report and any accompanying images.

Abbreviations: MRI: Magnetic Resonance Imaging, OPLL: Ossification of the posterior longitudinal ligament.

REFERENCES

- [1] Oyama M, Hattori S, Moriwaki N. A New method of cervical laminoplasty. *The Central Japan Journal of Orthopaedic Surgery*. 1973;16:792-794.
- [2] Tatar C, Tüzün İS, Karşıdağ T, Kızılkaya MC, Yılmaz E. Prosthetic Mesh Repair for Incarcerated Inguinal Hernia. *Balkan Med J*. 2016 Jul;33(4):434-40.
- [3] Usher FC. Hernia repair with knitted polypropylene mesh. *Surg Gynecol Obstet*. 1963;117:239-40.
- [4] Julian TM. The efficacy of Marlex mesh in the repair of severe, recurrent vaginal prolapse of the anterior midvaginal wall. *Am J Obstet Gynecol*. 1996;175(6):1472-5.
- [5] Babashahi A, Taheri M. Kyphotic deformity after laminectomy surgery for a gunshot wound to the spine: a case report. *J Spine Surg*. 2016 Mar;2(1):64-8.
- [6] Fehlings MG, Santaguida C, Tetreault L, Arnold P, Barbagallo G, Defino H, Kale S, Zhou Q, Yoon TS, Kopjar B. Laminectomy and fusion versus laminoplasty for the treatment of degenerative cervical myelopathy: results from the AOSpine North America and International prospective multicenter studies. *Spine J*. 2016 Sep 3.
- [7] Sun LQ, Li M, Li YM. Predictors for surgical outcome of laminoplasty for cervical spondylotic myelopathy. *World Neurosurg*. 2016 Oct; 94:89-96. Sun
- [8] Ghasemi AA, Behfar B. Outcome of laminoplasty in cervical spinal cord injury with stable spine. *Asian J Neurosurg*. 2016 Jul-Sep;11(3):282-6.
- [9] Rao RD, Gourab K, David KS. Operative treatment of cervical spondylotic myelopathy. *J Bone Joint Surg Am* 2006; 88:1619-1640.
- [10] Ren DJ, Li F, Zhang ZC. Comparison of functional and radiological outcomes between two posterior approaches in the treatment of multilevel cervical spondylotic myelopathy. *Chin Med J* 2015; 128:2054-2058.
- [11] Woods BI, Hohl J, Lee J. Laminoplasty vs laminectomy and fusion for multilevel cervical spondylotic myelopathy. *Clin Orthop Relat Res* 2011; 469:688-695.
- [12] Geck MJ, Eismont FJ. Surgical options for the treatment of cervical spondylotic myelopathy. *Orthop Clin North Am* 2002; 33:329-348.
- [13] Mayfield FH. Complications of laminectomy. *Clin Neurosurg* 1976; 23:435-439.
- [14] Sakaura H, Miwa T, Kuroda Y. Incidence and risk factors for late neurologic deterioration after C3-C6 laminoplasty for cervical spondylotic myelopathy. *Glob Spine J* 2016; 6:53-59.

Authors profile

Dr. Domenico Murrone was born in Rossano, Italy, in 1982. He received his medical degree from "Magna Graecia" University of Catanzaro, Italy. His postgraduate training was completed at Neurosurgery Department of Hospital Policlinico in Bari, Italy and "San Salvatore" city hospital in L'Aquila, Italy. He completed a residency in neurosurgery at the "Di Venere" city hospital in Bari, Italy. Dr. He published many work about neurovascular and neurooncological disorders and he underwent more than 700 surgical operations.

Dr. Bruno Romanelli was born in Bari, Italy. He received his medical degree from University of Bari, Italy. His postgraduate training was

completed at Neurosurgery Department of Hospital Policlinico in Bari, Italy. He completed a residency in neurosurgery at the “Di Venere” city hospital in Bari, Italy. He underwent more than 2000 surgical operations.

Dr. **Aldo Ierardi** was born in Petilia Policastro, Italy. He received his medical degree from University of Rome, Italy. His postgraduate training was completed at Neurosurgery Department of “La Sapienza” University of Rome, Italy. He completed a residency in neurosurgery at the “Di Venere” city hospital in Bari, Italy. He underwent more than 5000 surgical operations.

Dr. **Gennaro Perrino** was born in Bari, Italy. He received his medical degree from University of Bologna, Italy. His postgraduate training was completed at Neurosurgery Department of “La Sapienza” University of Rome, Italy. He completed a residency in neurosurgery at the “Di Venere” city hospital in Bari, Italy. He underwent more than 6000 surgical operations.