

Case Report: Clotting Factor XII (Hageman) Deficiency Predisposing Acute non-hemorrhagic Stroke

Dr. Riyadh Ali Hammamy, Dr. Mohamed Kamal Hassan Sabra

Abstract— Prolonged Activated Partial Thromboplastin Time (APTT) on routine coagulation screening would usually attract clinician's attention toward bleeding tendency specially when done as preoperative preparation. Factor XII (Hageman factor) is one of the factors involved in the intrinsic coagulation cascade and deficiency of these factors eventually prolong APTT with bleeding tendency. However, factor XII deficiency are more liable for thromboembolism through defective fibrinolytic pathway rather than bleeding tendency.

A case of 27 years old male patient without past medical illnesses or significant risk factors presented with acute middle cerebral artery non-hemorrhagic stroke, screening to almost all etiological and predisposing factors were negative apart from prolonged APTT which was due to Factor XII (Hageman factor) deficiency.

Index Terms— Factor XII deficiency, Hageman factor, Prolonged APTT, Stroke.

I. INTRODUCTION

Factor XII, also called Hageman factor is an enzyme initiating the coagulation cascade with dual roles, minor role via activation of factor X which activate factor IX (intrinsic pathway), while major role is through conversion of plasminogen into plasmin by active factor XII and initiation of fibrinolysis, the processes of coagulation and fibrinolysis are constantly in a dynamic equilibrium; therefore, factor XII deficiency can potentially increase the risk of thrombosis [1]. Congenital factor XII deficiency is not associated with a clinical bleeding tendency; it can be identified on a routine coagulation test, such as a prolonged APTT[2].

Earlier many studies suggested an association between factor XII deficiency and autoantibodies to factor XII and recurrent pregnancy losses. Thromboembolism was first described in literature in 1955 when a routine preoperative blood sample of the 37-year-old man John Hageman was found to have prolonged clotting time in test tubes, even

though he had no hemorrhagic symptoms. Hageman was then examined by Dr. Oscar Ratnoff who found that Mr. Hageman lacked a previously unidentified clotting factor. Dr. Ratnoff later found that the Hageman factor deficiency is an autosomal recessive disorder, when examining several

related people which had the deficiency. Paradoxically, pulmonary embolism or myocardial infarction contributed to Hageman's death after an occupational accident[3,4]. Since then, case series clinical studies have identified an association of thrombosis and factor XII deficiency, though the pathophysiology of the relationship is unclear. It has been described that Hageman factor deficiency would cause pregnancy losses and venous thromboembolism and reported cases of myocardial infarctions.

Factor XII (Hageman Factor) deficiency is a rare detection, usually persistent prolongations of APTT either suggests of Hemophilia or presence of antiphospholipid antibodies which we have ruled out in this patient. Patient had no history of warfarin intake or other anticoagulation drugs, so the diagnosis was challenging. Our case is an example of the thrombophilia tendency to those who have factor XII deficiency presenting with acute non-hemorrhagic stroke while screening of almost all predisposing and risk factors came out to be negative and not significant.

II. CASE REPORT

27-year-old male patient with not known past medical illnesses or bleeding tendency presented to emergency room (ER) complaining of left sided facial weakness with left sided hemiparesis of 10 hours duration prior to presenting to ER. Upon examination; patient has normal vital signs, drowsy but conscious and oriented to person, place and time, has slurring speech, left upper facial motor weakness, other cranial nerves examination is unremarkable, has left sided weakness with a power of 2/5 in the lower limb and 3/5 in the upper limb, his left planter is upgoing, deep tendon reflexes are exaggerated on the left side, while the sensations look intact. Cardiovascular, respiratory and abdominal examinations are unremarkable.

Laboratory investigation showed normal CBC,

CMP, cardiac enzymes, normal Prothrombin Time (PT), but has prolonged APTT 61 second (normal 24.6-31 second).

CT and MRI Head: Large non-hemorrhagic area of acute infarction in right Middle Cerebral Artery (MCA) territory without associated significant mass effect. (Figure 1)

Riyadh Ali Hammamy, Internal Medicine, Hamad Medical Corporation, Doha, Qatar

Mohamed Kamal Hassan Sabra, Internal Medicine, Hamad Medical Corporation, Doha, Qatar

Table 1 Factor assays

| Clotting Percentage | Factors | Normal limits |
|------------------------------------|---------------|---------------|
| VIII | 109 % | 50-150 % |
| IX | 91 % | 65-150% |
| XI | 93 % | 65-150% |
| XII | 32.1 % | 70-150% |
| XII 31%(repeated) | | 70-150% |

antiphospholipid antibodies. Factors assay for factor VIII,IX, XI, XII was sent, and it showed Factor XII deficiency and confirmed by repeating the test (table1).

Thrombophilia screen came normal (table2).

Table 2 Thrombophilia screen

| | |
|---------------------------|--------------------|
| Homocysteine | 11 µmol/L (4-12) |
| ANCA | Negative |
| Factor V Leiden mutation | Negative |
| Protein S | 74 IU/dl(65 - 145) |
| Protein C | 107IU/dl (65-135) |
| Antithrombin III activity | 109 %(80-120%) |
| Anticardiolipin | Negative |
| Lupus anticoagulant | Negative |
| B2 glycoprotein | Negative |
| Prothrombin gene mutation | Negative |

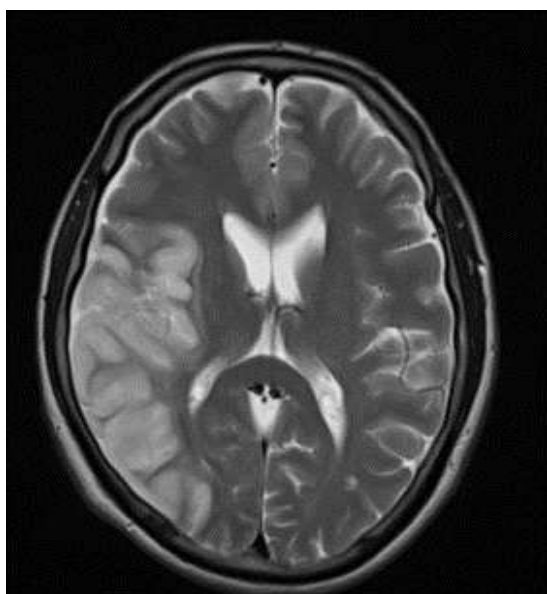


Figure 1. MRI HEAD

As patient came with late presentation and he is beyond the thrombolytic time management, he was managed conservatively with oral aspirin and high intensity statin, a thorough workup for the massive stroke in this young adult was done looking for the predisposing factors.

ECHO is normal, Doppler ultrasound of the neck came normal, cardiac Holter monitor for 48 hours showed no arrhythmia.

APTT was repeated and came prolonged, a mixing study was done and showed correction of the APTT, the mixing study is to differentiate the presence of antiphospholipid antibodies from factors deficiency, its performed by using 50:50 patient plasma and normal plasma and if the result showed correction of the prolonged APTT then the test confirmed it's a factor deficiency rather than the presence of

We would like to report this case of acute non-hemorrhagic stroke in a young adult with no previous predisposing factors found to have a prolonged APTT due to factor XII (Hageman) deficiency, although most of the reported cases with Hageman factor deficiency presented with pulmonary embolism or myocardial infarction and to lesser extent cerebrovascular accidents.

III. DISCUSSION

There have been many reports of association of Hageman Factor deficiency with myocardial infarction, pulmonary embolism and recurrent pregnancy loss. So better risk management is must for the better prognosis of individuals affected with Factor XII deficiency.

Factor XII, Hageman factor, is the zymogen of a serine protease that initiates the contact activation reactions and intrinsic blood coagulation in vitro. Severe factor XII deficiency is inherited as an autosomal recessive trait; affected patients have marked prolongation in the activated partial thromboplastin time (APTT) but do not exhibit a bleeding diathesis [3]. On the other hand, venous thromboembolism and myocardial infarction have been reported in patients with factor XII-deficient [4], including John Hageman, the initial patient described with this abnormality [5]. This thrombophilic tendency has been attributed to reduced plasma fibrinolytic activity [6].

Proposed mechanism for activation of Factor XII listed in figure 2.

Factor XII (Hageman factor) is an enzyme initiating the coagulation cascade with dual roles.

There are two pathways for Factor XII (Hageman factor) activation:

Autoactivation upon exposure to negatively charged surfaces and proteolytic activation on cell membranes.

Factor XII (FXII) autoactivates ($K_m = 2.4 \mu M$) on an artificial or biologic surface such as kaolin or a thrombus to activate Factor XII to α -FXIIa. α -FXIIa then activates FXI to FXIa to initiate hemostasis and activates PK to form plasma kallikrein (KAL). KAL cleaves HK to liberate bradykinin, which induces vasodilatation and vascular permeability. KAL also activates the complement system by directly activating complement components C3 and C5 and cleaving α -FXIIa to form β -FXIIa (a soluble light chain enzymatic form [Hageman factor fragment]), which then activates the macromolecular C1q,r,s complex to enzymatically active C1r and C1s. The results of the study by Maas *et al.* in this issue of the *JCI* (10) suggest that a second FXII autoactivation mechanism occurs upon exposure of FXII to aggregates of misfolded proteins and that this activation results in PK activation without FXI activation—showing that the kallikrein-kinin system can be activated separately from the coagulation cascade by FXII. A second pathway for FXII activation occurs on endothelial cells. PK bound to HK on endothelial cells is activated to plasma KAL by the serine protease prolylcarboxypeptidase (PRCP) ($K_m = 9 \text{ nM}$). KAL then activates FXII to α -FXIIa ($K_m = 11 \mu M$).

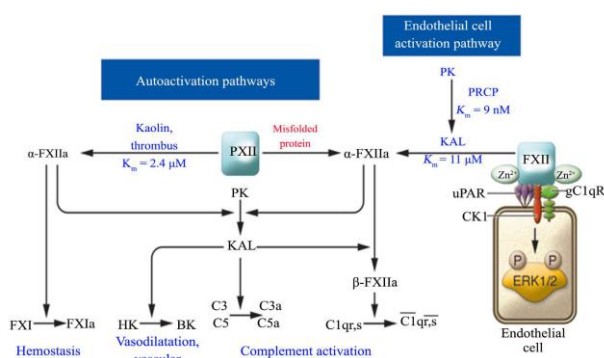


Figure 2. Mechanism for Factor XII activation [7]

Different theories of activation of factor XII in coagulation cascade as mentioned above but still the role of activation of urokinase & plasminogen receptors remains as a hallmark.

Currently, researches on coagulation factor XII are mainly focused on cardiovascular and cerebrovascular diseases.

Coagulation factor XII deficiency is either congenital or acquired. Congenital coagulation factor XII deficiency is a kind of rare autosomal recessive hereditary disease, and its clinical manifestation is low factor concentration without significant bleeding. Therefore, coagulation factor XII deficiency is often diagnosed before surgeries or during routine coagulation tests. Because no severe bleeding is related to this disease, no special treatment is required. Acquired coagulation factor XII deficiency is extremely rare and is related to coagulation factor XII inhibitors produced in patients with leukemia or nephrotic syndrome [8].

There are several conditions resulting in an isolated prolonged APTT. Deficiencies in contact factors, factors VIII, IX, XI and XII deficiencies, all result in an isolated APTT prolongation, as well as lupus anticoagulant, anticardiolipin, Von Willebrand disease and acquired clotting factor inhibitors such as acquired haemophilia A [9].

This lack of a bleeding tendency observed with FXII deficiency is in sharp contrast to deficiencies of other

components of the coagulation cascade, such as FVII, tissue factor (TF) and FVIII or FIX (causing the bleeding disorders hemophilia A and B, respectively) and has led to the reasonable hypothesis that fibrin formation in vivo is initiated largely, if not exclusively, through the extrinsic pathway of coagulation [10].

It has been a challenge for further management of a case who is found to have a low Factor XII, because the APTT is prolonged but no obvious bleeding symptoms are manifested. Our case was even more challenging as factor XII deficiency was the only predisposing factor detected after thorough workup and the patient had large non-hemorrhagic dense stroke, which might bleed if anticoagulation was started prematurely.

Finally, after consultation with hematology team and stroke unit team in our main hospital specialized departments they advised starting patient on warfarin with a target INR (2-3).

Plan was followed and intensive physiotherapy program in specialized rehabilitation center started, patient showed improvement and was discharged home later in fair performance status educated regarding anticoagulation and the need to follow PT-INR results

IV. CONCLUSIONS

Stroke in young adults became common diagnosis in cerebrovascular disease spectrum, although common known predisposing risk factors are smoking, hypertension, dyslipidemia and diabetes mellitus, but we need to give special concern for thrombophilia work up, cardiovascular causes (patent foramen ovale or arrhythmias), vasculopathy and autoimmune disorders is warranted when it comes to young patient with cerebrovascular accident.

Prolonged Activated Partial Thromboplastin Time due to Hageman factor deficiency would not present with bleeding tendency on the contrary they will remain asymptomatic most of the time and occasionally they may manifest with thrombotic event with special concern to the cerebrovascular accidents.

REFERENCES

- [1] Rygal, P. and Kuc, A. (2012) Perioperative Management of Cardiac Surgery Patients with Factor XII Deficiency—Two Case Reports. *Anesthesiology Intensive Therapy*, 44, 217-220.
- [2] Mariano, M.L., Yadir, P., Ana, A., Manuel, L. and Lopez Galvez, J.J. (2011) Coagulation Factor XII Congenital Deficiency in Women with Recurrent Miscarriage. *International Journal of Clinical Medicine*, 2, 469-472.
- [3] Saito H. Contact factors in health and disease. *Semin Thromb Hemost* 1987; 13:36.
- [4] Goodnough LT, Saito H, Ratnoff OD. Thrombosis or myocardial infarction in congenital clotting factor abnormalities and chronic thrombocytopenias: a report of 21 patients and a review of 50 previously reported cases. *Medicine (Baltimore)* 1983; 62:248.

- [5] Ratnoff OD, Busse RJ, Sheon RP. The demise of John Hageman. *N Engl J Med* 1968; 279:760.
- [6] Lodi S, Isa L, Pollini E, et al. Defective intrinsic fibrinolytic activity in a patient with severe factor XII-deficiency and myocardial infarction. *Scand J Haematol* 1984; 33:80.
- [7] Schmaier, A.H. (2008) The Elusive Physiologic Role of Factor XII. *Journal of Clinical Investigation*, 118, 3006-3009.
- [8] Wang, Y., Wang, Z., Li, H., Bi, K. and Zhu, C. (2014) Essential Thrombocytosis Accompanied by Coagulation Factor XII Deficiency: A Case Report. *International Journal of Clinical and Experimental Medicine*, 7, 3725-3729.
- [9] Nizamoglu, M., Alexander, K.S., Anwar, U. and Bhandari, S. (2014) Isolated APTT Prolongation—Not Always a Bleeding Risk in Acute Paediatric Burns Surgery. *European Journal of Plastic Surgery*, 37, 695-696.
- [10] Renné, T., Schmaier, A.H., Nickel, K.F., Blombäck, M. and Maas, C. (2012) In Vivo Roles of Factor XII. *Blood*, 120, 4296-4303.