

# Management of True Vaginal Prolapse in Bitch

Ankit Kumar Ahuja<sup>1</sup>, Shivkumar<sup>2</sup>, Ashwani Kumar Singh<sup>3</sup>, Shahbaz Singh Dhindsa<sup>4</sup>

<sup>1,2</sup>M.V.Sc Scholar, Department of Veterinary Gynecology and Obstetrics, College of Veterinary Science, Guru Angad Dev Veterinary and Animal Sciences University, Ludhiana, Punjab, India

<sup>3</sup>Assistant Professor, Department of Veterinary Gynecology and Obstetrics, College of Veterinary Science, Guru Angad Dev Veterinary and Animal Sciences University, Ludhiana, Punjab, India

<sup>4</sup>Assistant Animal Scientist, Department of Animal Genetics and Breeding, College of Veterinary Science, Guru Angad Dev Veterinary and Animal Sciences University, Ludhiana, Punjab, India

**Abstract**— True vaginal prolapse is a rare condition in bitch. It occurs majorly following parturition or during estrogen rise. *e* during estrous phase of the cycle. A two year old Grey Hound female was presented with true vaginal prolapse. The prolapse mass was large and hyperemic. By reducing the size and with bilateral pressure we reposed the mass in. Modified Buhner sutures were applied. Hormonal therapy using HCG were given for four days. The bitch recovered eventually.

**Keywords**— Vaginal Prolapse, Proestrous, Hyperemia.

## I. INTRODUCTION

True vaginal prolapse is very rare condition in bitch when compared to other vaginal pathologies like vaginal tumors or urethral tumors which protrude into vagina and obstruct the canal (Manothaiudom and Johnston, 1991). Vaginal prolapse usually occur in young bitch preferably less than 2 to 3 years age. It occurs majorly near parturition, as the serum progesterone concentration declines and the serum estrogen concentration increases (Koniget *et al.*, 2004; Rani *et al.*, 2004). This condition is less common in diestrus, anestrus and normal pregnancy (Johnston *et al.*, 2001; Schaefer-Okkens, 2001). Under the influence of high serum estrogen levels edematous swelling of the vaginal mucosa may develop (Johnston *et al.*, 2001). This is accompanied by increased vaginal hyperemia and edema occurring during proestrus and estrus due to the estrogen stimulus (Schaefer-Okkens, 2001). An amplification of this high serum estrogenic response can lead to disproportionate mucosal folding of the vaginal floor just cranial to the opening of urethra, which ultimately results in protrusion of vaginal mucosa from the vulva. The protruded mucosa can eventually become necrosed, inflamed and can easily be ruptured (Suresh Kumar *et al.*, 2011).

## II. CASE HISTORY AND OBSERVATIONS

A two year old female Grey Hound was presented in clinics with the history of mating. One day after mating due to vigorous straining the prolapse of vaginal fold and vagina has occurred (Fig 1). Physical parameters show a slight variation as compared to normal like sub normal rectal temperature (98.8 °F), increased heart rate (112 bpm) and congested mucus membrane. After carefully examining the mass it indicates the prolapse of vagina and its folds without the involvement of urinary bladder. The protruded mass has become edematous and hyperemic. The bitch has not urinated since last evening and straining was observed during defecation.

## III. TREATMENT

Catheterization was done to empty the urinary bladder and we collected about 120 ml of urine. Prolapsed mass was washed extensively with mild Potassium Permanganate solution (0.1% KMnO<sub>4</sub> Solution). Cold water treatment was done to reduce the mass size. We use drapes dipped in ice and cold water. Lignocaine jelly and ointment Soframycin was applied to lubricate and desensitized the mass. Drapes were squeezed to reduce the edema and hence size of protruded mass. Bilateral pressure was applied with the fingers from the ventral floor and lateral sides to repose the mass into the body. After continuous squeezing and applying bilateral pressure we are able to reduce the size and repose the mass. Modified Buhner suture were applied on the external labia keeping an opening of one finger diameter for the urination. Bitch was kept on Inj. Intacef 500 mg o.d I/M, Inj. Neurobion 3ml o.d I/M and Syrup Immunol 10 ml P.O for five days. Apart from this hormonal therapy using Human chorionic gonadotropin (HCG) was administered intramuscularly daily for 4 days at a dose of 500 I.U to induce premature ovulation. Sutures were removed after two weeks and the bitch recovered eventually.

#### IV. DISCUSSION

Vaginal prolapse mainly occur during proestrus or early estrous stages of the cycle (Johnston, 1989) and during or shortly after parturition (Schaefer-Okkens, 2001). Increased abdominal pressure and excessive pelvic ligaments relaxation predispose the animal for pre partum prolapse (Markandeya *et al.*, 2004). Constipation, forced separation during mating and size incompatibility between breeding animals can also lead to true vaginal prolapse (Purswell, 2005). Reports suggests that this condition may have some hereditary predisposition and is been seen in pure bred dogs (Johnston, 1989). Therefore it is advised to ovariectomized the affected bitches and they should not be used for breeding purpose (Troger, 1970). Vaginal prolapse usually occur during high serum estrogen concentration and is also connected with weakness of the perivulvar tissue of the bitch. Regression of the protruded mass begins in late estrus to early diestrus, as serum estrogen returns to the normal basal level (Alan *et al* 2007; Feldman and Nelson, 2004; Johnston *et al.*, 2001; Sarrafzadeh-Rezaei *et al* 2008). In the present case, reoccurrence of prolapsed mass do not occur as the after the end of estrous phase.

#### REFERENCES

- [1] Alan M., Cetin Y., Sendag S., Eski F. 2007. True vagina prolapse in a bitch. *AnimReprodSci* 100. 411-414.
- [2] Feldman E.C., Nelson R.W. 2004. *Canine and Feline Endocrinology and Reproduction*. W.B. Saunders, Philadelphia. pp. 901-918.
- [3] Johnston, S.D. 1989. Vaginal prolapse. In: *Current Veterinary Therapy*, 10th edn., Kirk R.W. (Ed). W. B. Saunders Co., Philadelphia. pp. 1302-1305.
- [4] Johnston, S.D., Kustritz, M.V.R. and Olson, P.N.S. 2001. *Canine and feline Theriogenology*, 1st edn. W.B. Saunders Co., London. pp. 225-273.
- [5] Konig, G.J., Handler, J. and Arbeiter, K. 2004. Rare case of a vaginal prolapse during the last third of pregnancy in a Golden Retriever bitch. *Kleintierpraxis*, 49. 299-305.
- [6] Manothaiudom, K. and Johnston, S.D. 1991. Clinical approach to vaginal/vestibular masses in the bitch. *Vet. Clin. N. Am. Small*.
- [7] Markandeya, N.M., Patil, A.D., Bhikane, A.U. 2004. Pre-partum vaginal prolapse in a dog. *Indian Vet. J.*, 81. 449.
- [8] Purswell, B. J. 2005. Vaginal disorders. In: *Textbook of Veterinary Internal Medicine*, 4th edn., Ettinger, S.J. and Feldman, E.C. (Eds). W.B. Saunders, London. pp. 1686-1690.
- [9] Rani, R.U., Kathiresan, D. and Sivaseelan, S. 2004. Vaginal fold prolapse in a pregnant bitch and its surgical management. *Indian Vet. J.*, 81. 1390-1391.
- [10] Sarrafzadeh-Rezaei F., Saifzadeh S., Mazaheri R., Behfor M. 2008. First report of vaginal prolapse in a bitch treated with oestrogen. *AnimReprod Sci*. 106. 194-199.
- [11] Schaefer-Okkens, A.C. 2001. Vaginal edema and vaginal fold prolapse in the bitch, including surgical management. In: *Recent advances in Small Animal Reproduction*
- [12] Suresh Kumar, R. V., P. Veena, P. Sankar, N. Dhana Lakshmi, Ch. Sreelatha & Kokila, 2011. Vaginal hyperplasia in a dog – a case report. *Tamilnadu Journal of Veterinary & Animal Sciences*. 7. 174-175.
- [13] Trogger, C.P. 1970. Vaginal prolapse in the bitch. *Mod. Vet. Pract.* 2: 428-430.

Figure

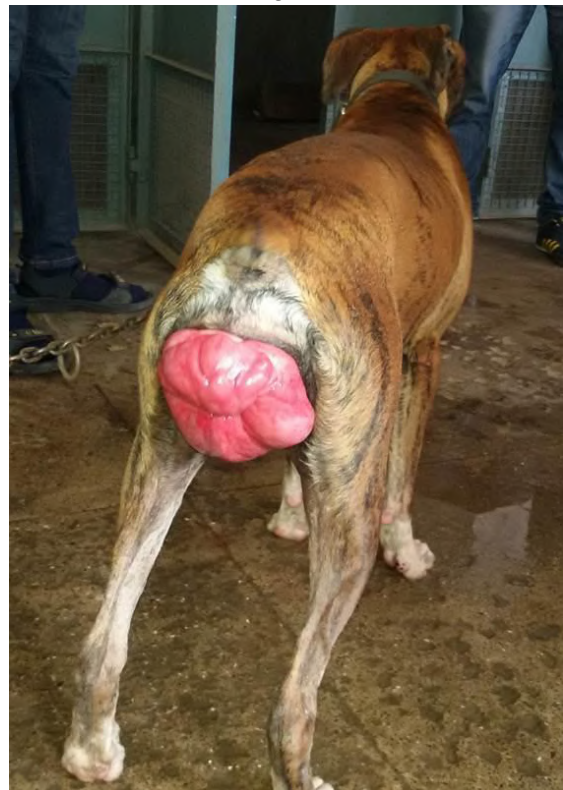


Fig.1: True vaginal prolapse