

# Endemic Fluorosis and Occurrence Gastrointestinal Disorders in Prakasam District A.P.

B. Tirumala Rao<sup>1</sup>, Dr B. Venkateswarlu<sup>2</sup>, Dr.C.V.Narasimha Murthy<sup>3</sup>

<sup>1</sup>Department of Chemistry, Rayalaseema University, Kurnool, Andhra Pradesh, India

<sup>2</sup>PBR Visvodaya Institute of Technology and Science, Kavali, SPSR Nellore, Andhra Pradesh, India

<sup>3</sup>Vikrama Simhapuri University P.G.Centre, Kavali, SPSR Nellore, Andhra Pradesh, India<sup>3</sup>

**Abstract**— Fluoride has been known to cause significant effect on human health through drinking water. Excessive ingestion of fluorides not only causes dental and skeletal fluorosis but also leads to gastro intestinal disturbances. Prakasam district of Andhra Pradesh, India is having severe fluorosis. In the present study epidemiological survey was conducted in five villages of Prakasam district regarding the incidence of Gastrointestinal symptoms such as loss of appetite, indigestion, nausea, vomiting, bloody vomiting, Pain in the upper part of the abdomen and blotting in the upper abdomen after eating. The results showed that nausea was found in 23 % of population. Loss of appetite was found in 18 % of villagers. Indigestion, bloody vomit was very low (6%) Experimental results show that male albino rats with ingestion of 4mg/L of fluorides for 120 days caused damage to the intestinal mucosa and sub mucosa. The possible reasons for the gastrointestinal problems and mechanism of action of fluorides on gastrointestinal tract was discussed.

**Keywords**— Endemic fluorosis, gastrointestinal problems, damage of sub mucosal layers.

## I. INTRODUCTION

Fluoride occurs naturally in public water systems as a result of runoff from weathering of fluoride-containing rocks such as fluorospar-CaF<sub>2</sub>, Cryolite-Na<sub>3</sub>AlF<sub>6</sub> and fluorapatite-Ca<sub>10</sub>F<sub>2</sub>(PO<sub>4</sub>)<sub>6</sub>. Lower concentrations of Fluorides are having beneficial effect on teeth by preventing and reducing the risk of tooth decay. In fact, concentrations lower than 0.5mg/L intensify risk of tooth decay. However, higher concentration (more than 1.5 – 2mg/L) fluoride becomes quite detrimental to health. Fluoride is potentially toxic at high doses or with prolonged lower-level exposure. It may cause dental fluorosis, osteomalacia, ligament calcification, hypocalcemia, arrhythmias, neurotoxicity, headaches, vertigo, thyroid dysfunction and anaemia (McNeely et al., 1979). Recent studies indicate that fluoride exposure from

fluoridated water correlates with increased risk of bone cancer in young boys, and hip fracture in the elderly. Major sources of internal exposure of individuals to fluorides are the diet (food, water, beverages) and fluoride-containing dental products (toothpaste, fluoride supplements). Internal exposure to fluorides also can occur from inhalation (cigarette smoke, industrial emissions). Fluorides are known to disturb enzymes and interfere with the intermediary metabolism (Barbier et al., 2010). They inhibit growth and development of animals by controlling the cellular respiration and ATP Synthesis (Mendoza-Shulz et al. 2009).

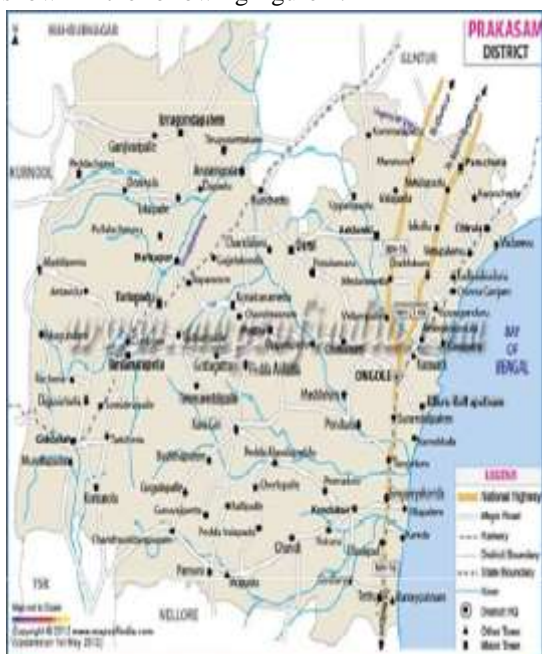Prakasam district of Andhra Pradesh, India is having serious endemic fluorosis ( Raghava Rao 2016, Sudhakar et. al. 2015). Fluorides not only affects the human beings but also other animal population. No specific studies are there on the influence of fluorosis on intestinal disorders. In the present study an epidemiological survey was made on the influence of fluorosis on gastrointestinal tract disturbance in Prakasam district. Apart from this the histological studies were made on the experimental rats to prove the damage of Intestinal mucosa by fluorides. A cross sectional survey was conducted in the fluorosis infested villages of Prakasam district of Andhra Pradesh. The aim of the study was to find out the prevalence of gastrointestinal disturbances among the population and to assess the relation between drinking water fluoride level and prevalence of fluorosis.

## II. MATERIAL AND METHODS

### 2.1. STUDY AREA

Prakasam District occupies an area of 17626 km<sup>2</sup>. It is the largest in area among the coastal districts of Andhra Pradesh. This district lies between 140 50' 27.725" to 160 17' 21.168" north latitude and 780 31' 1.298" to 80 30' 22.62" east longitude. The average elevation is 10m (30ft). It has a population of above 3054940 as per 2001 census. Many areas in this district depends on ground

water for drinking and other purposes. The base map representing the boundaries of 56 mandals are collected from collector office, Ongole. The collected map has been digitized by Arc Map 9.2 software. Map of the study area are shown in the following figure 1.



Taking these things into consideration a study has been conducted in selected villages of Prakasam district of Andhra Pradesh to understand the intensity of the problem.

**2.2 METHODS**

The study has been carried out in Giddalur, Kanigiri, and Chimakurthy, Kondapi, and Kandhukur mandals of Prakasam district in the year of 2016-17. From each mandal one village was selected and questioner was prepared and Household survey was made from 300 subjects from 120 households in each village where the fluoride incidence is high. Prior to starting the survey, information sharing and community consent was obtained by talking with Sarpanch and a large number of villagers. The nature and purpose of study was explained and oral consent was taken from the community. A cross sectional survey was made among the male population five villages from five mandals. In each village 60 males in the age group of 40-60 years were selected. Prevalence of symptoms related to the Gastro intestinal problems were recorded from them. The collected data was edited for completeness, accuracy and consistency.

**2.3. Animal trails:**

20 Wistar strain male albino rats were taken for the study. They were divided into two groups consisting of 10 animals in each group. First group was treated as control

group without any treatments. Rest of the 10 animals were treated as treatment group. They were given 4mg/l sodium fluoride treated for 60 days. After 60 days all the animals were sacrificed and autopsy was made and histological sections were made from intestine.

**III. RESULTS**

The data regarding the incidence of gastro intestinal disorders in the fluorosis infested villages is presented in Table.

Majority of villagers are above 40 years are suffering from nausea (22%). Blotting and anorexia was noted in 18% population. Indigestion and occasional vomiting were recorded in 12-14% Population. All these symptoms indicate the prevalence of gastrointestinal disorders in the villagers.

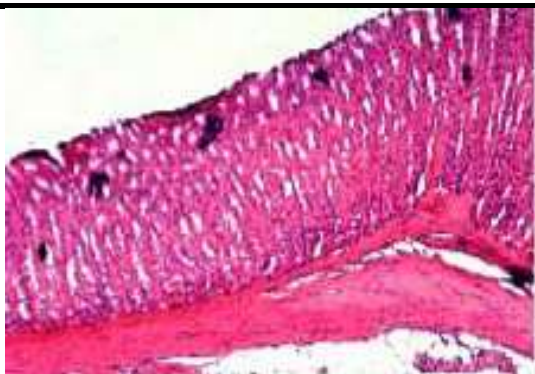*Table: Incidence of symptoms of gastrointestinal problems. No of cases is out of 300 subjects surveyed in five villages of Prakasam District.*

No	Symptom	Total subjects surveyed	No. of cases with symptom	% incidence
1	Loss of appetite	300	54	18
2	Indigestion	300	36	12
4	Nausea	300	66	22
5	Vomiting	300	42	14
6	Blood vomiting	300	18	6
7	Pain in the upper part of the abdomen	300	48	16
8	Blotting in upper abdomen	300	54	18

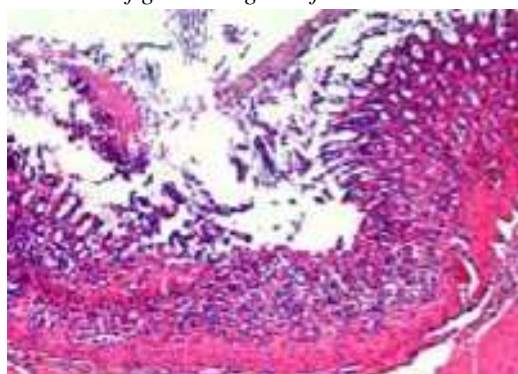
**3.2. Histopathological studies**

The c.s of the gastric region of control and fluoride treated rats were given below.

*Figure 1:*



C.S. of gastric region of Control Rats



C.S. of Gastric region of fluoride treated rats

#### IV. DISCUSSION

Fluoride occurs in drinking water primarily as free fluoride. When ingested, some From the above figures we can conclude that there is a severe damage of gastric region of fluoride treated rats. In them mucosa and submucosa were severely damaged leading to cause gastro intestinal symptoms.

Fluorides combine with hydrogen ions to form hydrogen fluoride (HF), depending on the pH of the contents of the stomach (2.4% HF at pH 5; 96% HF at pH 2). HF easily crosses the gastric epithelium, and is the major form in which fluoride is absorbed from the stomach upon entering the interstitial fluid in the mucosa where the pH approaches neutrality; HF dissociates to release fluoride and hydrogen ions which can cause tissue damage. Whether damage occurs depends on the concentrations of these ions in the tissue. Single high doses of ingested fluoride are known to elicit acute GI symptoms, such as nausea and vomiting, but whether chronic exposure to drinking water with fluoride at 4 mg/L can elicit the same symptoms has not been documented well. Hence in the present study an attempt is made to record the chronic effect of fluorides on gastric symptoms.

Fluoride can stimulate secretion of acid in the stomach (Assem and Wan 1982; Shaiq et al. 1984), reduce blood flow away from the stomach lining, dilate blood vessels, increase redness of the stomach lining (Fujii and Tamura 1989; Whitford et al. 1997), and cause cell death and

desquamation of the GI tract epithelium (Easman et al. 1984; Pashley et al. 1984; Susheela and Das 1988; Kertesz et al. 1989; Shashi 2002).

#### V. CONCLUSIONS

The survey findings revealed that the prevalence of gastro intestinal symptoms in Fluoride polluted villages of Prakasam district. It was more in elders than the youngsters. Our experimental results proved the damage of gastrointestinal mucosa due fluoride ions in rats on chronic treatment. Fluoride disrupts enzyme activity by binding to functional amino acid groups that surround the active centre of an enzyme. This includes the inhibition of enzymes of the glycolytic pathway and the Krebs cycle (Barbier et al., 2010). Studies by Mendoza-Shulz et al. (2009) indicate that fluoride at micromolar concentrations can act as an anabolic agent and promote cell proliferation, whereas at mill molar concentrations it acts as an enzyme inhibitor on e.g. phosphatases, which play an important role in the ATP (cellular energy) production cycle and cellular respiration.

#### ACKNOWLEDGEMENTS

The authors would like to thanks the management, principal, vice principal and staff of PBR Visvodaya Institute of Technology and Science, Kavali, SPSR Nellore district for providing all necessary facilities.

#### REFERENCES

- [1] Assem, E.S., and B.Y. Wan. Stimulation of H<sup>+</sup> ion secretion from the isolated mouse stomach by sodium fluoride. *Experientia* 38(3) 1982.369-370.
- [2] Barbier, O., Arreola-Mendoza, L., Del Razo, L.M. Molecular mechanisms of fluoride toxicity. *Chemico-Biological Interactions* 188: (2010)319-333
- [3] Easman, R.P., D.E. Steflik, D.H. Pashley, R.V. McKinney, and G.M. Whitford. Surface changes in rat gastric mucosa induced by sodium fluoride: A scanning electron microscopic study. *J. Oral Pathol.* 13(3) 1984.:255-264.
- [4] Fujii, A., and T. Tamura. Deleterious effect of sodium fluoride on gastrointestinal tract. *Gen. Pharmacol.* 20(5): 1989. 705-710.
- [5] Kertesz, P., T. Kerényi, J. Kulka, and J. Banoczy. Comparison of the effects of NaF and CaF<sub>2</sub> on rat gastric mucosa. A light-, scanning- and transmission electron microscopic study. *Acta Morphol. Hung.* 37(1-2) 1989.:21-28.
- [6] McNeeley, R. N., Neimanis, V. P., and Dwyer, L. *Water Quality Source Book. A Guide to Water*

- Quality Parameters. Inland Waters Directorate, Water Quality Branch, Environment Canada. (1979)
- [7] Mendoza-Schulz, A., Solano-Agama, C., Arreola-Mendoza, L., Reyes-M. rquez, B., Barbier, O., Del Razo, L.M., Mendoza-Garrido, M.E. The effects of fluoride on cell migration, cell proliferation, and cell metabolism in GH4C1 pituitary tumour cells, *Toxicol. Lett.* 190: (2009) 179–186.
- [8] Pashley, D.H., N.B. Allison, R.P. Easman, R.V. McKinney, J.A. Horner, and G.M. Whitford. 1984. The effects of fluoride on the gastric mucosa of the rat. *J. Oral Pathol.* 13(5):535-545.
- [9] Raghava Rao, S. 3-phase plan to end fluoride problems in Prakasam. *The Hindu.* 30<sup>th</sup> sep 2015.
- [10] Shashi, A. Histopathological effects of sodium fluoride on the duodenum of rabbits. *Fluoride* 35(1): 200228-37.
- [11] Shayiq, R.M., H. Raza, and A.M. Kidwai. Alteration in gastric secretion of rats administered NaF. *Fluoride* 17(3): 1984.178-1 82.
- [12] Steven F. Review of fluoride toxicity to aquatic organisms and its toxicity contribution in Volvo wastewater. Degree project for Master of Science in Ecotoxicology 30 ECTS. Department of Plant and Environmental Sciences University of Gothenburg. 2011.
- [13] Sudhakar G, Swarnalatha. G, Z. Vishnuvardhan, Harika.D , Statistical Analysis of the Groundwater Samples from Bapatla Mandal, Guntur District, Andhra Pradesh, India. *Journal of Envi sic, Toxicology & Food Tech.* 8(1) 2014. 27-32.
- [14] Susheela, A.K., and T.K. Das. Chronic fluoride toxicity: A scanning electron microscopic study of duodenal mucosa. *J. Toxicol. Clin. Toxicol.* 26(7): 1988.467-476.
- [15] Whitford, G.M., D.H. Pashley, and R.H. Garman. Effects of fluoride on structure and function of canine gastric mucosa. *Dig. Dis. Sci.* 42(10): 1997. 2146-2155.
- [16] World Health Organization: Drinking Water Standards and Health Advisories Office of Water U.S. Environmental Protection Agency Washington, DC.2011.