

## Alcoholic Liver Cirrhosis in Young Female: Diagnostic and Therapeutic Challenge

Syifa Mustika\*, Nina Nur Arifah\*

\*Division of gastroentero-hepatology, Department of Internal Medicine, Faculty of Medicine, Universitas Brawijaya/Dr. Saiful Anwar Hospital, Malang

### Corresponding author:

Syifa Mustika. Division of Gastroentero-hepatology, Department of Internal Medicine, Dr. Saiful Anwar General Hospital. Jl Jaksa Agung Suprpto No. 2 Malang Indonesia. Phone: +62-341-362101; Facsimile: +62-341-369384. E-mail: drtika\_78@yahoo.com

### ABSTRACT

Alcoholic liver cirrhosis is a disease due to excessive alcohol consumption that manifest as fatty liver, alcoholic hepatitis, and chronic hepatitis with fibrosis or liver cirrhosis. Alcohol consumption as much as 60 – 80 g per day for 20 years or more in male, or 20 g/day (approximately 25 mL/day) in female significantly increases the risk of hepatitis and fibrosis as much as 7-47%. The aim of this case report was to explore the diagnostic and therapeutic challenge of alcoholic liver disease in young aged female. A female, 24 years old, came with complaints of bloody vomiting, blacktarry stool, abdominal distention and history of alcohol consumption (canned beer 5%, equal to 56-70 g/day) for 9 years. Physical examination revealed anaemic conjunctiva (Hb 2.9 g/dL), ascites, hepatosplenomegaly, and bilateral legs oedema. Laboratory examinations showed thrombocytopenia (125000/uL) and hypalbuminaemia (2.65 gr/dL). AST and ALP were increased with the value of 175 U/L and 456 U/L, respectively. Albumin-globulin ratio was 0.93 g/dL with serum ascites albumin-gradient was 2.20 g/dL (ascites fluid albumin level was 0.45 gr/dL and serum albumin level was 2.65 gr/dL). Abdominal USG revealed hepatomegaly with coarse heterogenic ecoparenchyma, portal vein dilatation, and splenomegaly. Diagnosis of alcoholic liver cirrhosis was made based on clinical, laboratory, and radiologic findings, while biopsy result did not confirm the pathology. Patients condition improved with education of stop alcohol consumption and was given supportive therapy.

**Keywords:** alcoholic liver cirrhosis

### ABSTRAK

Penyakit sirosis hati alkoholik adalah manifestasi hati dari konsumsi alkohol berlebihan. Manifestasi yang dimaksud termasuk perlemakan hati, hepatitis alkoholik, dan hepatitis kronis dengan fibrosis atau sirosis hati. Konsumsi alkohol sebanyak 60-80 g per hari (sekitar 75-100 mL/hari) selama 20 tahun atau lebih pada pria, atau 20 g/hari (sekitar 25 mL/ hari) untuk wanita secara signifikan meningkatkan risiko hepatitis dan fibrosis 7-47%. Tujuan dari laporan kasus ini adalah untuk mengeksplorasi faktor risiko yang membuat penyakit hati alkoholik terjadi pada usia muda serta keberhasilan terapi suportifnya. Wanita muda datang dengan keluhan muntah darah dan BAB berwarna hitam, perut membesar dengan riwayat konsumsi alkohol selama 9 tahun. Dalam pemeriksaan fisik ditemukan konjungtiva anemia (Hb 2,9 g/dL), edema dan ascites. Temuan laboratorium menunjukkan trombositopenia (125.000/uL) dan hipoalbuminemia (2,65 gr/dL). AST dan ALP meningkat dengan nilai masing-masing 85 U/L dan 456 U/L. Rasio albumin-globulin adalah 0,93 g/dL dan serum asites albumin-gradien adalah 2,20 g/dL. USG abdomen menunjukkan hepatomegali dengan echoparenchym kasar heterogen dan dilatasi vena portal. Histologis biopsi hati menunjukkan Metavir F2 dengan degenerasi hidropik,

*terdapat nekrosis periportal di beberapa saluran portal, nekrosis lobular sedang di beberapa lobulus, portal dan beberapa fibrosis septum. Data ini mendukung adanya penyakit sirosis hati alkoholik. Kami melaporkan wanita, berusia 24 tahun dengan sirosis alkoholik yang berkembang dari konsumsi alkohol yang lama. Risiko pada wanita dapat ditingkatkan karena kurang dehidrogenase alkohol dalam mukosa lambung sebagai oksidasi pertama-pass alkohol menurun. Setelah terapi definitif dilakukan, kondisi pasien membaik.*

**Kata kunci:** *penyakit hati sirosis alkoholik*

## INTRODUCTION

Alcoholic liver cirrhosis is a disease due to excessive alcohol consumption that manifest as fatty liver, alcoholic hepatitis, and chronic hepatitis with fibrosis or liver cirrhosis. Alcohol consumption as much as 60 – 80 g per day (approximately 75-100 mL/day) for 20 years or more in male, or 20 g/day (approximately 25 mL/day) in female significantly increases the risk of hepatitis and fibrosis as much as 7-47%.<sup>1</sup>

Clinical syndrome of alcoholic hepatitis can be asymptomatic. However, in severe condition, this disease can be life-threatening with symptoms including jaundice, ascites, kidney failure, gastrointestinal bleeding, increased risk of infection, and encephalopathy.<sup>2</sup> The Royal Free Hospital reported that 20-30 patients in a year with severe alcoholic liver disease were referred from district hospitals. Several studies stated that mortality rate in acute severe alcoholic hepatitis was as high as 58% and could increase to 78% in the first year.<sup>2,3</sup> Although there is still lack of evident to effective treatment, administration of corticosteroid, and appropriate management in patients with alcoholic liver disease can decrease the development of life-threatening complications. One of the severe complications is hepatorenal syndrome. This condition can be prevented, but difficult to manage if it has happened.<sup>2,3</sup>

Alcoholic liver cirrhosis is a complex disease. The success of management depends on the integration of all competencies in public health, epidemiology, addiction behaviour, and alcohol-induced organ injury. The main intervention to decrease alcohol abuse and secondary intervention to decrease alcohol-associated morbidity and mortality depend on the coordinated action from multidisciplinary team which has been established in local, national, and international level.<sup>3</sup> Management of alcoholic liver cirrhosis is based on the severity of the illness and objective of treatment. Complications of cirrhosis, including evidence of liver failure (encephalopathy) and portal hypertension (ascites, variceal bleeding), are treated similar to non-alcoholic liver disease, with the main attention

given to other organ dysfunction, which is particularly associated with alcohol.<sup>4</sup> The aim of this case report was to explore the diagnostic and therapeutic challenge of alcoholic liver disease in young aged female.

## CASE ILLUSTRATION

A female, 24 years old, came with complaints of blood vomiting and black stool since 1 day before hospital admission. The volume of blood vomiting was  $\pm$  150 cc without precipitated by abdominal pain. Patient's stomach distended since 2 months before hospital admission. Patient was a housewife, married, and had a 1-year-old daughter. Before married, patient worked as a night bar guard and routinely consumed alcohol at work with the frequency of 4-5 times/week, and 4-5 cans of beer/day (equal to 56-70 grams of alcohol per day).

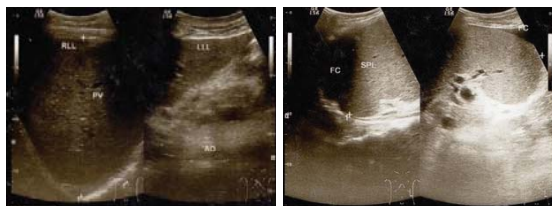Based on physical examination performed in the emergency department, we found blood pressure 110/50 mmHg, heart rate 110 bpm, respiratory rate 24x/minute. Conjunctiva were anaemic and systolic murmur in all valves were discovered. In physical examination of the abdomen, hepatomegaly was found (liver span 5 cm), splenomegaly Schuffner 3 with positive undulation, and oedema in the lower extremities.

Laboratory findings in the first day showed severe anaemia with haemoglobin level of 2.9 g/dL, thrombocytopenia (125000/uL), and hypoalbuminaemia (2.65 gr/dL). AST and ALP level were increased with value of 175 U/L and 456 U/L, respectively. Albumin-globulin ratio was 0.93 g/dL. Serum ascites albumin-gradient was 2.20 g/dL (with ascites fluid albumin level was 0.45 gr/dL and serum albumin level was 2.65 gr/dL). Bilirubin level was increased with total bilirubin value of 2.71 mg/dL, direct bilirubin 2.36 mg/dL and indirect bilirubin 0.35 mg/dL. Hepatitis seromarkers (HbsAg and anti-HCV) and ANA test results were negative.

As a definitive therapy, oxygen was administered using nasal cannula with the rate of 2-4 litre per minute, nasogastric tube was placed and gastric

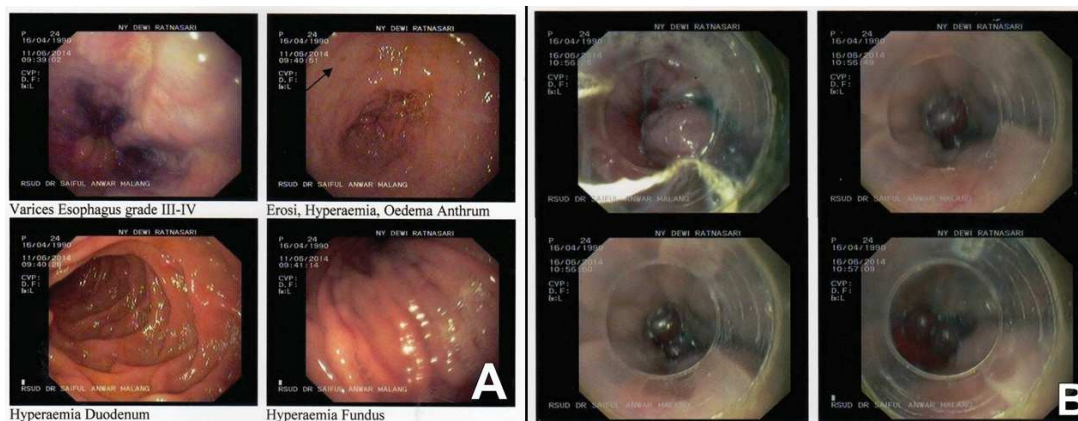
lavage was performed. In this patient, upper gastrointestinal bleeding was management by intravenous administration of omeprazole bolus 80 mg, followed with omeprazole drip 8 mg/hour for 3 days. For the anaemia, patient was given transfusion of PRC 2 unit/day with target of haemoglobin of 8 grams/dL. In addition, patient was also given intravenous Ceftriaxone injection 1 x 1 gram and oral lactulose of 3 x15 cc.

After gastric lavage was clear for 3 times, patient was given soft, low-salt diet 1700 kcal/day. Patient was also given supportive therapy of intravenous Furosemide 1x20 mg, spironolactone tablet 1x100 mg and propranolol tablet 2x10 mg. In day-2, day-3, and day-4 of hospitalisation, paracentesis of ascites fluid was performed with a total of 9700 mL

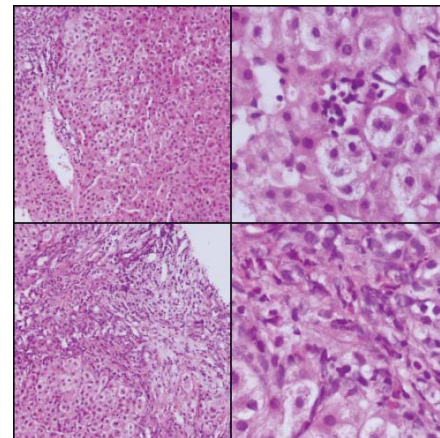


**Figure 2. 2 A:** Abdominal ultrasound showed hepatomegaly with the size of 15.4 cm, blunted edges, regular surface, coarse heterogenic ecoparenchyma. Dilatation of portal vein was found with diameter of 1.3 cm (Portal vein velocity 9 cm/s); **2 B:** Splenomegaly was also found, with diameter of 20 cm, blunted edges, flat surface, homogeny ecoparenchyma and dilated splenic vein (diameter 1.3 cm and splenic vein velocity 16 cm/s).

Abdominal ultrasound examination was performed in day-3 of hospitalisation and revealed the presence of hepatomegaly with coarse heterogenic ecoparenchyma and portal vein dilatation. Endoscopy was performed in day-6 of hospitalization and revealed the presence of oesophageal varices grade III-IV with erosive and hyperaemic surface, followed with three bands ligation.



**Figure 3. 3A:** Endoscopy showed presence of oesophageal varices grade III-IV, oedema of the antrum, hyperaemic fundus and duodenum (mosaic pattern was not found); **3B:** To the oesophageal varices, three bands ligation was performed.



**Figure 3. Histopathology:** Hydropic degeneration of liver cells, periportal and lobular necrosis, and portal and septal fibrosis → support chronic hepatitis metavir F2

Liver biopsy was performed in day-10 of hospitalisation and showed the presence of hydropic degeneration, necrotic periportal in several portal ducts, mild lobular necrosis in several lobules duct, portal, and several septum fibrosis. This data supported metavir F2 with moderate histologic activity.

Haemoglobin level was achieved in day-4 hospitalisation which was 9.2 gram/dL. Albumin level increased gradually with the value of 2.27 gram/dL in day-10 of hospitalisation. Patient was discharged after 14 days of hospitalisation in stable condition.

## DISCUSSION

Alcoholic liver disease can happen in patient who consumed alcohol excessively. Although the correlation between dose and consequence of alcohol consumption and alcohol-induced liver injury has been reported; no particular definition about amount of alcohol consumption which may further develop into

alcoholic liver disease. Nevertheless, most long-term heavy drinker may suffer from fatty liver, but only 10-35% develop into hepatitis and only 8-20% which will develop into cirrhosis.<sup>5</sup>

In this patient, there was habit of alcohol consumption since the age of 15 years old (9 years before identified to suffer from alcoholic liver disease), with frequency of alcohol consumption 4-5x/week, and 4-5 cans of beer/day. Estimated alcohol consumption was 56-70 grams/day. This was in accordance with the amount of daily intake which is a risk factor for alcoholic liver disease.<sup>5</sup>

Cirrhosis phase in alcoholic liver disease is associated with several histologic alterations, including the presence of Mallory hyaline, megamitochondria, or perisinusoidal fibrosis. In a study, alcohol consumption of at least 40 g/day continued to occur and increased the risk to develop cirrhosis up to 30%.<sup>4</sup> Patient consumed alcohol (in the form of canned beers as many as 4-5 cans/day) equal to 56-70 gram/day for approximately 9 years; therefore, the risk to develop alcoholic liver disease (fatty liver) was as much as 90% and liver cirrhosis as much as 30%, although the biopsy result did not confirm the pathology.

Other factor causing this patient to suffer from alcoholic liver cirrhosis in faster period was nutritional factor. Malnutrition generally happen in alcohol addict, as they tend to substitute daily nutritional calories with 'empty' calories provided by ethanol.<sup>5</sup> Nutritional status assessment in patients with alcoholic liver disease is made based on detailed anamnesis and physical examination. Patient's body mass index was within normal range, which was 21.5 kg/m<sup>2</sup> (BW: 51 kg; BH: 154 cm; measured after paracentesis of ascites fluid was performed). Good nutritional status based on body mass index might not be sufficient to describe nutritional status of patient with alcoholic liver disease. Another measuring tool which is widely used is Subjective Global Assessment (SGA). This questionnaire can evaluate every changes of food intake, changes of body weight, gastrointestinal symptoms, functional capacity, and malnutrition physical sign showed by loss of subcutaneous tissue, fat or muscle mass, oedema, or ascites<sup>8</sup>. Based on calculation using SGA, patient belong to moderate malnutrition or suggestive malnutrition (B).

Diagnosis of alcoholic liver disease was made based on the presence of excessive alcohol consumption history, presence of sign and symptoms of liver disease, and absence of other aetiology of liver injury<sup>3,6</sup>. There is no single definite laboratory marker which can

determine alcohol as the aetiology of liver disease. Besides, alcohol can be one of a number of factors which cause liver injury, and alcohol involvement alone may be difficult to be evaluated in patients with multifactorial risk factors.<sup>5</sup>

Several laboratory abnormalities, including increased serum aminotransferase may be found in patients with alcoholic liver disease. Generally, in severe alcoholic liver disease, serum AST may increase 2-6 times of the upper normal range. In approximately 70% of patients with alcoholic liver disease, AST/ALT ratio may be higher than 2. AST/ALT ratio > 3 is highly likely to develop into alcoholic liver disease. In this case, there was increased AST and ALT with the value of 175 U/L and 79 U/L, respectively, with AST/ALT ratio of 2.21.

Physical examination in patient with alcoholic liver disease may range from normal to the presence of signs of cirrhosis. In more severe condition, alcoholic liver disease may cause life-threatening conditions, such as jaundice, ascites, renal failure, gastrointestinal bleeding, increased risk of infection, and encephalopathy. In several studies, the mortality rate of acute severe alcoholic liver disease was as much as 58%, and increased to 78% in 1 year<sup>7</sup>. In this patient, we found anaemic conjunctiva, icteric sclera, and systolic murmur in all valves. From abdominal examination, we found hepatomegaly (liver span 15 cm), splenomegaly (Schuffner 3) with positive undulation and oedema in lower extremities. In accordance to the diagnostic criteria of cirrhosis, in the presence of signs of liver function failure and portal hypertension, it was established that patient suffered from cirrhosis. With the total bilirubin level of 2.71 mg/dL, albumin 2.65 g/dL, INR 1.23, ascites which well-responded with diuretic, this patient stood in Child Pugh B.

Imaging studies can be used to diagnose the presence of liver disease, but did not have specific role in determining alcohol as the specific aetiology of liver disease. Nonetheless, with fat alteration, presence of cirrhosis, and hepatocellular carcinoma can be revealed through ultrasound, CT scan, or magnetic resonance imaging confirmed with other laboratory examinations. The main objective from imaging studies are to exclude the other causes of abnormal liver examinations in patient with alcohol abuse, such as gall bladder obstruction or infiltrative pathology and neoplastic liver disease.<sup>3</sup>

Ultrasound appearances of patients with alcohol-induced cirrhosis liver disease include hepatomegaly with blunted edges, coarse liver parenchyma, and



fatty liver. Irregular liver surface, hepatomegaly, and decreased ultrasound brightness are important signs to evaluate the presence of cirrhosis.<sup>10</sup> In this patient, it was obtained that abdominal USG showed enlarged liver with cranio-caudal diameter of 15.4 cm with blunted edges. Although liver surface in patient's abdominal USG showed regular pattern, the finding of coarse and heterogenic echoparenchyma, was in line with the ultrasound appearance of patient with alcoholic liver disease who suffered from cirrhosis. Biliary system in this patient was not dilated, however portal vein dilatation with diameter of 1.3 cm was found. Based on the study performed by Geleto G et al (2016), the normal diameter of portal vein in average was  $10.6 \text{ mm} \pm 1.8 \text{ SD}$  with respiraphasic variation (revealing average of increased normal portal diameter during inspiration which is above maximal value) as much as 25.6%.<sup>11</sup> Therefore, it was obtained that increased diameter of portal vein was one of the signs of portal hypertension. This condition was supported with the velocity of patient's portal vein which decreased up to 9 cm/s. The velocity of blood flow in portal system correlated with the presence and size of oesophageal varices. In cirrhosis, portal vein velocity will tend to decrease and if less than 16 cm/s, most likely portal hypertension is present.<sup>12</sup> In the spleen, there was enlargement with cranio-caudal diameter of 20 cm, blunted edges, flat surface, homogen echoparenchyma, dilated splenic vein with diameter of 1.3 cm. Splenomegaly is an essential diagnostic sign of portal hypertension and generally found in patients with cirrhosis.<sup>12</sup>

Liver biopsy has three main roles, which are: (1) to establish diagnosis, (2) to determine prognosis (stage of disease), and/or (3) to facilitate in determining the decision of management and therapy.<sup>13</sup> In the guidelines recommended by AASLD in year 2009,

biopsy in alcoholic liver disease, liver biopsy is essential to be performed in determining stage of disease.<sup>13</sup> Although liver biopsy is a gold standard in diagnosis and evaluation of liver fibrosis, there are several limitations in liver biopsy procedure. In a literature, it was stated that although liver biopsy had been performed in ideal condition, there was discordance in the degree of fibrosis with a possibility as much as 20%.<sup>14</sup>

Anatomical histopathologic results from liver biopsy preparation in this patient showed the presence of hydropic degeneration of liver cells, periportal and lobular necrosis, and portal and septal fibrosis, in which this condition was in accordance with chronic hepatitis metavir F2. This result was not completely in accordance with the pathologic appearance of alcoholic liver disease in general. Hydropic degeneration is the initial phase of ballooning degeneration in liver cells, which is one specific appearance in alcoholic liver disease. Involved hepatocytes will show fine hydropic granule cytoplasm and contain hyaline Mallory's bodies.<sup>15</sup>

Necrosis is more commonly found in hepatitis caused by virus, autoimmune, and hepatotoxic medications, that represents the irreversible condition in acute and chronic liver disease which is caused by cell death due to hypoxia and ischemia.<sup>16</sup> In this patient, the possibility of hepatitis due to virus and autoimmune had been excluded (non-reactive HbsAg, negative antiHCV, negative ANA test). Hepatitis which is caused by medications had not been fully excluded, but based on anamnesis, patient denied particular medications consumption in duration or dose which was at risk to cause hepatotoxic.

Studies have shown that liver biopsy performed with a single pass can miss the diagnosis of cirrhosis in 20%-50% of patients.<sup>14</sup> Furthermore, other several

**Table 1: Prognostic parameter in alcoholic liver disease<sup>4</sup>**

Scoring system	Number of samples	Measured Elements				Test Characteristics
1. Maddrey (modified) discriminant function (1989)	n=66	MDF = 4.6 (patient's PT level – control PT value) + total bilirubin (mg/dL)				Poor prognosis if score is $\geq 32$
2. MELD score (2001)	n=1179	MELD score – $3.8 \times \log(\text{bilirubin in mg/dL}) + 11.2 \times \log_e(\text{INR}) + 9.6 \times \log_e(\text{creatinine mg/dL}) + 6.4$				Poor prognosis if score is $> 18$
3. Glasgow Hepatitis Alcoholic score (2005)	n=241	Score	1	2	3	Poor prognosis if score is $> 8$ (score calculated in the first or seventh day of hospitalization)
		Age	$< 50$	$\geq 50$	-	
		Leukocyte	$< 15$	$\geq 15$	-	
		Ureum (mmol/L)	$< 5$	$\geq 5$	-	
		PT Ratio	$< 1.5$	$1.5 - 2.0$	$\geq 2$	
		Bilirubin (mg/dL)	$< 7.3$	$7.3 - 14.6$	$> 14.6$	

MDF: Maddrey Discriminant Function; MELD: Model for End-stage Liver Disease

studies performing liver biopsy in all patients with alcoholic liver disease exhibited that histologic confirmation was only found in 70-80% of patients.<sup>4,14</sup> This was suggested to be caused by the depth of biopsy of 4 cm could not be considered as gold standard, as to evaluate liver as a whole, needle with minimal length of 10 cm was needed.<sup>14</sup> Although results of anatomical histopathology did not fulfil the specific appearance of alcoholic liver cirrhosis (in which Metavir F2 was obtained), patient had showed clinical alcoholic liver cirrhosis, which includes alcohol consumption equal to 56-70 gram/day for at least 9 years, signs of liver failure (hypoalbuminemia, icteric, ascites, lower extremities oedema) and signs of portal hypertension (massive ascites), hematemesis which was caused by oesophageal varices grade III-IV, portal vein dilatation, decreased velocity of portal vein, splenomegaly, and thrombocytopenia). Discordance of clinical and histologic appearance in this patient might represent that in several conditions, liver biopsy could possibly not able to show liver injury as a whole. Clinical condition and other parameters can be more relied on to establish the diagnosis of alcoholic liver cirrhosis.

Decision regarding treatment of alcoholic liver disease is very much based on patient's prognosis. In alcoholic liver disease, *Maddrey discriminant function*, is used to stratify disease severity. The formula is *Maddrey discriminant function* (MDF) = 4.6 (patient's PT - control PT) + total bilirubin (mg/dL). Patient with the score of >32 has highest risk factor of mortality, with mortality rate 1 month as high as 30 - 50%. In this patient, MDF result was 15.34; therefore, patient was categorised to have good prognosis.

Despite the severity of the disease, cessation of alcohol consumption is the most important thing in therapy and early management of alcohol abuse in patients with alcoholic liver disease. Nutritional status also need to be evaluated. In regard to the presence of Wernicke encephalopathy, supplementation of vitamin B complex is recommended. Recommended daily protein intake is 1.5 g/kg body weight. Deficiency of liposoluble vitamin need to be compensated. In this case, patient has stopped consuming alcohol since her first pregnancy.

This patient stood in the degree of alcoholic liver disease with low risk; hence, based on the algorithm showed in figure 6, patient was given supportive therapy, in the form of nasogastric tube placement for gastric lavage, PPI drip, oesophageal varices ligation, and PRC transfusion as much as 4 flasks during hospitalization. After hematemesis and melena

had stopped, patient was given propranolol 2x10 mg, furosemide 1x20 mg, spironolactone 1x100 mg, and paracentesis of ascites fluid as much as 9700 mL.

## REFERENCES

1. Carithers RL, McClain C. Alcoholic liver disease. In: Feldman M, Friedman LS, Brandt LJ. *Feldman: Sleisenger & Fordtran's Gastrointestinal and Liver Disease*. 9th ed. Philadelphia, PA: Elsevier Saunders; 2016:chap 86.
2. Celli R, Zhang X. Pathology of Alcoholic Liver Disease. *Journal of Clinical and Translational Hepatology* 2014;2:103–09.
3. European Association for the Study of the Liver. EASL Clinical Practical Guidelines: Management of Alcoholic Liver Disease. *Journal of Hepatology* 2012;57:399–420.
4. O'Shea, RS, Dasarthy S, McCullough, AL. ACG Practice Guidelines: Alcoholic Liver Disease. *The American Journal of Gastroenterology*. Am J Gastroenterol 2010;105:14-32.
5. Gramenzi A, Caputo F, Biselli M, Kuria F, Loggi E, Andreone P, Bernardi M. Review article: alcoholic liver disease-pathophysiological aspects and risk factors. *Aliment Pharmacol Ther* 2006;24:1151-61.
6. Mookerjee RP, Lackner C, Stauber R, Stadlbauer V, Deheragoda M, Aigelsreiter A, et al. The role of liver biopsy in the diagnosis and prognosis of patients with acute deterioration of alcoholic cirrhosis. *Journal of Hepatology* 2011;55:1103–11.
7. Beirne JO, Patch D, Holt S, Hamilton M, Burroughs AK. Alcoholic hepatitis — the case for intensive management. *Postgrad Med J* 2000;76:504–7.
8. Rossi RE, Conte D, Massironi S. Diagnosis and treatment of nutritional deficiencies in alcoholic liver disease: Overview of available evidence and open issues. *Dig Liver Dis* 2015;47:819-25.
9. Griffith CM, Schenker S. The Role of Nutritional Therapy in Alcoholic Liver Disease. *Alcohol Research & Health* 2006;29:296-305.
10. Yang SS. Alcoholic Liver Disease: Clinical and Sonographic Features. *J Med Ultrasound* 2008;16:140–9
11. Geleto G, Getnet W, Tewelde T. Mean Normal Portal Vein Diameter Using Sonography among Clients Coming to Radiology Department of Jimma University Hospital, Southwest Ethiopia. *Ethiop J Health Sci* 2016;26: 237–42.
12. Burroughs AK. The Hepatic Artery, Portal Venous System and Portal Hypertension: the Hepatic Veins and Liver in Circulatory Failure. In: Dooley JS, Lok ASF, Burroughs AK, Heathcote EJ (ed). *Sherlock's Diseases of the Liver and Biliary System*. Blackwell Publishing Ltd. 2011. London.
13. Rockey DC, Caldwell SH, Goodman ZD, Nelson RC, Smith AD. Liver Biopsy. *American Association for the Study of Liver Diseases* 2009:1017-40.
14. Sanai FM, Keeffe EB. Liver Biopsy for Histological Assessment – The Case Against. *Saudi J Gastroenterol* 2010; 16:124–32.
15. Afroudakis, AP. Alcoholic liver disease - An overview. *Annals Gastroenterol* 2000;13:290-8.
16. Krishna M. Patterns of Necrosis in Liver Disease. *Clin Liv Dis* 2017;10:53-6.