

Osteoarticular tuberculosis of the right foot: a diagnostic delayed

N Akil,¹ B Setiyohadi,² AMT Lubis,³ A Fawziah⁴

¹ SMF Internal Medicine, Kanujoso Djatiwibowo Hospital, Balikpapan;

² Division of Rheumatology, Departement of Internal Medicine, School of Medicine University of Indonesia;

³ Departement of Orthopaedic Surgery, School of Medicine University of Indonesia;

⁴ Departement of Internal Medicine, School of Medicine University of Indonesia

Extrapulmonary tuberculosis (TB) involving the musculoskeletal system occurs in approximately 1% to 3% of patients with extrapulmonary TB. Concurrent pulmonary or intrathoracic TB is present in less than 50% of cases.¹ Spine is the most frequent site of osseous tuberculous involvement. Other affected sites include the hip, knee, foot, elbow, hand, and bursal sheaths.² Tuberculosis of the foot and ankle remains an uncommon site of the infection, present in 8% to 10% of osteoarticular infection. The diagnosis of osteoarticular tuberculosis is often delayed due to a lack of familiarity with the disease.³ We describe a patient with foot pain and swelling without any respiratory symptom as initial presentation of pulmonary and osteoarticular tuberculosis.

CASE REPORT

A 60-year-old woman was admitted to Cipto Mangunkusumo Hospital with complaint of chest pain for two days. Chest pain was mainly felt when she inhaled. The pain was accompanied by cough and dyspnea. There were decreasing of appetite with 12 kg weight loss in the last 4 months, intermittent fever, and difficulty to fall asleep. The patient denied having night sweats. She had also complained of swelling and tenderness of the right foot since 2 years ago. There was no history of pulmonary tuberculosis previously. She was a smoker, 12 sticks/day, started from the age of 25 and had stopped when she was 40. On physical examination we found that she was alert with poor nutritional status, blood pressure was 120/80 mmHg, pulse rate was 104 times/minute, respiratory rate was 28 times/minute, and body temperature was 38°C. The conjunctiva was pale. On lung examination, the main respiratory sound was bronchovesicular in both of the lungs with rales in the top and basal of the lung. On extremities examination, the right foot and right ankle appeared swollen and painful upon palpation with limitation of the range of motion of ankle joint (figure 1). The clinical examination of the rest of the systems revealed no abnormality.

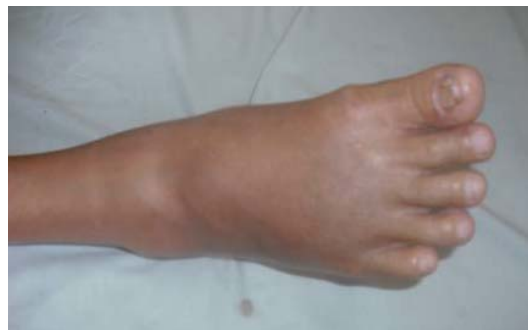

Figure 1 Swelling of the right foot and the right ankle joint

The results of the blood test were as follows: hemoglobin 9.0 gr/dl, WBC 18,700/ul, platelet 350,000/ul, ESR 27 mm/1st hr, triglyceride 90 mg/dl, total cholesterol 80 mg/dl, HDL 28 mg/dl, LDL 34 mg/dl, uric acid 3.5 mg/dl, creatinine 1.3 mg/dl, SGPT 19 U/L, random blood glucose 106 mg/dl, Na 123 mEq/L, K 4.7 mEq/L, Cl 93 mEq/L, CK 189 mg/dl, CKMB 11 mg/dl. Serial of 3 times electrocardiogram test showed sinus rhythm, normal axis, QRS rate 107 times/minute, and no ST change. Peripheral blood morphological examination revealed normocytic normochromic anemia. Microbiologic examination of her sputum was positive for acid-fast bacilli (AFB). The result of chest X-Ray examination was duplex lung tuberculosis (figure 2). The X-ray examination of the right foot was suggestive for chronic destructive arthritis (figure 3).

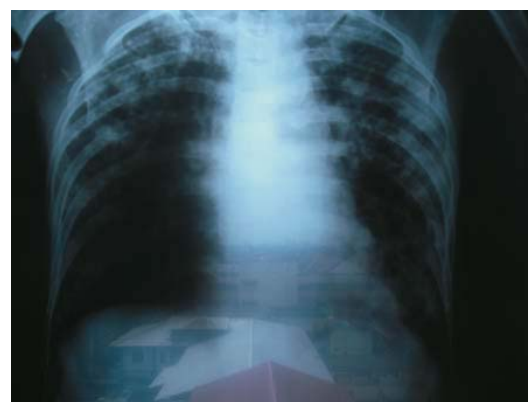


Figure 2 Plain Chest X-ray in posteroanterior view. There were bilateral fibroinfiltrates.

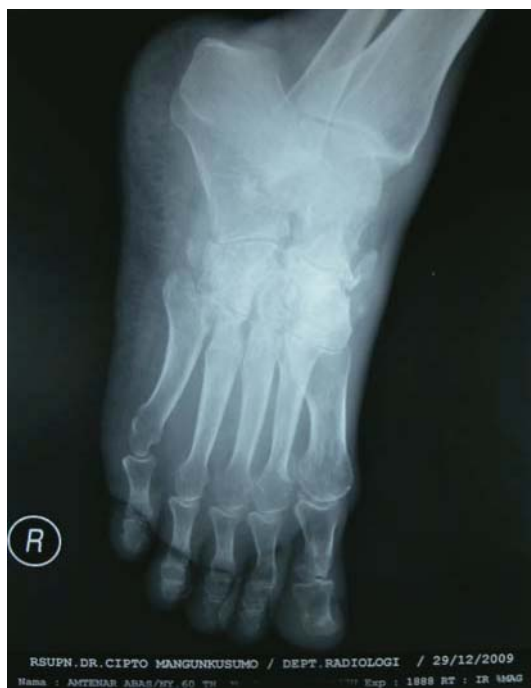

Figure 3 X-ray of right foot. It showed destruction of tarsal bone and proximal third, fourth, and fifth metatarsal bones, the more porotic first metatarsal bone, tarsometatarsal joint space narrowing, soft tissue swelling, and calcification.

Surgery was conducted in this case for diagnostic and as well as treatment purposes (figure 4). The result of microscopic examination of pus that was obtained from debridement procedure was positive AFB. The anatomical pathology examination showed non specific chronic osteomyelitis. The patient was given the diagnosis of pulmonary and osteoarticular tuberculosis of the right foot and received the medication of the anti-TB drug of fixed dose combination (INH 300 mg/day, rifampicin 450 mg/day, ethambutol 1,5 g/day, pyrazinamide 1,5 g/day) for two months as the intensive phase. Then the medication will be continued to the maintenance phase for 9 to 12 months based on the clinical and radiographic improvement. After 3 month treatment, the foot swelling and pain are reduced and the range of motion of right ankle joint is improved.

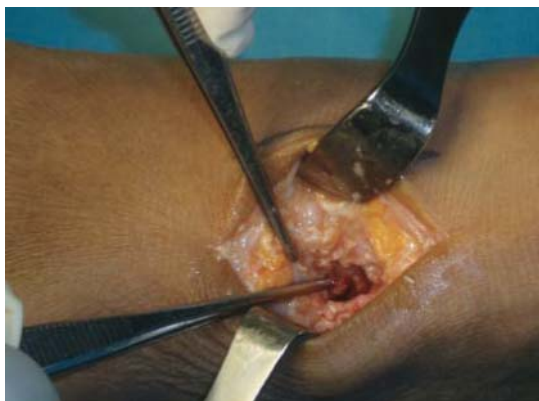

Figure 4 Intraoperative photo showed pus and mass with dimension of 1 x 1 cm.

DISCUSSION

Clinical symptoms of osteoarticular tuberculosis may be nonspecific early in the course of infection: low-grade fever, weight loss, and night sweats being the most common. Patients with more advance disease may exhibit local pain, atrophy of affected limb due to immobilization, muscle spasms, and regional lymphadenopathy.⁴ The diagnosis of osteoarticular TB is made based on clinical and imaging findings, histopathological examinations, culture identification, and polymerase chain reaction.^{5,6,7} The mainstay of the treatment is multidrug antituberculosis chemotherapy and active or assisted non-weight bearing exercises of the involved joint throughout the period of healing. An initial period of rest is to be followed by supervised gradual mobilization. Adequate nutritional support is also essential, as in all forms of TB. Tuberculosis of the foot occurs in various forms. Granulomatous infection adjacent to a joint is the most common form. The second is a central granuloma, especially in the phalanges or the metatarsals. Up to 33% of patients have multiple metatarsals involvement.⁴ In this case report the patient had multiple metatarsals involvement. Based on plain radiography of right foot, there was involvement of tarsal and third, fourth, and fifth metatarsal bones which are destroyed. The patient had swelling and joint pain of the right foot since two years before admission. No history of diagnosed lung TB, but clinical and imaging findings at the admission time revealed active lung TB. It is similar with those reported by Huang et al. In Taiwan's tertiary teaching hospital, they found joint pain (96.1%) and swelling (90.2%) as two major presentations of arthritis TB. Twenty six (51.0%) patients had radiologic evidence of pulmonary TB.³ Plain films of involved extraaxial joints may show a normal, widened (from effusion), or narrowed joint space (in advanced disease). Periarticular osteoporosis may be severe.⁴ Plain photo in this case revealed periarticular osteoporosis where was found destruction of tarsal and proximal metatarsal bone. Diagnosis of the patient was established by the microscopic examination of pus obtained from debridement procedure that showed AFB positive. Response to the treatment of osteoarticular tuberculosis is difficult to assess. Resolution of systemic symptoms, local pain, swelling, or effusion in addition to radiographic improvement are helpful in determining duration of therapy.⁴ Interestingly, there was a delayed diagnosis in this case. Swelling, joint pain, and tenderness of the right foot had been suffered since 2 years before admission. Similar case was reported by Erdem et al, a gonitis TB that was diagnosed after 4 year evaluation with various tests.³

REFERENCES

1. Paredes CF, Borjon AD, Senger MA, Barragan L, Leonard M. The ever-expanding association between rheumatologic diseases and Tuberculosis. *Am J Med* 2006;119:470-7.
2. Hazra A, Laha B. Chemotherapy of osteoarticular tuberculosis. *Indian J Pharmacol* 2005;37:5-12.
3. Erdem H, Baylan O, Simsek I, Dinc A, Pay S, Kocaoglu M. Delayed diagnosis of tuberculous arthritis. *Jpn J Infect Dis* 2005;58:373-5.
4. Patel M, Pappas PG. Fungal and mycobacterial osteoarticular infections. In: Koopman WJ, Moreland LW, editors. *Arthritis and allied conditions: a textbook of rheumatology*. 15th ed. Philadelphia: Lippincott Williams and Wilkins; 2005. p. 2615-43.
5. Vanhoenacker FM, Sanghvi DA, De Backer AI. Imaging features of extraaxial musculoskeletal tuberculosis. *Indian J Radiol Imaging* 2009;19:176-86.
6. Ytterberg SR. Infectious disorders: Mycobacterial, fungal, and parasitic arthritis. In: Rosen CJ, Compston JE, Lian JB, editors. *Primer on the metabolic bone diseases and disorders of mineral metabolism*. 7th ed. Washington DC: ASBMR; 2008. p. 290-5.
7. Titov AG, Vyshnevskaya EB, Mazurenko SI, Santavirta S, Kontinen YT. Use of polymerase chain reaction to diagnose tuberculous arthritis from joint tissues and synovial fluid. *Arch Pathol Lab Med*. 2004;128:205-9.
8. Huang TY, Wu TS, Yang CC. Tuberculous arthritis — a fourteen-year experience at a tertiary teaching hospital in Taiwan. *J Microbiol Immunol Infect* 2007;40:493-9.