

**TOPICAL APPLICATION OF ETHANOL EXTRACT OF STARFRUIT LEAVES (*AVERRHOA BILIMBI LINN*)
INCREASES FIBROBLASTS IN GINGIVAL WOUNDS HEALING OF WHITE MALE RATS**

^{1,2}Hartini IGAA

¹Postgraduate School of Biomedicine Udayana University, Bali-Indonesia

²Faculty of Dentistry Mahasaraswati University, Bali-Indonesia

ABSTRACT

Injuries to the gingiva are often encountered because of abnormalities in the oral cavity. Gingival wound healing is more complex because it lies in an open area, often contaminated and exposed to various types of bacteria in the oral cavity. Gingiva wound healing is determined by increase of fibroblasts. Plants widely used by humans as medicine is star fruit (*Averrhoa Bilimbi Linn*). This study aims to determine an increase of gingival fibroblasts on wound healing of male white rats given various concentrations of starfruit leaves extract topically. The study was conducted with a pretest-posttest control group design, consisted of four groups: the control group with distilled water and the groups treated with ethanol extract of starfruit leaves with a concentration of 10%, 20% and 40%. The result based on comparison test between the groups with One Way Anova, showed that the average amount of fibroblast in four groups after receiving the treatment was significantly different ($p < 0.01$). The result of the test showed an increase in the number of fibroblasts in groups concentration of 10% and 20%, there was a decline observed in group concentration of 40%. It was concluded that application of ethanol extract of starfruit leaves with concentration of 10% increase the highest number of fibroblasts in the rat gingival wound healing process. Keywords: wound healing, leaves of starfruit (*Averrhoa Bilimbi Linn*), fibroblasts.

INTRODUCTION

Gingiva is a mucosa of mouth cavity that specifically has a structure to support tissue function, especially as a barrier towards damage caused by mechanical factor or microbes. Gingiva wound is frequently found as a results of mouth cavity disability. This wound is probably due to pathologic or non pathologic factors. Recurrent ulcer mouth cavity is one of example of pathologic gingiva wound, meanwhile for nonpathologic of cavita wound is due to instrumental trauma after operation.

Wound healing is a complex process involves interaction of various types of cells and biochemical mediators. Cavita injury lies in an open area, therefore, it will be contaminated and exposed to various types of bacteria. Gingival epithelial cells play an active role in the immune system to provide interactive response to bacteria.¹ Therefore, the wound healing process is not limited to local regeneration processes but the overall condition involving endogenous factors such as age, nutrition, medicine, immunological status, and metabolic conditions.²

Histologically, the healing of wounds showed a picture of an increase in inflammatory cells, vascularity, epithelial cell density, increased number of fibroblasts and collagen fibers. The wound healing

process involves three phases, namely inflammatory phase, proliferative phase and remodeling phase.³

In Indonesia medical science improvement shows a rapid progress proven by many research on development of varies natural substances for drug including application and their utilization. Improvement of technology that can process traditional medicine, made an easy way to generate practical, economical, and easy way to produce many medicines, including wound healing medicine.⁴

Indonesia has varies of tropical plants applied as traditional medicine. One of plant grown in garden and used in everyday life both as a medicine, herbs, flavor concentrates is starfruit (*Averrhoa Bilimbi Linn*).⁵

Starfruit contains potent compounds, such as saponins, tannins, flavonoids, alkanoid, glucosides, calcium oxalate, sulfuric acid, formic acid, peroxide, and potassium citrate. This fruit is believed to have antioxidant activity. In addition, starfruit also contains nutritional elements such as: calories, protein, carbohydrates, calcium, phosphorus, iron, vitamin A, vitamin B1, and vitamin C. Starfruit has an ability as a pain reliever (analgesic), launching the release of bile, anti-inflammatory and urinary shed.⁵

Starfruit can be used as a drug to somatitis wound because it contains saponins which have the ability to clean and as an anti-septic, tannins and flavonoids act as anti-inflammatory by inhibiting the enzyme cyclooxygenase and lipoxygenase. While alkanoid able to relieve pain (analgesic) and vitamin C play a role in the repair of oral mucosal tissues, which can help the process of wound healing.⁵

Correspondence: Hartini IGAA

Address: Faculty of Dentistry Mahasaraswati University,
Bali-Indonesia

Research in some plants obtain flavonoid that have an anti-inflammatory activity through inhibition reaction of some enzymes. Aglikon is a non polar flavonoid, whereas glicosida is a polar flavonoid. Therefore, polar flavonoid can be isolated from star fruit using water solvent or ethanol 70%.⁷ Ethanol 70% is an effective solvent to produce an optimal amount of active ingredient, does not cause swelling of the cell membrane and improve the stability of the components dissolved.⁶

This research aims to investigate application of star fruit (*Averrhoa Bilimbi Linn*) extracted using ethanol for increasing fibroblast in wound healing of gingiva injury of white male rat.

METHODS

Research Design

This is an experimental study with Randomized Pre-Posttest Control Group Design.⁸ A number of 32 white male rats were recruited and divided into 4 groups. The first is control group treated only with aquadest. The second is treatment group 1 treated with 10% of star fruit extract. The third is treatment group 2 treated with 20% of star fruit extract. The last group is treatment group 3 treated with 40% of star fruit extract.

Time and Places

This research was carried out at Pharmacology Laboratory Faculty of Medicine Udayana University and Veterinary Faculty of Udayana University. The research was carried out during March – June 2011.

Research variable

Independent variable

1. Topical administration of 10% star fruit extract.
2. Topical administration of 20% star fruit extract.
3. Topical administration of 40% star fruit extract.

Dependent variable

Number of fibroblast in gingiva.

Control variables

1. Food and rat cages
2. Rata ge (2 months)
3. Sexes of rat (male)
4. Weight of rats (180-200 g)
5. Humidity
6. Temperature
7. Light

Procedure

Preparation of starfruit ethanol extract

Ethanol extract of starfruit leaves were prepared at Laboratory of Pharmacy Faculty of Medicine Udayana University. Starfruit leaves obtained from Bualu village, Nusa Dua, Bali-Indonesia. Starfruit leaves were washed and dried in room, then crushed in a blender to form powder. This powder then was

added 70% ethanol and stirred for 30 minutes with magnetic stirrer and allowed to stand for 24 hours. This mixture was then filtered using Buchner funnel. The filtrate obtained was dried via evaporation using vacuum rotary evaporator. After evaporation, crude extract was obtained and from this crude extract many concentrations of starfruit, i.e 10%, 20%, and 40% were prepared based on method mentioned in Voigt, 1994.⁶

Treatment of Rats

Rats for this experiment were adapted for one week in a plastic cage. To make the rats do not getting stress, the environment should be clean, dry or moist, odorless, and have pretty good air circulation, temperature between 25-35 °C, have a sufficient intensity of light and avoid noise. Food composition to reach nutritious food are compromise of vitamins A 4000UI/kg, vitamin D 1000UI/kg, α-tocopherol 30mg/kg, 3g/kg linoleic acid, 4mg/kg thiamine, riboflavin 3mg/kg, pantothenic 8mg/kg, vitamin B12 50ug/kg, 10ug/kg biotin, pyridoxine 40-300 µg / kg, and 1000mg/kg kaolin.

Before making wound, rats were anesthetized topically on their xylonor gingiva using pellets. The wound was made on the labial gingiva below the mandibular central incisors using a 2 mm punch biopsy and depth of the wound on the alveolar bone.

Starfruit leaf ethanol extract 10%, 20% and 40% respectively were spread out on the group II, III and IV, whereas in group I only distilled water was applied. Each group was smeared for 1 minute using a sterile cotton bud and taken twice a day, i.e. in the morning and evening.

After 7 days of treatment, the rats were decapitated using chlorofom. Wound tissue and surrounding tissue is cut and put into pots containing 10% buffered formalin and sent to the Laboratory Faculty of Veterinary Udayana University to make microscopic preparations.

Preparation of microscopic materials

Tissue fixation was performed with a 10% buffered formalin for 24 hours. Then, the tissue was cut using a scalpel. Fixation improvement was carried out using automatic tissue processor and dehydrated with alcohol 70% -100% to clean the remnants of fixative. To clean up any residual alcohol, xylol cleaning and paraffin infiltration at temperature of 57-59 °C were carried out and forming a block of paraffin. This block cooled briefly in a freezer. Each block of paraffin was sliced to 3-4 µm thick using a microtome.

Staining process was initiated by paraffin clearance using xylol, followed by rehydration with alcohol from high concentration to low concentration to take out remaining xylol and to put water in to the tissue. Residual alcohol is removed by washing the preparat under running water and then stain with Harris Hematoxylin-Eosin.

Fibroblast counting

Fibroblast was counted by counting active fibroblast indicates by the present of large cytoplasma, soft chromatine, ovoid nucleous, apparent, This was carried out in a five field microscope view (Olympus Type CX 21) with 400 x zoom.

Data Analyzed

Data were descriptively analyzed to describe their characteristic. Data were then analyzed for their normal distribution and homogeneity by applying Shapiro-wilk for distributuion and Levene's test for homogeneity. one-way anova *was the applied to determine the treatment different and followed by LSD Post Hoc Test* to find out how big is the different.

RESULTS

There were 37 of male *Rattus novergicus* age of 2 months and weight between 180 – 200 g, used as samples. A number of 5 rats were applied for obtaining pretest data. The rest, 32 rats were grouped into 4 groups for treatment, i.e. group 1 as a control group treated with aquadest, group 2 treated with 10% of starfruit leaf extract, group 3 treated with 20% of starfruit leaf extract, and the last is group 4 treated with 40% starfruit leaf extract. All fibroblast data obtained were normally distributed and their variances were also homogeneous.

In this study, average number of fibroblast before treatment was 25.00 ± 0.51 . Their immunohistochemistry was presented in Figure 1.

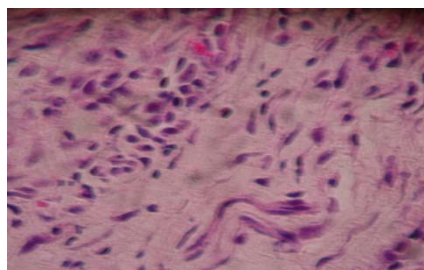


Figure 1
Immunohistochemistry of pretest data

Treatment effect analysis was performed based on number of fibroblast between groups after treated with starfruit extract. The significant test was determined using *One Way Anova* and the results was presented on Table 1. This table reveals that average number of fibroblast in control group was 25.00 ± 0.67 , and for the treatment groups, i.e group 1, group 2, and group 3 were 27.23 ± 0.39 , 26.01 ± 1.14 , and 16.38 ± 0.36 , respectively. Anova test indicates that there was a significant different between groups indicates by $p = 0.001$.

Table 1
Summary of Anova Test between Groups

Groups	n	Average Fibroblast	p
1	8	25.00 ± 0.67	0.001
2	8	27.23 ± 0.39	
3	8	26.01 ± 1.14	
4	8	16.38 ± 0.36	

Immunohistochemistry of fibroblasts observed for all groups were presented in Figure 2.

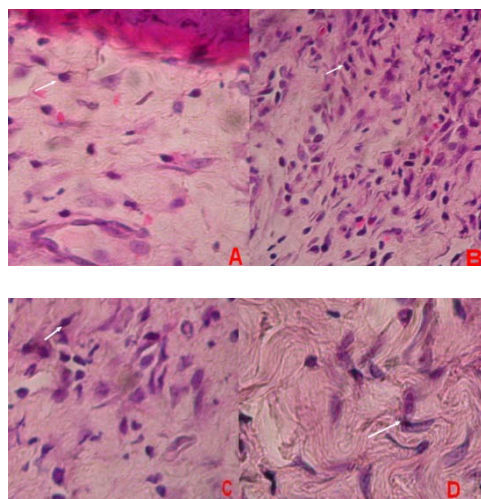


Figure 2
Fibroblast Observed with H-E Staining (400 zoom)
A. For group 1 (control), B. Group 2 with 10% Starfruit Leaf Extract, C. Group 3 with 20% Starfruit Leaf Extract, and D. Group 3 with 40% Starfruit Leaf Extract

DISCUSSION

The different test between four groups after treatment was tested using Anova. The results indicate that there was a significant different of number of fibroblast between group after treatment with p value of 0.001.

Fibroblast increase in some treatment groups after treatment were due to bioactive contents of the starfruit leaf extract, such as flavonoid, tanin, saponin, alkaloid and antioksidant. Flavonoid, saponin and tanin have an effect as antiinflammatory, antibacterial, and increase of fibroblast ploriferation.

Some of active ingredient of star fruit, such as saponin improve extracellular matrix metabolism and activate of TGF- β synthesis that stimulate of collagen biosynthesis.⁹ Then, inflammatory processes was decrease by antiinflammation effect of flavonoid and saponin, therefore, wound can be healed faster.

Research by Sudarsono, et al. (2002), indicates that natural chemistry incidence in starfruit that suspected as an antiinflammatory is flavonoid and saponin. Research by Fahrani (2009), indicates that starfruit extract contain flavonoid, saponin and tanin.¹¹ Other research by Jannah et.al. (2010), stated that aquadest extract of starfruit leaf tested was potent as an antibacteria that caused fish decay, i.e. *M. Luteus* and *P. Flurescens*.¹² The active component

act as an antibacterial was tannin. Ilham (2007), reported that starfruit tested against 1,1-Diphenyl-2-Picrylhydrazyl (DPPH), was probably active as an antioxidant.¹³ Biworo, et.al. (2004), in their research of antioxidant enzymatic test of starfruit infuse obtained that this infuse was potent for analgesic.¹⁴

This study and supported by other researchs obtained that starfruit leaf was proven for healing rats gingival wound. This is probably due to the bioactive contents of the leaf, i.e. flavonoid, saponin, tannin, alkaloid and antioxidant. The leaf of starfruit also contains high contents of nutritious material, such as calorie, protein, carbohydrate, calcium, phosphorus, iron, vitamin A, vitamin B1, vitamin C.¹⁵

Flavonoid one of the important component found in starfruit leaf plays an important role that the fruit has an ability as an antiinflammatory. This is probably due to flavonoid inhibits some enzymes, such as aldose reductase, xanthine oxydase, phosphodiesterase, lipooxygenase and cyclooxygenase.¹⁶ Formation of inflammation process mediator was facilitated through enzyme cyclooxygenase and lipooxygenase cycle in arachidonate acid metabolism assisted by difasilitasi melalui jalur enzim dari metabolisme asam arakidonat.¹⁷ Saponin is a strong lowering surface tension material that acts as an antimicrobe through disturbance of bacteria membrane cells stability which leads to cells lysis.¹⁷ This is probably because of saponin as a semipolar material could dissolve in lipids and water, therefore, this material will concentrate in subtle and important membrane cells.

Other component of starfruit leaf that acts as antimicrobial is tannin. Mechanism of how tannin has an antimicrobial property was related to activation of microbe cells adhesion on the host surface.¹⁷ Tannin has a target of polypeptide membrane cells cause damaging of the membrane due to the phenolic properties of this material. Starfruit leaf also contains peroxides components that acts as an antipyretic. Peroxide is an oxidator and their action depend on oxygen release ability to destroy the microorganism.

Increase of fibroblast in this study obtained was increase on treatment of 10% and 20% starfruit extract and decrease on treatment of 40% starfruit extract. This is in line to statement of Volk and Wheller (1993), that phenol and its derivatives are antibacterial in which their action based on disturbance of cytoplasm cell function. When applied in high concentration leads to destruction of cytoplasm and precipitation of cells protein resulted in damaging and lysis of bacteria.^{18,19} Wound healing process was not only involving of local regeneration, instead of a process as a whole involving endogenous factors.¹⁹ Increase of fibroblast as an indicator of wound healing was observed on treatment of 10% and 29% starfruit extract compared to control and 40% starfruit extract.

CONCLUSION

In this study, it was observed that starfruit (*Averrhoa Bilimbi* Linn) has an ability to heal a gingival wound in rats as indicated by formation of fibroblast during the wound healing. The best starfruit concentration extract observed for healing is 10% indicates by the higher fibroblast obtained.

ACKNOWLEDGEMENT

The author would like to thank Prof.Dr.dr. Nym. Mangku Karmaya, M.Repro., PA(K) and Dr.dr. Bgs. Km Satriyasa, M.Rep. for their help, aids during research and writing this paper. Thank was also great to the dean of Faculty of dentistry and the rector of Mahasarawati University.

REFERENCES

1. Wolf, H.F., Rateitschak, K.H., Hassell, T.M. 2004. *Color Atlas of Dental Medicine: Periodontology*. 3th Ed. New York: Thieme Medical Publishers.
2. Adminin. 2009. Pengertian luka dan proses penyembuhan luka. *Anatomi dan Patofisiologi*. (cited 2010 nov. 4). Available from: <http://cupu.web.id.htm>.
3. Mitchell, V., Cottrane, R.S. 2003. Repair: Cell Regeneration, Fibrosis and Wound Healing, dalam Kumar, V, Cottrane, R.S dan Robbins, S.L (Eds) *Basic Pathology*. 7th . Ed. Philadelphia: WB Saunders Company.
4. Arief, F. 2007. *Aneka Tanaman Obat Dan Khasiatnya*. Yogyakarta: Med Press.
5. Dalimartha, S. 2008. *Atlas Tumbuhan Obat Indonesia*. Jilid 5. Jakarta: Pustaka Bunda.Bashori, Y.M. 2008. Efek Antiinflamasi Ekstrak Etanol Daun Belimbing Wuluh (*Averrhoa Bilimbi* Linn) Pada Tikus Putih Jantan Galur Wistar. (cited 2009 Nov. 11). Available from:<http://etd.eprints.ums.ac.id/1425/k100040021.pdf>.
6. Voigt, R. 1994. *Teknologi Farmasi*. edisi V. (Noerono, S Pentj). Yogyakarta: Gadjah Mada University Press. 551-564.
7. Harbone, J. B. 1987. *Metode Fitokimia; Penuntun Cara Modern Menganalisis Tumbuhan*. (Padmawinata Pentj). Bandung : ITB.
8. Pocock, S.J. 2008. *Clinical Trials : A Practical Approach*. New York: John Wiley & Sons. p.128.
9. Kanzaki, T., Morizaki, N., Shiina, R., Saito, Y. 1998. Role of Transforming Growth Factor- β Pathway in The Mechanism of Wound Healing by Saponin from Ginseng Radix Rubra. *British Journal of Pharmacology*.p. 125:255-262.
10. Sudarsono, Gunawan, D., Wahyono, S., Donatus, I.A., dan Purnomo. 2002. *Tumbuhan Obat II (Hasil Penelitian, sifat-sifat dan Penggunaan)*. Yogyakarta: Pusat Studi Obat Tradisional- Universitas Gadjah Mada. 157- 158.

11. Fharani, B.G.R. 2009. "Uji Aktivitas Antibakteri Daun Belimbing Wuluh (*Averrhoa bilimbi* L) terhadap Bakteri *Staphylococcus aureus* dan *Escherichia coli* secara Bioautografi". (Skripsi). Yogyakarta: Jurusan Farmasi FMIPA UII.
12. Jannah A, Hayati E.K, Mukhlisoh W. 2010. Efektivitas Antibakteri Ekstrak Akuades dan Ekstrak Tanin Pada Daun Belimbing Wuluh (*Averrhoa bilimbi* L) secara In Vitro. *Seminar Nasional Kimia Bahan Alam*. Bandung: ITB.
13. Ilham, K., Sunardi. 2007. Uji aktifitas antioksidan ekstrak daun belimbing wuluh (*Averrhoa Bilimbi* Linn) terhadap 1,1-Diphenyl-2-Pyrcylhydrozyl (DPPH). *Tehnologi Farmasi Fakultas Teknik : Universitas Setiabudi*.
14. Biworo, A., Suhartono, E., Setiawan, B. 2004. *Aktivitas antioksidan enzimatis infus daun belimbing wuluh (Averrhoa Bilimbi Linn) dan potensinya sebagai analgesik*. Kalsel : univ Lambung Mangkurat Banjar Baru.
15. Bashori, Y.M. 2008. Efek Antiinflamasi Ekstrak Etanol Daun Belimbing Wuluh (*Averrhoa Bilimbi* Linn) Pada Tikus Putih Jantan Galur Wistar. (cited 2009.Nov. 11). Available from: [http //etd.eprints.ums.ac.id /1425/k100040021.pdf](http://etd.eprints.ums.ac.id/1425/k100040021.pdf).
16. Narayana, K. R., Reddy, M.R., Chaluvadi, M.R. 2001. Bioflavonoids Classification, Pharmacological, Biochemical Effects and Therapeutic Potential. Indian.
17. Katzung, B.G. 2001. Farmakologi Dasar dan Klinik. (Dripa, S., Pentj). Jakarta: Salemba Medika. 449-471.
18. Volk, W.A and M.F Wheeler. 1993. Mikrobiologi Dasar. (Markham, Pentj). Jakarta: PT.Gelora Aksara Pratama.
19. Hermanto, E dan Taufiqurrahman, I. 2008. *Manfaat terapi oksigen hiperbarik dalam mempercepat proses penyembuhan luka*. (cited 2009. okt 4). Available from: http://www.pdgi-online.com/v2/index.php?option=com_content&task=view&id=732.