

# Small Bowel Malignancy in Patient with Obscure Gastrointestinal Bleeding in Cipto Mangunkusumo Hospital, Diagnosed Using Double Balloon Enteroscopy: A Case Series

*Hasan Maulahela, Achmad Fauzi*

Division of Gastroenterology, Department of Internal Medicine, Faculty of Medicine Universitas Indonesia/Dr. Cipto Mangunkusumo General National Hospital, Jakarta

## **Corresponding author:**

*Achmad Fauzi. Division of Gastroenterology, Department of Internal Medicine, Dr. Cipto Mangunkusumo National General Hospital, Jakarta. Jl. Diponegoro No. 71 Jakarta Indonesia. Phone: +62-21- facsimile: E-mail: ppfauzidrgm@gmail.com.*

## **ABSTRACT**

*Small bowel malignancy is still a rare case as a cause of gastrointestinal bleeding. The symptoms of small bowel malignancy are not specific. One of the symptoms is obscure gastrointestinal bleeding. Obscure gastrointestinal bleeding (OGIB) is defined as recurrent or persistent gastrointestinal bleeding when the result esophagogastroduodenoscopy and colonic endoscopy is negative. OGIB accounts for approximately 5% of all gastrointestinal bleeding events. Most OGIB events are attributable to small bowel disease. Double-balloon enteroscopy, also known as push-and-pull enteroscopy is an endoscopic technique for visualization of the small bowel. Here we present 5 cases of small bowel tumours in patient with obscure gastrointestinal bleeding who underwent double balloon enteroscopy at Cipto Mangunkusumo Hospital, Jakarta, Indonesia. Three patients had confirmed gastrointestinal stromal tumour (GIST) from the histopathology examination, while 2 patients were diagnosed with adenocarcinoma.*

**Keywords:** *small bowel tumour, gastrointestinal stromal tumour (GIST), obscure gastrointestinal bleeding, and double balloon enteroscopy*

## **ABSTRAK**

*Keganasan usus halus merupakan penyebab perdarahan saluran cerna yang sangat jarang. Gejala yang timbul pun tidak spesifik. Salah satu gejala yang sering dijumpai adalah perdarahan saluran cerna tersembunyi. Perdarahan saluran cerna tersembunyi (PSCT) adalah perdarahan saluran cerna yang berulang dan persisten, namun hasil pemeriksaan esofagogastroduodenoskopi dan kolonoskopi normal. PSCT terjadi pada sekitar 5% dari seluruh perdarahan saluran cerna. Sebagian besar PSCT akibat dari gangguan pada usus halus. Enteroskopi balon-ganda, atau dikenal sebagai enteroskopi dorong-tarik, adalah teknik endoskopi untuk memvisualisasikan usus halus. Tulisan ini mempresentasikan lima kasus tumor usus halus dengan PSCT yang menjalani enteroskopi balon-ganda di RS Ciptomangunkusumo, Jakarta, Indonesia. Tiga pasien terbukti gastrointestinal stromal tumor (GIST) dari pemeriksaan histopatologi, sementara dua pasien lainnya mengalami adenokarsinoma.*

**Kata kunci:** *tumor usus halus, GIST, perdarahan saluran cerna tersembunyi, enteroskopi balon-ganda*

## INTRODUCTION

Small bowel malignancy is still considered as rare cases compared to other gastrointestinal (GI) tumours. The incidence is approximately less than 1%<sup>1</sup>. The rarity of small bowel malignancy sometimes causes misdiagnosis in patient with occult and obscure gastrointestinal bleeding. The symptoms of small bowel malignancy are not specific ranging from abdominal cramping or pain to gastrointestinal bleeding. Malignant small bowel tumours consist of carcinoid, adenocarcinoma, lymphomas, and gastrointestinal stromal tumour (GIST).

Double-balloon enteroscopy (DBE), also known as push-and-pull enteroscopy is an endoscopic technique for visualization of the small bowel. Double balloon enteroscopy allows gastroenterologist not just to visualize small bowel but also to get sample tissue and perform therapeutics procedures. Before the advancement of enteroscopy, exploratory laparotomy was often required to diagnose small bowel tumours. Double balloon enteroscopy is a non-invasive procedure, safe and well-tolerated procedure<sup>2</sup>. Here we present 5 cases of small bowel malignancies that were diagnosed using double balloon enteroscopy in patient with obscure gastrointestinal bleeding.

### Case 1

A 14-years-old young girl who had repeated melena and severe anaemia (hemoglobin: 7,46 gr%). Esophagogastroduodenoscopy (EGD) and colonoscopy had been performed in other hospital, but the source of bleeding could not be identified. Further, the patient was transferred to our hospital. The result of both upper and lower gastrointestinal endoscopy are normal. Thus, the source of her GI bleeding was suspected to be in the small intestine, and the patient underwent per oral double balloon enteroscopy. On DBE we found a proliferative nodular mass in the proximal side of small intestine (jejunum) as a cause of gastrointestinal bleeding (Figure 1). Biopsy was taken and the result was mesenchymal tumour, suspected GIST. The patient

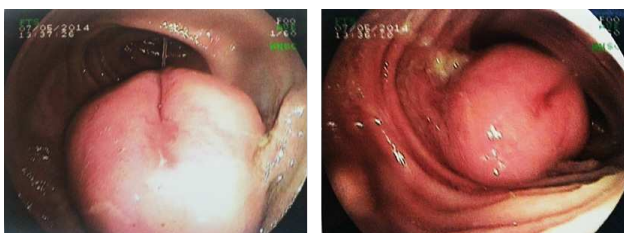


Figure 1. Double balloon enteroscopy image of a proliferative nodular mass (GIST) in the Proximal side of small intestine (jejunum) as a cause of gastrointestinal bleeding

had undergone a surgical resection tumour, and GIST was concluded by histopathology department through immuohistochemical examination.

### Case 2

A 26-years-old male came with chronic fatigue and had been diagnosed with chronic anaemia for 10 years. Patient underwent EGD and colonoscopy at local hospital. The result of EGD was erosive gastritis, and colonoscopy revealed internal haemorrhoids. Patient had melena for 8 years after the first symptoms, and the result from second EGD was normal, then he was referred to our hospital. We performed oral route double balloon enteroscopy and found distal jejunum tumour (Figure 2). From the histopathology result, it was confirmed that the tumor was gastrointestinal tumor (GIST).

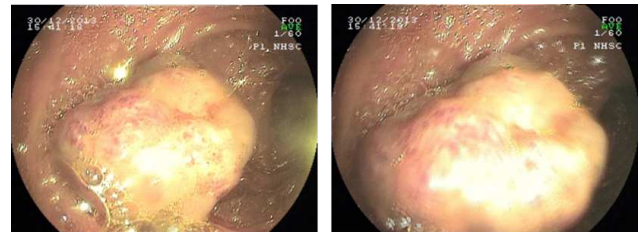


Figure 2. Double Balloon Enteroscopy image of distal jejunum mass (GIST)

### Case 3

A 49-years-old female was referred with anaemia and melena. Patient had repeated episodes of melena since 1 year before diagnosis and had multiple transfusions. She also had significant weight loss. The result from the esophagogastroduodenoscopy 1 year before showed that the patient had peptic ulcer. Since the symptom did not resolved using medication for ulcer, patient was referred to our centre. During a week before admission to our hospital, patient's symptoms became more severe with abdominal pain. She also had abdominal ultrasound and CT scan, the result was no mass or malignancy detected. We performed DBE and found a mass at jejunum, with bleeding ulcer at the mass (Figure 3.A). We also performed Argon Plasma Coagulation (APC) for the bleeding (Figure 3.B and Figure 3.C). The result of histopathology examination was GIST.

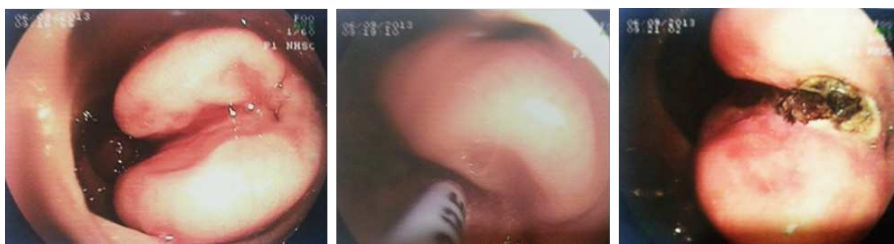

Figure 3. Double Balloon Enteroscopy image of GIST at jejunum with bleeding ulcer. We performed Argon Plasma Coagulation for the bleeding

#### Case 4

A 55-years-old male came with chronic abdominal pain (since 4 months before admission) and repeated melena. He also complained of weight loss for the last 3 months. Abdominal CT scan showed non-specific thickening of ileum wall. After his EGD and colonoscopy showed normal result, we performed DBE. From DBE, we found a granular circular mass at distal of ileum, with giant ulcer at the mass (Figure 4). The histopathology result exhibited that it was an adenocarcinoma of the ileum.

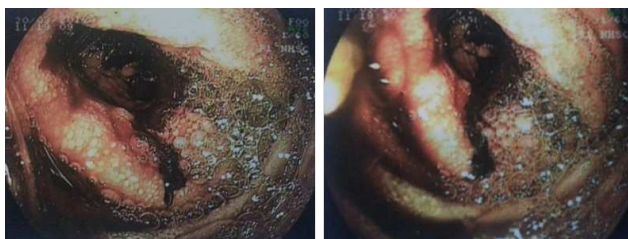

Figure 4. Double Balloon Enteroscopy image of granular mass (adenocarcinoma) at distal ileum

#### Case 5

A 52-years-old female came to our hospital with hematochezia since 6 months before hospital admission. Patient complained of weight loss and rare abdominal cramping. The EGD result was normal. From the colonoscopy we still found fresh blood but there was no clear source of bleeding. After colonoscopy procedure, we decided to do DBE. The result of DBE revealed a granular mass at proximal jejunum (Figure 5). The result of histopathology examination was adenocarcinoma of jejunum.

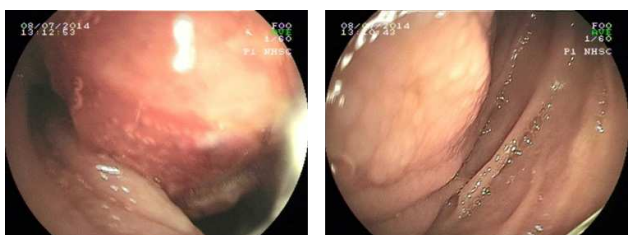


Figure 5. Double Balloon Enteroscopy image of adenocarcinoma of proximal jejunum

#### DISCUSSION

Small bowel tumour has low incidence (1-2%) compared to other gastrointestinal tumours although the length of small bowel comprises approximately 75% of gastrointestinal system<sup>3</sup>. Difficulties in diagnosing small bowel tumor caused by its vague symptoms and difficult to access using standard upper and lower gastrointestinal endoscope. The invention of capsule endoscopy and enteroscopy (single and double balloon) helps to discover what previously difficult to access area. Double balloon enteroscopy allows us to obtain tissue sample and perform therapeutic procedures compares with capsule endoscopy.

Data from National Cancer Data Base in the United State shows that carcinoid and adenocarcinoma are the most common small bowel tumour (44% and 33%).<sup>4</sup> While data from Japan multicentre study in patient underwent DBE showed that lymphomas and GIST were the most common small bowel tumour<sup>5</sup>. The result from single centre Chinese study from 78 patients with small bowel tumour shows adenocarcinoma was the most common tumour, followed by lymphoma and GIST<sup>6</sup>. From our case series (Table 1) we found most of the tumours were gastrointestinal stromal tumor. Studies with larger samples are still needed to confirm this finding in Indonesia.

The mean age for small bowel tumour in the United States is 65 years old<sup>7</sup>. In this case series we found that the age range (14-55 years old) is younger than the mean age from that find in United State. This phenomenon was possibly due to earlier exposure of carcinogen (environmental factors) or genetic factors which needs further investigation.

Most patients from these case series came to our hospital after repeated episodes of gastrointestinal bleeding (Table 1). In patient no 2 and 3 the result of upper gastrointestinal endoscopy showed a source of bleeding (peptic ulcer and erosive gastritis) but the recurrence of bleeding after optimal therapy made us further evaluate them with double balloon enteroscopy. Another patient had melena and haematochezia with no clear source of bleeding from upper and lower

gastrointestinal endoscopy. Abdominal pain or cramping was also symptoms that correlated with small bowel malignancy like we found in case number 4.

In case no 3 and 4 the abdominal CT could not detect mass or lesion in the small bowel. Abdominal CT imaging can miss tumours or lesion in the small bowel especially if the size is less than 10 mm<sup>8</sup>.

In summary the double balloon enteroscopy helps to diagnose the cause of obscure gastrointestinal bleeding. Small bowel tumour is one of the rare causes of obscure gastrointestinal bleeding.

### Conflict of Interest

No conflict of interest with any financial organization regarding the material discussed in this manuscript

### REFERENCES

1. Siegel R, Naishadham D, Jemal A. Cancer statistics, 2012. *CA: a cancer journal for clinicians* 2012;62:10-29.
2. Heine GD, Hadithi M, Groenen MJ, Kuipers EJ, Jacobs MA, Mulder CJ. Double-balloon enteroscopy: indications, diagnostic yield, and complications in a series of 275 patients with suspected small-bowel disease. *Endoscopy* 2006;38:42-8.
3. Moglia A, Menciassi A, Dario P, Cuschieri A. Clinical update: endoscopy for small-bowel tumours. *Lancet* 2007;370:114-6.
4. Bilimoria KY, Bentrem DJ, Wayne JD, Ko CY, Bennett CL, Talamonti MS. Small bowel cancer in the United States: changes in epidemiology, treatment, and survival over the last 20 years. *Annals of surgery* 2009;249:63-71.
5. Mitsui K, Tanaka S, Yamamoto H, Kobayashi T, Ehara A, Yano T, et al. Role of double-balloon endoscopy in the diagnosis of small-bowel tumors: the first Japanese multicenter study. *Gastrointestinal endoscopy* 2009;70:498-504.
6. Chen WG, Shan GD, Zhang H, Li L, Yue M, Xiang Z, et al. Double-balloon enteroscopy in small bowel tumors: a Chinese single-center study. *World journal of gastroenterology* 2013;19:3665-71.
7. Hatzaras I, Palesty JA, Abir F, Sullivan P, Kozol RA, Dudrick SJ, et al. Small-bowel tumors: epidemiologic and clinical characteristics of 1260 cases from the connecticut tumor registry. *Archives of surgery (Chicago, Ill : 1960)*. 2007;142:229-35.
8. Cheung DY, Lee IS, Chang DK, Kim JO, Cheon JH, Jang BI, et al. Capsule endoscopy in small bowel tumors: a multicenter Korean study. *Journal of Gastroenterology and Hepatology* 2010;25:1079-86.