

Can uterine rupture be prevented: Case series in Zainoel Abidin Hospital, Banda Aceh, Indonesia

Eva Febia and Mohammad Andalas

Department of Obstetrics and Gynecology, Faculty of Medicine Universitas Syiah Kuala, Banda Aceh, Indonesia; Zainoel Abidin General Hospital, Banda Aceh, Indonesia.

Abstract. The incidence of uterine rupture was devastating to the outcome of mother and the baby. This serial cases were to evaluate and analyze many factors which contributed to uterine rupture in Zainoel Abidin Hospital, Banda Aceh. Six serial cases of uterine rupture in almost one year (January 2011-Augustus 2011) were analyzed. There were six cases of uterine rupture. All cases happened in patients with previous caesarean sections. There were two cases in patients with classical previous caesarean section incision. One case happened in patient with previous caesarean section eleven months ago or short delivery interval. Two cases happened in prolonged of the second phase of labor more than 4 hours. One cases happened in second phase of labor less than one hour. Among six cases, there was one perinatal death in uterine rupture due to prolonged second phase of labor more than 5 hours. Previous classical uterine incision, second phase of labor, and inter-delivery time in previous Caesarean Section were contributing factors to the incidence of uterine rupture that can be predicted. So many ways can be used to prevent them.

Keywords: uterine rupture, classical incision, inter-delivery time

Introduction

Uterine rupture is a life-threatening event, resulting in serious complications, including peripartum hysterectomy, hemorrhage, shock, and even maternal and newborn mortality. It is more likely happen in prior uterine scar after cesarean section. Concern about the complication of uterine rupture have led to significant decline in attempted vaginal birth after cesarean (VBAC).

Several factors have been associated with uterine rupture, including induction of labor, number of previous cesareans, inter-delivery interval, type of uterine closure during previous cesareans, prior vaginal delivery, maternal age, gestational age at delivery, and birthweight. If we were able to accurately predict uterine rupture then we could select patients at high risk of uterine rupture in order to prevent the complication in VBAC.

In this case-series we would like to report six cases of uterine rupture descriptively in order to characterize what risk factors happen to the six case of uterine rupture in Zainoel Abidin Hospital from January 2011 until October 2011. We tried to discuss what are the risk factors of uterine rupture cases and thought of policies to enhance the safety of VBAC.

Material and Method

This is the case series of six cases uterine rupture in Zainoel Abidin General Hospital. Uterine rupture was characterized by complete disruption of the prior uterine scar in association with at least one of the following associated symptoms or signs: laparotomy for hemorrhage or hemoperitoneum, excessive injury to the uterus necessitating hysterectomy, injury to the bladder, extrusion into the peritoneal cavity of any portion of the fetoplacental unit, or nonreassuring fetal testing or suspected rupture.

The first case was Mrs F, 34 years old, G2P1, 39 weeks of gestational age, came to our hospital due to the process of labor. She was referred by midwife because of previous caesarean section. On physical examination we noticed the previous Pfannenstiel incision scar. There was history of caesarean section five years ago because it was said to the family that there was no progress in labor. The birth weight of the baby from the previous caesarean section was 2800 gram. On obstetric examination the baby was head presentation, 4/5 palpable on abdominal examination, fundal height was 36 cm, and estimated fetal weight was 3565 gram. Fetal heart rate was 136 beat per minute with regular contraction 2 times in ten minutes with duration of 30 seconds. The pelvic examination revealed that promontorium was not palpable, linea terminalis was palpable ¼-1/4, sacrum concave, interspinosus diameter was greater than 9.5 cm, and pubic arch greater than 90°. The portio was soft, axial, and thin, with three centimeter of cervical dilatation, intact amniotic fluid, the baby's head on Hodge 1. We assessed as G2P1 at term pregnancy, in labour with previous caesarean section. We planned the vaginal birth after

caesarean for this patient because of Pfannenstiel incision and good progression in labor of this patient. In ten hours, this patient entered phase two of labor, with full cervical dilatation, the baby's head on Hodge three. Because there was no progress in phase two of labor in one hour we tried vacuum extraction. One vacuum extraction was tried and it was heavy, so we proceed directly to caesarean section. On operation table, when the peritoneum was incised, we were so surprised to see blood clot surround the uterus from the lower segment until the uterine corpus corresponding to uterine rupture on previous classical uterine incision [Figure 1]. We delivered the female baby, 3200 grams, Apgar Score 8/9. We tried to conserve the uterus, so we did debridement and hysteroraphy of the uterus. We succeed to control the bleeding and we did tubal sterilization for this patient. This patient was given packed red cell transfusion for 350 cc and she was discharged in good condition.

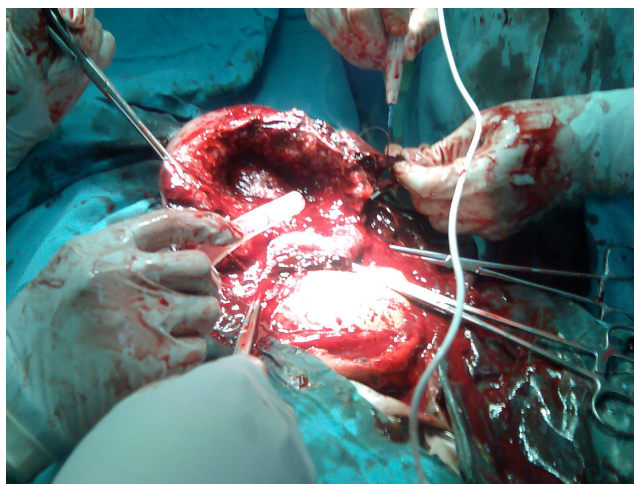


Figure 1. Rupture on previous classical uterine incision was found in patient Mrs F with Pfannenstiel incision of abdominal wall.

The second case was Mrs R, 30 yo, G2P1 on 40 weeks 2 days of gestational age, referred to our hospital because of painful contraction, previous cesarean section 25 months ago because of dystocia. When she came we noticed firm abdomen and pathological retraction Bundle ring, irregular fetal heart rate of 50 beats per minute, full dilatation of the cervix, baby's head in Hodge II. Because of fetal compromise and symptomatic uterine rupture, we proceeded straightly to cesarean section. During surgery, there was complete rupture on the previous uterine scar [Figure 2]. We delivered 3400 g baby boy, 50 cm, with a 1-minute APGAR score of 3 and a 5-minute APGAR score of 4 who died three hours ago because of severe asphyxia. The third case was Mrs T, 32 yo, G2P1 on 41 weeks of gestational age, referred to our hospital on prolonged second phase of labor (second phase of labor for 3 hours). There was history of drinking Fatimah leaf, traditional herbs used to enhanced contraction with uterotonic effect of the uterus. We also notice pathological ring, blood on urine catheter, and variable deceleration on cardiotocography. During cesarean section there was incomplete rupture on the anterior site of previous lower uterine incision. The 3200 gram-baby, even though asphyxiated, was able to be rescued, treated in neonatal intensive care and discharge eleven days later.

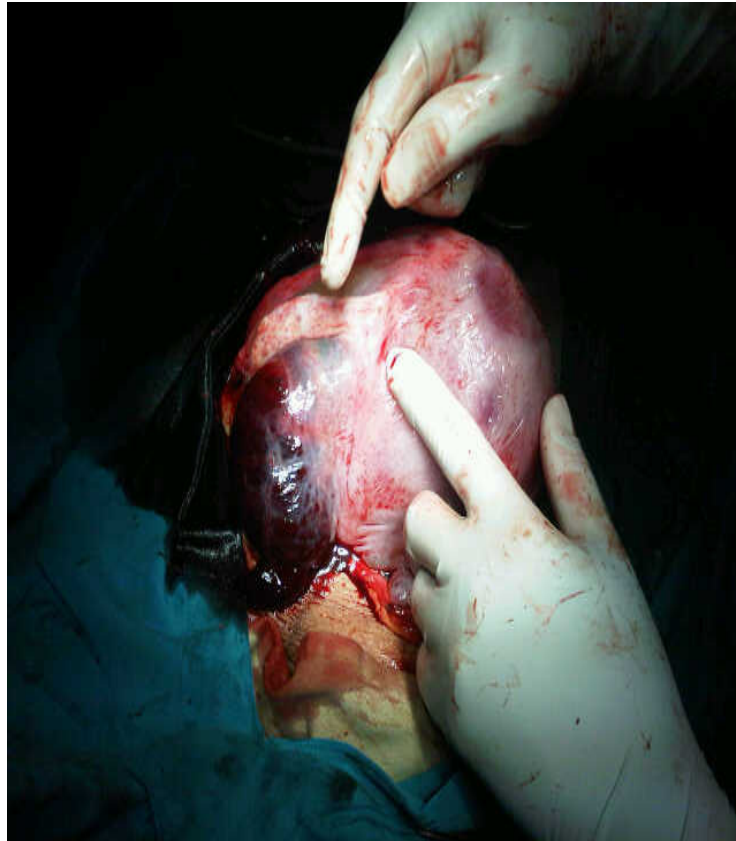


Figure 2. Uterine rupture at previous uterine scar was shown in Mrs R

The fourth case was Mrs N, 30 yo, G2P1, previous cesarean section 25 months ago, 41 weeks of gestational age who attempted VBAC in our hospital. She came on the latent phase of labor, entered active phase in 6 hours and completed active phase to full dilatation of cervix in 4 hours. On the second phase of labor there was variable deceleration on cardiotocography without any symptoms of uterine rupture [Figure 3]. On cesarean-section there was complete rupture. We delivered 3000 grams baby boy with 1-minute APGAR score of 7 and 5-minute APGAR score of 8. Mother and baby were discharge in good condition two days later.

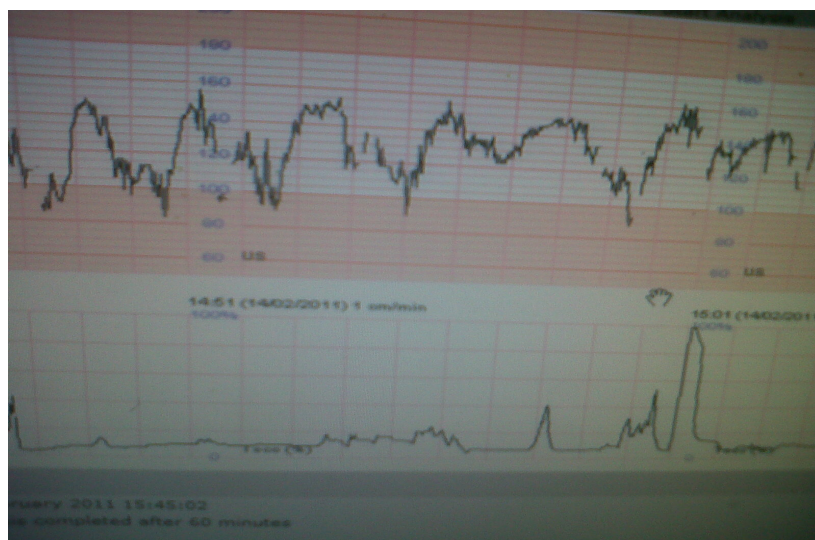


Figure 3. Variable deceleration was found on cardiotocography without any sign of uterine rupture in Mrs N

The fifth case was a booked case in our hospital, Mrs C, 27 years old, G5P4 in term pregnancy, previous cesarean section 11 months ago. She was a booked case in our policlinic planned to undergo elective cesarean section in the next seven days. She felt painful contraction at home and came to our hospital on the active phase of labor. On examination we noticed abdominal tenderness, no sign of pathological ring, and no blood in the urine. The cardiotocography revealed variable deceleration three times in ten minutes. [Figure 4]. During cesarean section we found baby shoulder just beneath the serosa layer of anterior segment of previous uterine scar. We delivered baby girl, 2700 gram with 1-minute APGAR score of 4 and 5-minute APGAR score of 8. The baby was discharge after six days care in neonatal intensive care.

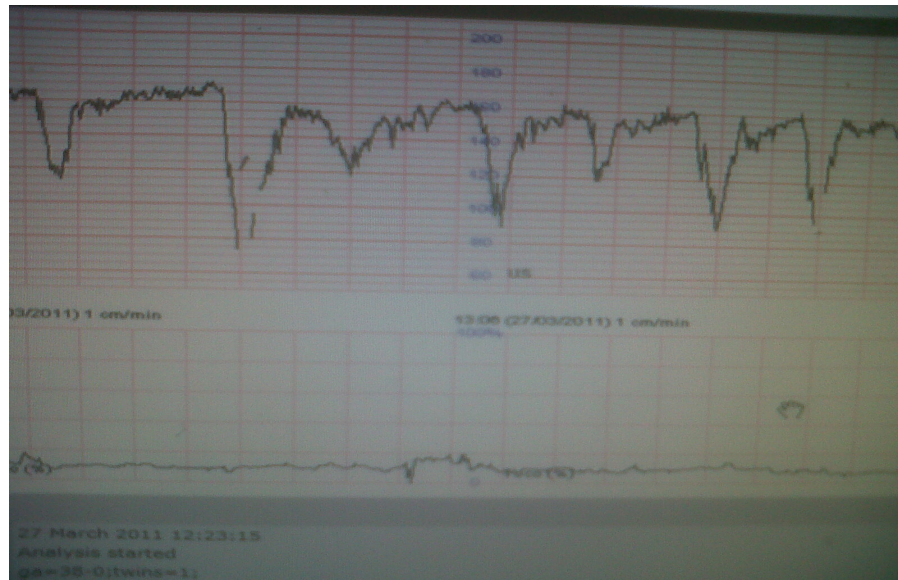


Figure 4. Repeated variable deceleration was found on cardiotocography

The six case was one mortality case of Mrs X, 37 years old, G4P3. She was brought in our emergency department in comatose condition, weak pulse, undetected blood pressure. We did resuscitation but failed to stabilize her condition. From her husband, we found out that she complaint severe abdominal pain before she fainted. She was pregnant, at 32 weeks of gestational age, previous two times cesarean section with the interdelivery time from the last cesarean section was 10 months. We noticed median abdominal wall incision. We did not find pathological ring. Because the patient already died before surgery we could not confirm the tipe of uterine incision of previous cesarean section.

Discussion

Factors that are known to increase the rate of uterine rupture appreciably during VBAC include maternal age of 30 years, history of 2 previous cesarean deliveries, no previous vaginal delivery, shortened inter-pregnancy interval, single-layer rather than double-layer closure of the uterus during previous cesarean delivery, and the use of prostaglandin or oxytocin for cervical ripening.

In these case series, two cases of uterine rupture happened in patients with prolonged second phase of labor with previous cesarean section. Two cases of uterine rupture occurred in previous cesarean section with inter-delivery time less than 12 months. There were two cases of uterine rupture which were asymptomatic. There were no pathological ring of Bundle, no blood in the urine. One sign that we noticed was only non-reassuring fetal heart rate characterized by repeated variable deceleration in cardiotocography. Many studies supported the use of cardiotocography in diagnosis of uterine rupture, especially in the second phase of labor. We recommended the use of continous monitoring of patient with previous cesarean section that attempt VBAC, especially in the active phase of labor. Earlier diagnosis made uterine rupture identified soon so that it influenced the outcome. One referral case resulted in maternal mortality that

was caused by late diagnosis of uterine rupture. To be able to identify uterine rupture earlier, continuous fetal heart rate monitoring by cardiotocography can detect any alteration in fetoplacental circulation or cord compression which happened in early incomplete uterine rupture.

Because uterine rupture, the outcome of interest, can be confused with an asymptomatic dehiscence of the prior scar, we defined uterine rupture as separation of the uterine scar, immediately preceded by either a nonreassuring fetal heart rate pattern (determined by the treating obstetrician) or by signs/symptoms of acute maternal bleeding (systolic blood pressure [SBP] <70 mm Hg, diastolic blood pressure [DPB] <40 mm Hg, heart rate [HR] >120) or by the presence of blood in the maternal abdomen at the time of laparotomy. The first sign occurred was the alteration of fetal heart monitoring from cardiotocography. In these cases, repeated variable deceleration from cardiotocography which was persistent after intrauterine resuscitation revealed cord compression which might be caused by leaking of amniotic fluid from rupture site as well as stretching of the umbilical cord.

Advanced maternal age was one risk of uterine rupture. Almost all uterine rupture cases happened in patients aged 30 years old or older. Only one case happened in patient 27 years old in less than one year interdelivery time. According to study by Shipp T et al, age at 30 years old or older was associated by increasing rate of uterine rupture. It might be caused by the higher prevalence of classical uterine incision than lower uterine segment incision as well as the influence of tissue healing in older age patients. Type of uterine incision was proven to be associated with uterine rupture. There were two cases of classical incision of uterine rupture. Many studies showed more increased rate of uterine rupture in classical type of uterine incision compared with in lower segment of uterine incision.

In some studies showed that inter-delivery time associated with uterine rupture. Many guidelines recommended repeated elective cesarean section in patients with previous cesarean section with inter-delivery time less than 18 months. It was hypothesized to be associated with incomplete wound healing formation of uterine incision site as uterine rupture predilection.

Strategies that can be used to prevent uterine rupture were to prevent inter-delivery time less than 18 months. One effective way is by enhancing the contraceptive method for post cesarean section patients by applying intra-operative post-placental intra uterine device, inserting subcutaneous implant post-operative care in obstetric ward, as well as giving progesterone injection before patients discharged. All patients post-operatively should be encouraged to give high caloric and high protein nutrient in order to make sure the wound healing proceed perfectly. Habits of avoiding meat, egg and fish among our societies should be discouraged. All patients went home after cesarean section should be given note about the type of uterine incision. For classical uterine incision scar, doctors should give note and educate patients about the increasing rate of uterine rupture in the future if they attempt VBAC.

Uterine rupture happened in patient with prolonged second phase of labor since the lower uterine segment was getting thinner. One intervention to prevent uterine rupture is to avoid prolonged second phase of labor not more than one hour. Vacuum or forceps extraction can be used to shorten the second phase of labor in patient with previous cesarean section who attempt VBAC.

Conclusion

These case series showed uterine rupture happened in patients 30 years old or older, inter-delivery time less than 12 months, classical type of uterine incision, and prolonged second phase of labor. Using effective contraceptive method, good nutrition, shortening second phase of labor, as well as proper education and note for patients were essential strategies of uterine rupture prevention in the future.

References

Chauhan S, Martin J, Henrichs C, Morrison J, Magann E. 2003. Maternal and perinatal complications with uterine rupture in 142075 patients who attempted vaginal birth after cesarean delivery: a review of the literature. *Am J Obstet Gynecol* 189:408-17.

- Caughey A, Shipp T, Repke J, Zelop C, Cohen A, Lieberman E. 1999. Rate of uterine rupture during trial of labor in women with one or two prior cesarean deliveries. *Am J Obstet Gynecol* 181:872-6.
- Jastrow N, Gauthier R, Gagnon G, Leroux N, Beaudoin F, Bujold E. 2010. Impact of labor at prior cesarean on lower uterine segment thickness in subsequent pregnancy. *Am J Obstet Gynecol* 205:563.e.1-7.
- Macones G, Cahill A, Stamilio D, Odibo A, Peiper J, Stevens E. 2006. Can uterine rupture in patients attempting vaginal birth after cesarean delivery be predicted? *Am J Obstet Gynecol* 195:1148-52.
- Ofir K, Sheiner E, Levy A, Katz M, Mazor M. 2004. Uterine rupture: differences between a scarred and an unscarred uterus. *Am J Obstet and Gynecol* 191:425-9.
- Ofir K, Sheiner E, Levy A, Katz M, Mazor M. 2003. Uterine rupture: risk factors and pregnancy outcome. *Am J Obstet Gynecol* 189:1042-6
- Porter T, Zelop C. 2004. Vaginal birth after previous cesarean delivery: Clinical management guidelines for obstetrician-gynecologist. *ACOG Practice Bulletin* July, No 54.
- Royal College of Obstetricians and Gynecologists. 2007. Birth after previous caesarean birth. *Green-top Guideines* No. 45.
- Shipp T, Zelop C, Repke J, Cohen A, Caughey A, Lieber E. 2002. The association of maternal age and symptomatic uterine rupture during a trial of labor after prior cesarean delivery. *Obstet Gynecol* 99:585-9.
- Shipp T, Zelop C, Repke J, Cohen A, Lieberman E. 2001. Interdelivery interval and risk of symptomatic uterine rupture. *Obstet Gynecol* 97:175-7.