

# FREQUENCY OF RETINAL REDETACHMENT BASED ON THE PRIMARY REATTACHMENT TREATMENT AND INTRAOCULAR TAMPONADE

A.M.Ichsan<sup>1</sup>, Erwin Iskandar<sup>2,3</sup>, Rova Virgana<sup>2,3</sup>, Arief Kartasasmita<sup>2,3</sup>, Habibah S. Muhiddin<sup>1</sup>, Iwan Sovani<sup>2,3</sup>

<sup>1</sup>Department of Ophthalmology, Faculty of Medicine, Hasanuddin University

<sup>2</sup>Department of Ophthalmology, Faculty of Medicine, Padjadjaran University

<sup>3</sup>Cicendo Eye Hospital

## Corresponding Author:

A.M.Ichsan

Email : am\_ichsan@yahoo.com

## ABSTRACT

**Introduction:** To observe the number and presentation of retinal redetachment after primary reattachment treatment in a national eye center. **Methods:** This study was designed for observational-descriptive of the medical record from April 2011 to March 2012. Selected cases were identified on the secondary retinal surgery for retinal reattachment followed the failure of the primary treatment. Cases were then classified into 4 groups based on the primary reattachment procedure: pneumatic retinopexy (PR), scleral buckle (SB), pars plana vitrectomy (PPV), and combined SB with PPV. Furthermore, in the group of PPV and SB+PPV were then divided into 3 subgroups based on the intraocular tamponade: SF<sub>6</sub> gas, silicone oil, and heavy silicone oil. **Results:** At one-year followed-up data, the presentation retinal redetachment was 7.1%, relative to the sex female (26%) was less than male (74%) with the most common age group was 41-50 years-old. Regarding with primary reattachment treatment, cases of retinal redetachment after pneumatic retinopexy was 6%, the scleral buckle was 16%, pars plana vitrectomy was 29%, and combined sclera buckle with pars plana vitrectomy was 48%. **Conclusions:** Rates of retinal redetachment after primary reattachment treatment varied from 6% to 48%, that were performed by combined scleral buckling and pars plana vitrectomy with or without tamponade silicone oil.

**Keyword :** Retinal redetachment, pars plana vitrectomy, scleral buckle, silicon oil, intraocular gas

## INTRODUCTION

The term of retinal detachment (RD) is used to describe a separation of the neurosensory retina from the retina pigment epithelium (RPE) and the potential space is occupied by sub-retinal fluid.<sup>1,2</sup> Nearly all retinal detachments fall into one of three general categories based on the underlying cause of the RD. The first is rhegmatogenous retinal detachment (RRD), which occurs as the result of a full-thickness retinal break. The second category is traction retinal detachment (TRD) occurs when vitreoretinal adhesions mechanically detach the retina from the un-

derlying RPE. In some instances, RD may involve both RRD and TRD. The third category is exudative serous retinal detachment (ERD), this type of RD occurs due to a process, such as a tumor or inflammation resulting in accumulation of subretinal fluid without associated traction or full-thickness retinal break.<sup>2</sup>

The incidence of RRD, the most common type of retinal detachment, varies between 12.9 to 17.9 per 100,000 persons per year. The primary interventions currently used to repair RRD are pneumatic retinopexy, scleral buckle, pars plana vitrectomy (PPV), and combined PPV with scleral buckle.<sup>3</sup>

Pneumatic retinopexy (PR) is a minimally invasive surgical procedure in the treatment of primary rhegmatogenous retinal detachment (RRD). First introduced in the mid-1980s by Dominguez in Spain, and Hilton and Grizzard in the United States, this technique has been used in a variety of cases all over the world.<sup>4,5</sup> Pneumatic retinopexy involves creation of retinopexy around retinal breaks by intraocular gas injection is considered to be most successful for primary retinal reattachment in phakic patients with limited superior retinal breaks who can cooperate with post-procedure head positioning.<sup>3</sup>

The aim of buckling surgery that been introduced by Custodis<sup>6</sup> is to create an indentation of the sclera beneath the retinal break with effects to reduce the flow of fluid into the sub-retinal space, leading to resolution of the detachment.<sup>7</sup> In most vitreoretinal surgical centers, the use of scleral buckling constitutes the mainstay of treatment for rhegmatogenous retinal detachment (RRD), either alone for routine cases or combined with vitrectomy for patients with more advanced forms of the disease.<sup>8</sup>

The purported advantages of primary PPV are improved internal search for retinal breaks, elimination of vitreous traction, and removal of the vitreous as a stimulant for proliferative vitreoretinopathy, while scleral buckling relieves circumferential traction at the vitreous base and avoids post-vitrectomy cataract progression and glaucoma. As surgical practices evolve over time, it is helpful to have additional information about surgical outcomes of each type of retinal detachment repair.<sup>3</sup>

The choice of primary surgical intervention is the most important predictor of primary anatomic success and final visual outcome. The aim of this study was to investigate the existing evidence of success rate of retinal detachment repair included PR, SB, PPV, and combined SB with PPV by examining recorded data from national eye hospital Cicendo, Bandung, Indonesia. A retrospective study of representative patient's database for 1 year who experienced secondary retinal detachment treatment.

## METHODS

This study was designed for observational-descriptive of the medical record from April 2011 to March 2012. Selected cases were identified on the secondary retinal surgery for retinal reattachment followed the failure of the primary treatment. Cases were then classified into 4 groups based on the primary reattachment procedure: pneumatic retinopexy (PR), scleral buckle (SB), pars plana vitrectomy (PPV), and combined SB with PPV. Furthermore, in the group of PPV and SB+PPV were then divided into 3 subgroups based on the intraocular tamponade: SF<sub>6</sub> gas, silicone oil, and heavy silicone oil.

## RESULTS

Rhegmatogenous retinal detachment is the most common form of retinal detachment, where a retinal "break" allows the ingress of fluid from the vitreous cavity to the subretinal space, resulting in retinal separation. Retinal break refers to a full-thickness defect in the neurosensory retina. Diagnosis of RRD is often, but not universally, associated with symptoms of flashes of light (retinal photopsia), visual floaters, and peripheral and usually progressive visual field loss.<sup>1</sup>

Retinal detachment can be defined as the separation of the neurosensory retina from the underlying retinal pigment epithelium. In normal retina, the potential "subretinal space" between these two layers is closed by the retinal pigment epithelium actively pumping fluid across the retina and into the choroid.<sup>1,9</sup> Cellular interdigitation and extracellular matrix provide additional adhesion. Retinal detachment occurs when the forces of retinal attachment are overcome and fluid accumulates in the subretinal space.<sup>9</sup> Direct apposition of the retina to the RPE is essential for normal retinal function and retinal detachment involving the foveal center leads to profound loss of vision in the affected eye.<sup>1</sup> Repair of primary RRD was usually unsuccessful before Gonin demonstrated the importance of localizing and sealing retinal breaks. Scleral buckling introduced by Custodis, intraocular gasses by Norton, and development of vitreous surgery by Machemer profoundly changed the history

of RRD repair. Pars plana vitrectomy, a method originally reserved for complicated cases, is now used increasingly for primary repair of uncomplicated RRD.<sup>6</sup>

This study focused to the vitreoretinal surgeries particularly to retinal detachment repair that has been done from April 2011 until March 2012 at Cicendo Eye Hospital, Bandung, Indonesia.

Figure 1 shows the number of vitreoretinal surgeries that have been performed at Cicendo Eye Hospital. The monthly average VR surgery was 63.9, primary reattachment was 20.1, and retinal redetachment was 4.5

In figure 2, we can see that percentage of primary reattachment surgery was 31.4 % and retinal redetachment was 7.1 %.

Figure 3 shows that sexes affected more in male (74%) than those in female (26%). This finding is similar to the previous study,<sup>1</sup>

but different results reported that sexes affected equally<sup>9</sup> and Ellakwa found that males (42.5%) were less affected than female (57.5%).<sup>4</sup>

Figure 4 shows the number of RRD case was mostly affected by age group of 41-50 YO (16/29.6%) and 51-60 YO (14/25.9%). The previous studies reported that the average of presentation is around 60 years-old,<sup>9</sup> and other found the mean age was 44.25±10.85 years.<sup>4</sup>

And in figure 5, we can see the vast majority of detachments in this study require surgical intervention, and thus generally means using PR, SB, PPV, and combined SB+PPV.

Figure 6 shows the percentage of retinal redetachment based on the intravitreal tamponade which mainly divided into three sub-groups: intraocular gas (SF<sub>6</sub>), silicone oil, and heavy silicone oil.

Figure 1. Distribution of vitreoretinal surgeries at Cicendo Eye Hospital; April 2011 – March 2012

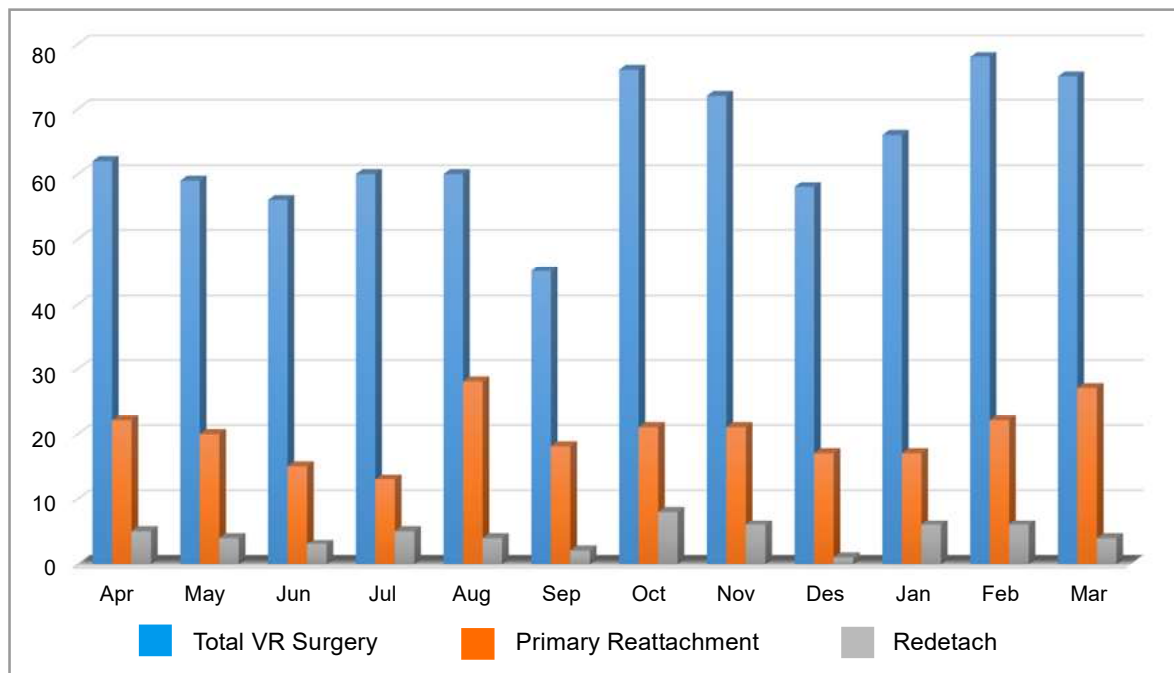


Figure 2. Percentage of vitreoretinal surgery at Cicendo Eye Hospital

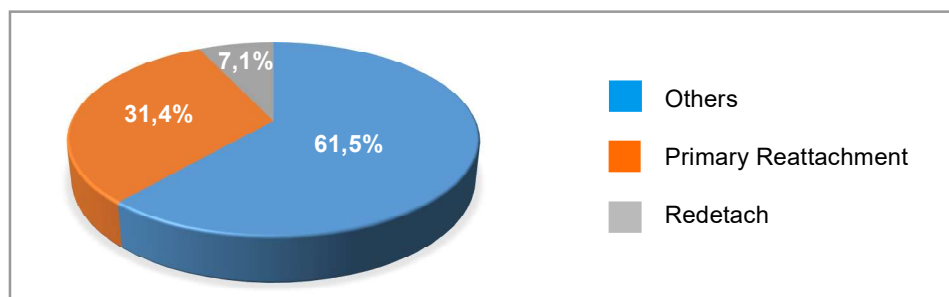
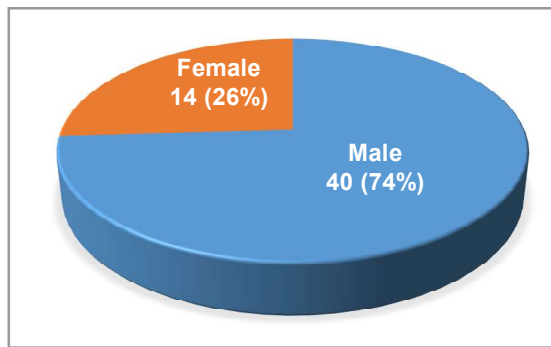


Figure 3. Distribution of retinal redetachment based on sex



## DISCUSSION

For more than a half-century, the operation most favored for primary retinal detachment has been scleral buckling (SB). Between 75-88% of cases attain permanent reattachment with one operation.<sup>10</sup> The anatomic results after scleral buckling for RRD are dependent on many preoperative and intraoperative factors. An overall reattachments rate of at least 90% is achievable.<sup>11</sup> Multiple preoperative and intraoperative risk factors have been correlated with the anatomic prognosis after SB. These include the presence of PVR, vitreous hemorrhage, choroidal detachments, greater extend of detachment, larger or giant retinal tears, hypotony, failure to identify retinal break, or injection of air, gas, or fluid.<sup>11</sup>

This study found the retinal redetachment after primary reattachment surgery by sclera buckling was 16%. Chignell et al reported success in 26 of 29 cases of retinal detachment treated with scleral buckling alone. The results were follow-up varied from 6 months to 2 years and no retinal redetachments were reported.<sup>12</sup> A larger study of SB without PR, primary success was achieved in 143 of 175 cases (82%), and final success in 158 cases (90%).<sup>7</sup> Rates of primary anatomic success for scleral buckle reported in a review of retrospective case series have ranged from 75% to 91% for 4940 eyes, and 82% in a recent retrospective case series of 227 eyes.<sup>3</sup>

Pneumatic retinopexy was first introduced in the mid-1980s independently by Dominguez and by Hilton and Gizzard as a procedure to repair RRD consist of intravitreal gas injection with transconjunctival cryopexy or laser photo-coagulation, followed by appropriate head positioning.<sup>4,5,10</sup> Pneumatic retinopexy was developed in an attempt to minimize the problems resulted by SB or PPV. PR is substantially less expensive than SB or vitrectomy and may be considered in patients who do not have detached inferior breaks, extensive retinal breaks, or significant PVR.<sup>10</sup>

This study revealed the presentation of redetachment after PR was 6%. This finding is relevant to the study reported by Shelley

Figure 4. Distribution retinal redetachment based on age group

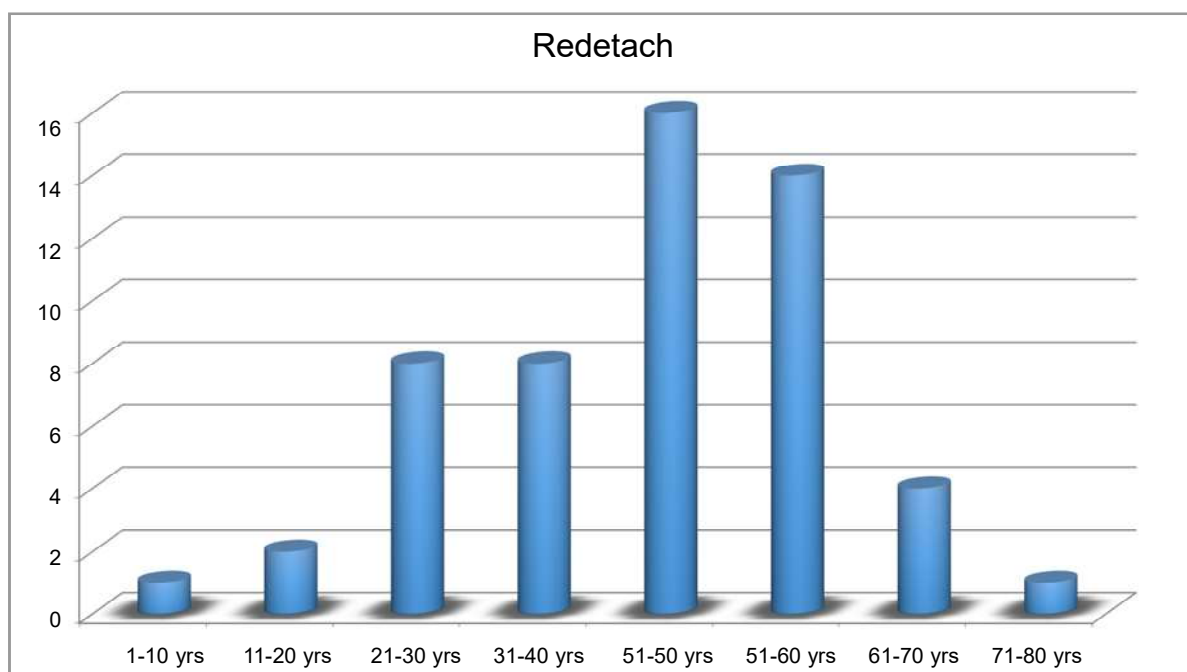


Figure 5. Distribution of retinal redetachment based on the primary surgery

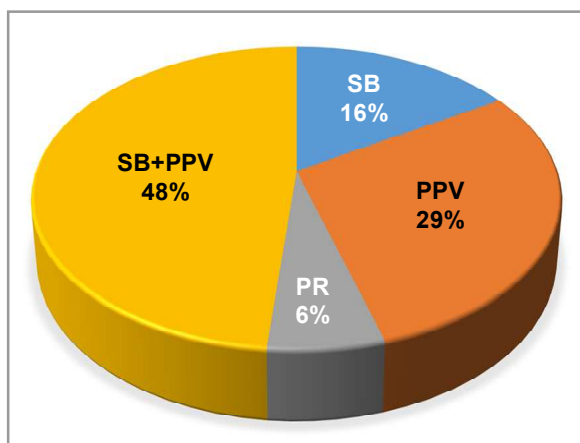
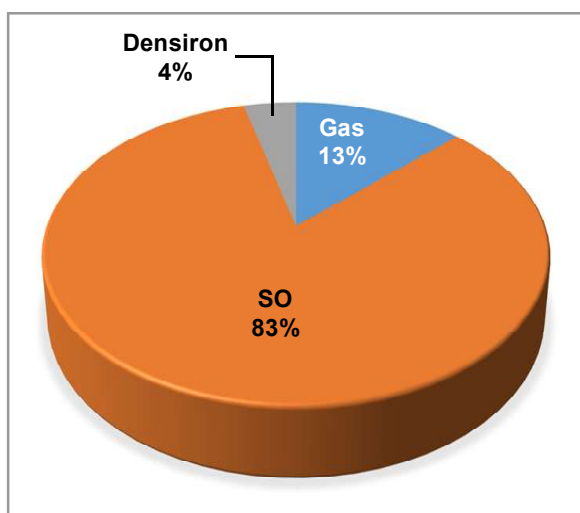


Figure 6. Distribution of retinal redetachment based on intraocular tamponade



Day et al. In their retrospective case series, they found that PPV has been shown to have the success rate of single operation ranging from 53-100%.<sup>3</sup> The other study reported thirty-three of 61 (54%) cases achieved anatomical reattachment of the retina with a single procedure. An additional seven cases were a qualified success defined as anatomical reattachment with either repeat injection of gas or laser retinopexy alone bringing the total success rate to 40 of 61 (66%).<sup>5</sup> Ellakwa et al reported the average follow-up period was 3 years. Primary successful anatomical retinal reattachment after PR was obtained in 30 (75%) out of 40 cases. Twenty-four cases (60%) achieved long-term retinal reattachment with single operation success (SOS) while six cases (15%) showed redetachment.<sup>4</sup> Freyler and Radax reported their long-term results for 89 cases of retinal detachment

treated with PR. They achieved primary reattachment in 73% of cases; in 12.36%, redetachment occurred in five eyes (5.6%) within the first month post-operatively and six eyes (6.75%) within the next 5 years.<sup>13</sup>

A recent study used pneumatic retinopexy with inverted head posturing to treat patients with inferior retinal breaks. Previously, pneumatic retinopexy was thought to be contraindicated in RRDs with inferior breaks but, as Chang's study showed, inverted posturing achieved primary success in eight of 11 subjects (82%) and final success in all subjects. The posturing involved is quite extreme and many patients would not be suitable. We can conclude, however, that inferior breaks can be managed as superior ones provided tamponade is maintained for long enough for retinopexy to take effect.<sup>14</sup>

There is a remarkable geographical difference in the acceptance of PR as the treatment of the first choice in uncomplicated primary RRD. In Europe PR, because of its lower success rate, has not found general acceptance and is used only in selected cases. Whereas the majority of North American responders (55%) selected PR as their primary choice, German surgeons preferred segmental SB or SB with an encircling band as the first procedure.<sup>4</sup>

In recent years, however, reports on vitrectomy without scleral buckling for RRD have become more frequent. Vitrectomy offers the possibility of removing vitreoretinal traction, controlled drainage of subretinal fluid, and precise laser treatment.<sup>8</sup> PPV has been used without scleral buckling for complicated RRD such as aphakia and pseudophakia with satisfactory results,<sup>14</sup> since scleral buckling may be associated with perioperative and postoperative complications leading to ocular morbidity. These include drainage problems, choroidal effusions, raised intraocular pressure, refractive changes, macular pucker, motility problems, and extrusion of the explants.<sup>7</sup> Kwong et al stated that the main reasons for performing vitrectomy and gas without scleral buckle were to avoid the possible. The high rate of final reattachment reported in the study is encouraging. Vitrectomy and gas alone is believed as an effective method to treat selected cases of retinal detachments with inferior retinal breaks.<sup>15</sup>

This study found the presentation of retinal redetachment after PPV was 29%, this is similar to the previous study reported by Shelley Day et al. In their retrospective case series, they found that PPV has been shown to have primary anatomic success rate ranging from 71-93%.<sup>3</sup> Sharma et al found the primary success rate was 81.3% for the inferior break group and 85.4% for the control group without inferior breaks. Final success rates were identical for both groups (95.8%).<sup>14</sup> A subsequent series reported on vitrectomy and fluid-gas exchange in 29 cases of RRD, reattachment rate following one operation was 79%, increasing to 93% after two operations.<sup>16</sup>

Surgeons became comfortable using vitrectomy technique since it has the advantages of an internal approach to managing cases of vitreous pathology and complex retinal detachments. Vitrectomy techniques even with a shaving of the vitreous base are not capable of removing all the vitreous, which may continue to exert traction on retinal breaks and form a scaffold for the later development of PVR. For this reason, many surgeons have advocated supplementary scleral buckling.<sup>7</sup>

This study reported 48% redetachment after failure reattachment by SB+PPV. The previous study reported that the reasons for failure after primary vitrectomy in 226 of 1446 cases were: postoperative PVR in 91/226 cases (40%), new or missed retinal breaks in 90/226 cases (40%), and reopened old breaks in 31/226 cases (14%). Additional reasons for failure included choroidal hemorrhage, endophthalmitis, and insufficient intraocular tamponade.<sup>16</sup>

The use of intraocular gas in the treatment of retinal detachment was first described by Ohm 1911.<sup>7</sup> Sulfur hexafluoride ( $\text{SF}_6$ ) and perfluoro-propane ( $\text{C}_3\text{F}_8$ ) are the gasses most frequently used with PR. Both  $\text{SF}_6$  and  $\text{C}_3\text{F}_8$  are chemically inert, colorless, odorless, and nontoxic. The value of the intraocular bubble is based on three features: buoyancy, surface tension, and isolation of retinal tears from intraocular currents.<sup>16,17</sup> In retinal detachment surgery, an intraocular gas bubble flattens the retina by providing internal tamponade.<sup>17</sup> If the bubble is larger than the retinal break, the surface tension of the gas prevents it from passing through the retinal break. When the gas bubble is positioned against the break,

the passage of fluid from the vitreous into the subretinal space is blocked, and subretinal fluid can be resorbed through the retinal pigment epithelium and choroid.<sup>17</sup>

This study found the presentation of retinal redetachment after vitrectomy with gas as intraocular tamponade was 13%. Sharma et al reported their study of management with PPV + intraocular gas tamponade without buckling of RRD with inferior breaks, they found that primary success rate was 81.3% and the final success rate was 95.8%.<sup>14</sup> Campo et al have suggested that adequate retinal reattachment rates can be obtained by using PPV and gas only, with extensive peripheral 360° laser therapy.<sup>18</sup> The other study the final anatomical success rate was 88.7% (110 of 124). In 1999 the primary success rate was 106 (84%) cases of 126. Ten cases underwent one further procedure and two had two further procedures. Final success rate was 93.6% (118 of 126). There was no significant difference in the primary ( $p=0.37$ ) or final success rates ( $p=0.08$ ) between the two groups.<sup>6</sup>

Silicone oils are linear synthetic organic-inorganic polymers have been approved by The United State Food and Drug Administration (US FDA) after Cibis et al in 1962 reported their work of successfully introduced two types of silicone oil to retinal surgery. The reattachment success rates obtained with fluid-gas exchange impeded the acceptance of silicone oil for vitreous substitution.<sup>19</sup> In the eye, the dynamics of the silicone oil tamponade involves the interplay of buoyancy, interfacial surface tension, and viscosity.<sup>19</sup>

Emulsification is considered as a complication of vitreous substitution surgery with silicone oil, since it has been demonstrated that once divided into small droplets, it may penetrate the subretinal space, or migrate into the anterior chamber and contact the trabeculum and cornea, and thus is possibly responsible for retinal toxicity, failed retinal detachment, keratopathy, and glaucoma.<sup>19</sup> In a study of 150 eyes with complicated retinal detachment, Federman and Schubert found that emulsification of SO occurred in 1% of eyes at 1 month, 11% at 3 months, 85% at 6 months, and 100% at 1 year.<sup>19</sup>

This study found that retinal redetachment after PPV with silicone oil tamponade was 83%. Johansson et al reported

their study with silicone oil 1000–5000 centistokes was used in eyes with more severe PVR. The retina was completely attached in 114 of the 131 (87%) eyes after one operation, and in 124 (95%) eyes after 2–3 operations. Re-detachments occurred after 12–78 days in 17 eyes, and were caused by progressive PVR in 10 eyes, and by new breaks in 4 eyes.<sup>8</sup>

Densiron-68 is a novel tamponade agent composed of perfluorohexyloctane, a semi-fluorinated alkane with a specific gravity of 1.35 g/cm<sup>3</sup>, solubilised in 5000 cS silicone oil. This “heavy oil” has a specific gravity of 1.06 g/cm<sup>3</sup>, and has a higher viscosity than perfluorohexyloctane to reduce postoperative emulsification.<sup>20</sup>

The inferior retina is critical in retinal detachment surgery, as it often harbors not only retinal tears but proliferative vitreoretinopathy (PVR) membranes, and is the typical site for performing large relaxing retinectomies. Heavier than water agents are available to be used in the form of perfluorocarbon liquids such as perfluoro-n-octane and perfluorodecalin. First developed by Chang and colleagues, 2 perfluorocarbon liquids are invaluable tools for manipulating the retina and displacing subretinal fluid intraoperatively. But these agents are not left in the eye for postoperative tamponade because of risks of toxicity,

suggested by animal studies but as yet unproved in human patients. Up to this point, there is simply been no way of getting around gravity, and tamponade of the inferior retina has been a frustrating gap in a repair of retinal detachment. Heavy silicone oil has been tested in primary RD repair as a medium term tamponade agent for approximately 2 weeks in duration.<sup>20</sup>

This study found the presentation of redetachment after primary reattachment surgery with heavy silicone oil as tamponade was 4%. Bhisitkul reported that the success rates with medium term PFO were encouraging, and significant retinal toxicity was not observed, but the incomplete removal of PFO was an issue, as was cataract formation and glaucoma.<sup>20</sup> Wong and colleagues describe the use of Densiron-68 for complex RD cases with inferior retinal breaks and PVR. The surgical outcomes were promising, with 81% successful reattachment with a single surgery and mean duration of tamponade of 72 days.<sup>21</sup>

## CONCLUSIONS

Rates of retinal redetachment after primary reattachment treatment varied from 6% to 48%, that were performed by combined scleral buckling and pars plana vitrectomy with or without tamponade silicone oil.

## REFERENCES

1. Fraser S., Steel D. Retinal detachment. Clin Evid. 2009; 08: 710-723.
2. Kean T., Hartnett M.E., Maurice B. Landers III. Pathogenic mechanisms of retinal detachment, In: Ryan SJ, Wilkinson CP, Scharchat AP, Hinton DR, eds. Retina. St.Louis: Mosby, 2009: 2013-2020
3. Day S., Grossman D.S., Mruthyunjaya P., Sloan F.A., Lee P. 1-year outcomes after retinal detachment surgery among Medicare beneficiaries. Am J Ophthalmol. 2010 September; 150(3): 338-345.
4. Ellakwa A.F. Long term results of pneumatic retinopexy. Clin Ophthalmol. 2012; 6: 55-59.
5. Zaidi A.A., Alvarado R., Irvine A. Pneumatic retinopexy: success rate and complications. Br J Ophthalmol. 2006 April; 90(4): 427-428.
6. Minihan M., Tanner V., Williamson T. Primary rhegmatogenous retinal detachment: 20 years of change. Br J Ophthalmol. 2001 May; 85(5): 546-548.
7. Aylward G.W. Optimal procedures for retinal detachments, In: Ryan SJ, Wilkinson CP, Scharchat AP, Hinton DR, eds. Retina. St.Louis: Mosby, 2009: 2095-2105.
8. Johansson K., Malmsjö M., Ghosh F. Tailored vitrectomy and laser photocoagulation without scleral buckling for all primary rhegmatogenous retinal detachments. Br J Ophthalmol. 2006 October; 90(10): 1286-1291.
9. Hyong K.K, Luff A.J. Management of retinal detachment: a guide for non-ophthalmologists. BMJ. 2008 May 31; 336(7655): 1235-1240.
10. Brinton D.A., Eugene S. Pneumatic tinopexy, In: Ryan SJ, Wilkinson CP, Scharchat AP, Hinton DR, eds. Retina.

- St.Louis: Mosby, 2009: 2071-2083.
11. Williams G.A., Aaberg M.T. Jr. Techniques of sclera buckling, In: Ryan SJ, Wilkinson CP, Scharchat AP, Hinton DR, eds. Retina. St.Louis: Mosby, 2009: 2035-2070.
12. Chignell A.H., Markham R.H.C.. Retinal detachment surgery without cryotherapy. British Journal of Ophthalmology, 1981, 65, 371-373.
13. Freyler H, Radax U. Pneumatic retinopexy - a study of 7 years experience. Klin Monatsbl Augenheilkd. 1993;202(3):212-217.
14. T.H. Management of primary rhegmatogenous retinal detachment with inferior breaks. Br J Ophthalmol. 2004; 88(11): 1372-1375.
15. Kwong Y.Y., Tsang C.W., Lai W.W., Lam D.S. Vitrectomy with and without scleral buckle for inferior retinal detachment. Br J Ophthalmol. 2005 June; 89(6): 784-785.
16. Heimann H., Kirchhof B. Primary vitrectomy in rhegmatogenous retinal detachment, In: Ryan SJ, Wilkinson CP, Scharchat AP, Hinton DR, eds. Retina. St.Louis: Mosby, 2009: 2085-2094.
17. Chang S. Intraocular gases, In: Ryan SJ, Wilkinson CP, Scharchat AP, Hinton DR, eds. Retina. St.Louis: Mosby, 2009: 2165-2177.
18. Campo RV, Sipperly JO, Sneed SR. Pars plana vitrectomy without sclera buckle for pseudophakic retinal detachments. Ophthalmology 1999;106:1811-5.
19. Parel J.M., Milne P., Gautier S., Jallet V., Villain F.. Silicon oils: Physicochemical properties, In: Ryan SJ, Wilkinson CP, Scharchat AP, Hinton DR, eds. Retina. St.Louis: Mosby, 2009: 2191-2209
20. Bhisitkul R.B., Gonzalez V.H. "Heavy oil" for intraocular tamponade in retinal detachment surgery. Br J Ophthalmol. 2005 June; 89(6): 649-650.
21. Kirchhof B, Wong D, Van Meurs J. Use of perfluorohexyloctane as a long-term internal tamponade agent in complicated retinal detachment surgery. Am J Ophthalmol 2002; 133:95-101.