

THE DIAGNOSTIC ACCURACY OF CHEST CT IN THE DETECTION OF TUMOR AND NODAL STATUS IN NON SMALL CELL LUNG CARCINOMA

Aziza Icksan¹, Ismid Busroh², Anwar Yusuf³, Elisna Syachruddin³

¹Department of Radiology, ²Department of Thoracic Surgery ³ and Department of Respiratory Medicine,
Persahabatan Hospital, Jakarta, Indonesia

Abstract

At this time there is an increasing demand for an accurate pre operative staging in non small cell lung cancer. Chest Computed Tomography (CT) is one of the imaging modality of choice used for this purpose. This study evaluated the accuracy of the chest CT to determine the status of the tumor and nodules in non small cell lung cancer. During the years 1998 and 1999, a descriptive prospective study of 32 patients undergoing a contrast enhanced chest CT examination for non small cell lung cancer, stage I-IIIa, was conducted. Lobectomy, lymph nodes dissection and postoperative histo-pathological examination were done. CT findings were as follows: a sensitivity of 100%, a specificity of 25% and an accuracy of 60% in the detection of the nodule stage were found. In 17 patients with adeno-carcinoma, the sensitivity, the specificity and the accuracy were 86.6%, 100% and 88.2% respectively. The diagnosis of all patients was confirmed histo-pathologically. Six patients with T2 and 26 patients with T3 were detected by chest CT; the accuracy of the tumor status was 93.7%, confirmed by surgical and histo-pathological examinations. It was concluded that the CT played an important role in determining the clinical stage of non small cell lung cancer. The specificity and accuracy were higher in adeno-carcinoma as compared with squamous cell carcinoma in detecting the nodal status.

Keywords: Chest CT, nodal status, adeno-carcinoma, squamous cell carcinoma

1. Introduction

According to American Cancer Society (A.C.S) in USA, lung cancers are the most common site of cancer, regarding both mortality and incidence, with an estimated rate of 153.000 deaths and 172.000 new cases in 1994. The mortality of lung cancer rose rapidly from 7 per 100.000 in the population in 1940 to 50 per 100.000 in the year 1990. Only 16% of lung cancers were early detected, with a survival rate of 46%¹. The most often detected type was the non small cell lung cancer (NSCLC)¹⁻⁴.

At this time there is an increasing demand for accurate preoperative staging of the lung cancers, the so-called clinical staging^{2,6-8}. It is based on the assessment of the anatomic extent of the disease before establishing definitive therapy. This covered the assessment of plain chest X-ray examination, CT scan of the chest with contrast medium, endoscopic studies including bronchoscopy, mediastinoscopy and other tests, designed to demonstrate extra thoracic metastasis. The status of the tumor and regional lymph nodes, as well as the mapping scheme of lymph nodes are major issues for staging, assigning and evaluating treatment efficacy

in patients with lung cancer^{3,9-11}. Tumor (T) and nodal (N) stages are determined according to the assessment and judgment of radiologist.

Anatomic imaging modality, such as chest and upper abdominal CT should be applied for this reason. CT could detect the detail of the anatomy of the T, the N status, and also lung, pleural and upper abdominal metastasis^{1-3,6-8,9-13}.

Studies showed that chest CT had a high accuracy and sensitivity. N status could be detected in 70 - 90 %, therefore the accuracy rate was 85% in revealing the stage of the primary T^{2,6,7,13}. Authors reported that the clinical stage decreased and the survival rate increased due to giving neo adjuvant therapy during stage IIIa NSCLC. For these reasons, an accurate clinical staging has been needed¹⁴. Besides clinical staging, there is pathologic staging. It is based on the information obtained from clinical staging, findings at surgical and examination of the resected specimens including lymph nodes³.

The purpose of this study was to know the accuracy, sensitivity and specificity of chest CT in detecting the

stage of the T and the N of stage I – III A of type NSCLC, with histo-pathologic anatomy as the gold standard.

2. Material and Methods

In Persahabatan Hospital, 237 new cases of lung cancer in 1998 and 294 cases in 1999, including only 32 (6%) cases stage I-III A and 499 (94%) cases stage IIIB to IV, were found. The most frequently observed type was type NSCLC (72.6 %) ^{4,5}. In this descriptive prospective study, conducted from January 1998 to December 1999, 32 patients with suggested type NSCLC, clinical stage I - III A according to TNM UICC 1997 criteria, who underwent surgery, were included. The cases consisted of 24 males and 8 females between 32 and 65 years old with a mean age of 48.5 years. The clinical stage I - III A NSCLC was determined by the medical history, physical examination, sputum cytology, bronchoscopy, trans-thoracic biopsy and various imaging procedures such as chest radiography, chest and upper abdominal CT. Bone scanning, abdominal USG and brain CT were done to exclude metastasis.

The status of the T and the N were established according to reports on radiological findings from thoracic and upper abdominal CT examination, following AJCC / TNM UICC 1997. CT was performed on General Electric Helical Sytec SRI. Standard protocol CT involved imaging from apical lung to upper abdominal area, with slice thickness of 10 mm and interval of 10 mm. In the hilar area, the slice thickness was 5 mm and the interval 5mm. CT scan was obtained using non-enhanced and enhanced scans.

The criteria of lymph nodes enlargement were as follows: size more than 1cm, peripheral enhancement or no enhancement after enhanced CT. Report of the N status according to mapping of lymph nodes. The stage of the tumor T2 and T3 were made according to TNM criteria. Some criteria, used for excluding T4, were as follows: extension of the tumor to the mediastinum not more than 3cm, extension of the tumor to the vascular system not more than 90 degree.

Clinical stage means stage before operation, included chest x ray, cytology sputum, chest and upper abdominal CT, bronchoscopy, TTb, bone scanning, abdominal USG, and brain CT.

The operation was done not more than 1 month after the CT examination and clinical staging. Type of surgery was complete resection and homo lateral lymph nodes dissection.

The histo-pathologic stage was based on the information obtained from clinical staging, findings at the operation and at the pathologic examination of the resected

specimen, including lymph nodes. The result of the clinical stage was compared by the histo-pathologic stage as the gold standard.

True positive were patients with positive lymph nodes enlargement, observed at the CT as well as at the operation and afterwards proven by histo-pathologic examination. True negative meant patients with negative lymph nodes enlargement, determined by CT and by surgery, as well as proven by histo-pathologic examination. False positive were patients with positive lymph nodes enlargement, discovered by CT and during operation, however the histo-pathologic specimen was negative. False negative meant patients with negative lymph nodes enlargement by the CT and at the operation, however the histo-pathologic specimen was positive.

True positive of the tumor meant patient with T3 by CT and according to findings at surgery. True negative of the tumor meant patient with T2 by CT and to findings at the operation. False positive of the tumor were patient with T3 by CT and T2 during the operation. False negative of the tumor meant patient with T2, T3 by CT and T3, T4 at surgery.

3. Results

The clinical stage among the 32 patients was as follows: 3 patients, stage IB (T2 N0 M0), 3 patients IIB (T3 N0 M0) and 26 patients with clinical stage IIIA (T3 N1 M0: 1 patient, T3 N2 M0: 22 patients and T2 N2 M0: 3 patients).

The location of the tumor was in the right upper lobe, in the right lower lobe, in the right middle lobe, in the left upper lobe, in the left lower lobe in respectively 14, 7, 2, 7 and in 2 patients. Therefore the tumor was found in the right lobe in 23 patients and in 9 patients the tumor was located in the left lobe.

The histo-pathologic type of the tumors was squamous cell carcinoma in 15 patients and adeno-carcinoma in 17 patients.

Before operation, we found 26 patients with T3 and 6 patients with T2 by CT, and after the operation 24 patients with T3, and 8 patients with T2. Two patients with T3 were proven by surgery to be T2. The findings at CT about the N status were as follows: 25 patients N2 positive, 1 patient N1 positive and 6 patients N0. After the operation, it was found that among 6 patients N0, 4 were negative, whereas 2 patients were positive by histo-pathologic examination. From 26 N positive before operation, we found 17 patients positive and 9 patients negative by histo-pathologic examination.

Table 1. The correlation of N status positive, between CT and histo-pathologic (PA) findings

	CT	PA
Squamous cell ca	13 patients	7 patients
Adeno ca	13 patients	13 patients
Total	26 patients	20 patients

Table 2. The correlation of the N status negative, between CT and histo-pathologic findings

	CT	PA
Squamous cell ca	2 patients	2 patients
Adeno ca	4 patients	2 patients
Total	6 patients	4 patients

Table 3. The correlation of the T status between CT and Surgery

T Stage	Chest CT	Surgery
T2	6 (2 adeno,4SCC)	6 (2 adeno,4SCC)
T3	26 (15 adeno, 11SCC)	24 (13 adeno,11 SCC)
Total	32 (17 adeno, 15 SCC)	30 (17 adeno, 11SCC)

Note : SCC = Squamous cell carcinoma

Table 4. Evaluation of the N status by CT and histo-pathologic findings

	SCC	Adeno Ca	Total
True positive	7	13	20
False positive	6	0	6
True negative	2	2	4
False negative	0	2	2
Total	15	17	32

Table 5. Evaluation of the T stage by CT and surgical findings

	SCC	Adeno Ca	Total
True positive	11	13	24
False positive	0	2	2
True negative	4	2	6
False negative	0	0	0
Total	15	17	32

Table 4 shows the N status by CT and histo pathology. True positive SCC and Adeno CA are 62.50%.

Table 5 shows the true positive T stage by CT and surgical findings are 75%.

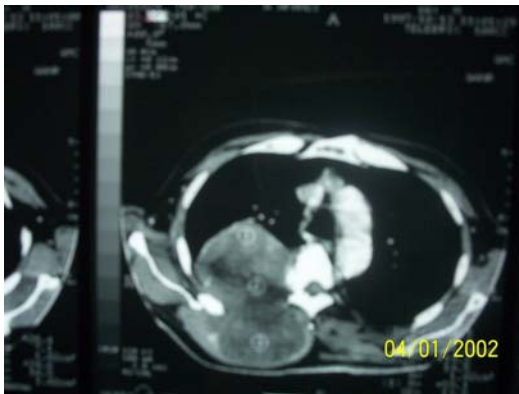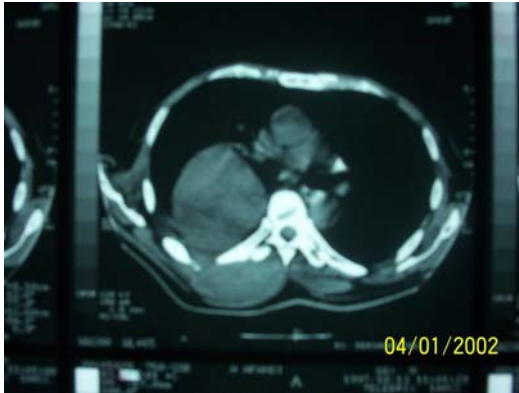In detecting the T stage, chest CT had a sensitivity, a specificity and an accuracy of 100 %, 75% and 93.7% respectively.

In this study chest CT had a sensitivity, a specificity and an accuracy in detecting the N status as follows: the sensitivity in squamous cell carcinoma was 100 %, the specificity was 25%, and the accuracy was 60%. In adeno-carcinoma the sensitivity was 86.6%, the specificity was 100% and the accuracy was 88.2 %.

Totally, in both adeno and squamous cell carcinoma, the sensitivity was 90.9%, the specificity was 40 % and the accuracy was 75%.

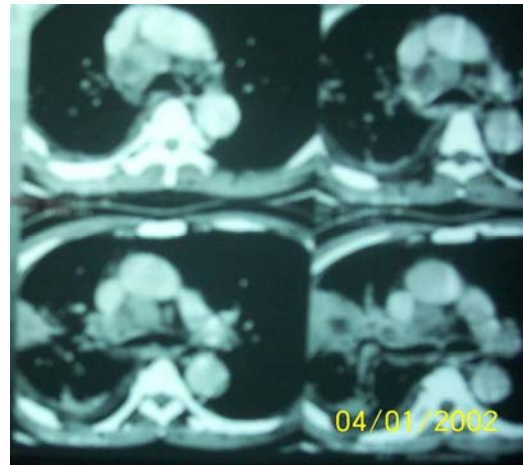
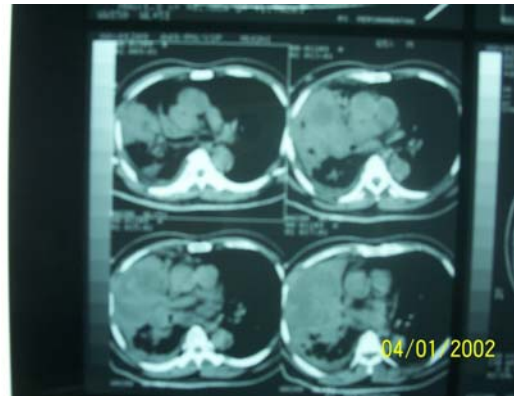
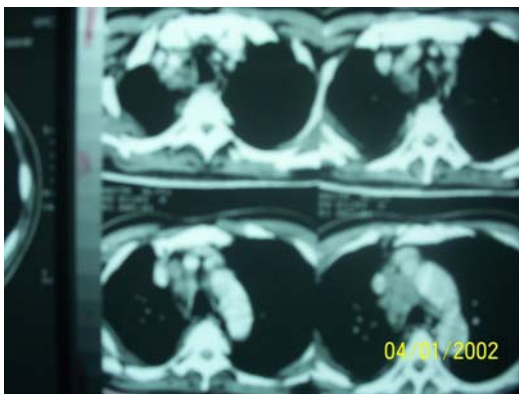
Case 1.

Chest CT of a 59 year old man with clinical stage T3N0M0 of the squamous cell ca on the right upper lung. After surgical resection of the tumor and nodal, the pathologic stage was same.



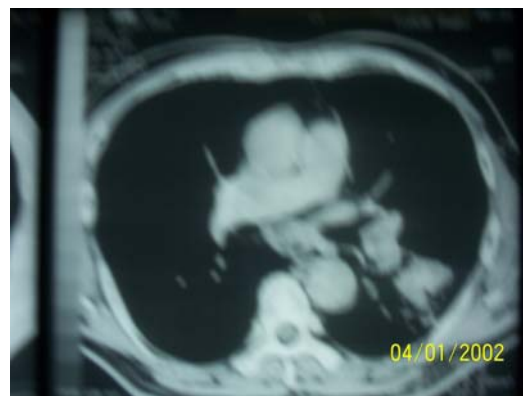Case 2.

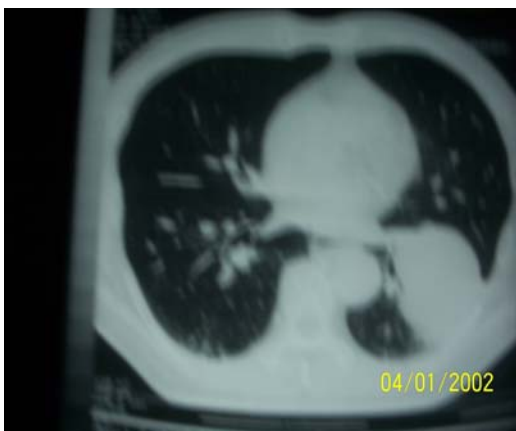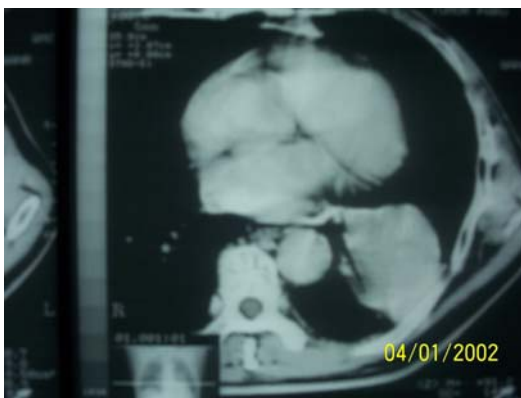Chest CT of a 62 year old man with clinical stage T3N2M0 of adeno ca on the right upper lung. After surgical resection of the tumor and nodal, the pathologic stage was same.



Case 3.

Chest CT of a 65 year old man with clinical stage T3 N2 M0 of adeno ca on the left lower lung. After surgical resection of the tumor and nodal, the pathologic stage was T2N2 M0, there is no extension of the tumor to the chest wall.





4. Discussion

From 32 patients of our study, the accuracy of chest CT in detecting the T stage was 93.7%, compared to another study of about 85%. the accuracy of chest CT to detect the N status was 75%. This finding is almost the same as others studies which reported the accuracy of CT about 70%⁶. Other studies reported an accuracy of 90%². According to our opinion, the difference of the result was possibly due to the small number of cases in our study. Especially for the negative findings by CT, the sensitivity and the specificity were higher. Like other studies, if the nodal status was negative by CT, thoracotomy has to be done immediately. Some studies have been reported, that only 7% of patients with normal size lymph nodes possibly have metastasis¹⁴. In cases with adeno-carcinoma, if there were lymph nodes enlargement (N2), detected by CT, the neo adjuvant therapy must be considered before the operation, to increase the survival rate of the patients. The neo adjuvant therapy in squamous carcinoma was not decided before the operation, because of high numbers with false positive results. Especially in patients who live in geographic regions where granulomatous

diseases is prevalent, the enlarge nodes are more likely to be benign than malignant. So in squamous carcinoma, the lymph nodes enlargement must be verified, before giving neo adjuvant therapy¹⁴.

5. Conclusions

CT has to be done in NSCLC in order to determine the clinical staging. Also CT is useful in identifying T status and macroscopic mediastinal and hilar nodal enlargement. In detecting the T status, the accuracy of CT was 93.7%, the sensitivity 100% and specificity 75%. The accuracy of CT was 75% and its sensitivity was 100 % in the detection of the nodal status of the NSCLC type. If the nodal status was negative by CT, thoracotomy has to be done immediately. The level of specificity of CT to detect the N status was higher in adeno carcinoma as compared to that of squamous cell carcinoma (100% vs 25%).

References

1. Roth JA, Ruckdeschel JC, Weisenburger TH. *Thoracic Oncology. Fundamentals of Diagnostic Imaging, Staging of Lung cancer*. Philadelphia: Saunders, 1995: 68-100.
2. Izbicki JR, Thetter O, Karg O, et al. Accuracy of computed tomographic scan and surgical assessment for staging of bronchial carcinoma. *J Thorac Cardiovasc Surg* 1985; 90: 639 – 648.
3. Zerhouni EA. Diagnosis and staging of lung cancer. *Starr II* 1997: 98 – 108.
4. Yusuf A. *Manfaat klinis pemeriksaan sitologi paru*. Konas XIII IAPI, 1999: 1-8.
5. Elisna S, Hudoyo A, Yusuf A. *Data, thoracic malignancy cases in the Department of Pulmonology, Persahabatan Hospital Indonesia* (unpublished report).
6. Ferguson MK, MacMahon H, Little AG, Golomb HM, Hoffmann PC, Skinner DB. Regional accuracy of computed tomography of the mediastinum in staging of lung cancer. *J Thorac Cardiovasc Surg* 1986; 91: 498-504.
7. Lewis JW, Pearlberg JL, Beute GH, et al. Can Computed Tomography of the chest stage lung cancer? Yes and no. *Ann Thorac Surg* 1990; 49: 591 -596.
8. Lewis JW, Madrazo BL, Gross SC, et al. The value of radiographic and computed tomography in the staging of lung carcinoma. *Ann Thorac Surg* 1982; 34: 553-558.
9. Osborne DR, Korobkin M, Ravin CE, et al. Comparison of plain plain radiography, conventional tomography, and computed tomography in detecting intra thoracic lymph node metastases from lung carcinoma. *Radiology* 1982; 142: 157–161.

10. Kiyono K, Sone S, Sakai F et al. The number and size of normal mediastinal lymph nodes, post mortem study. *AJR* 1988; 150: 771–776.
11. Mountain CF. Revision in the International system for staging lung cancer. *Chest* 1997; 6: 1710-1716.
12. Naruke T, Suemasu K, Ishikawa S. Lymph node mapping and curability at various levels of metastasis in resected lung cancer. *J Thorac Cardiovasc Surg* 1978; 76: 832 – 836.
13. Martini N, Heelan R, Westcott J, et al. Comparative merits of conventional Computed tomographic and magnetic resonance imaging in assessing mediastinal involvement in surgically confirmed lung carcinoma. *J Thorac Cardiovasc Surg* 1985; 90: 639 –648.
14. Elias AD, Skarin AT, Leon T, et al. Neoadjuvant therapy for surgically stage IIIA, in NSCLC. *Lung Cancer* 1997; 17: 147-161.
15. Watanabe Y, Shimizu J, Tsubota M, IWA T. Mediastinal spread of metastatic lymph nodes in bronchogenic carcinoma. *Chest* 1990; 97: 1059–1065.