

Kerley a line in an 18-year-old female with acute pulmonary edema and chronic kidney disease stage V

Agus Nur Salim Winarno*¹

¹Internship doctor at AM Parikesit General Hospital, Kutai Kartanegara, East Kalimantan

Case Report

ABSTRACT

ARTICLE INFO

Keywords:

acute pulmonary edema
chronic kidney disease
kerley line

*Corresponding author:

agusnur_salim@yahoo.com

DOI : 10.20885/JKKI.Vol8.Iss1.art6

History:

Received : November 11, 2016

Accepted : February 2, 2017

Online : April 26, 2017

The incidence of chronic kidney disease (CKD) continues rising recently. Chronic kidney disease is associated with many multiple complications. One of the complications related to the emergency situation is acute pulmonary edema (APE). Acute pulmonary edema is a condition where there is acute fluid accumulation in the lungs. Acute pulmonary edema can cause respiratory distress and severe hypoxia. Early recognition and initial treatment shall be considered to prevent further morbidity and mortality. This will be presented a case of 18-year-old female who came to the hospital with progressive dyspnea. After further diagnostic procedures, diagnosis of APE and CKD are constructed. Initial treatment in the emergency room did not give a good response. Then, the patient referred to the higher level hospital to receive possible dialysis treatment.

Insidensi CKD terus meningkat akhir-akhir ini. CKD bisa menyebabkan beberapa akibat. Salahsatu komplikasi yang berkaitan dengan emergensi ialah APE. APE merupakan suatu keadaan dimana terjadi akumulasi cairan di paru secara akut. APE bisa menyebabkan respirasi distress dan hipoksia berat. Perlu pengenalan awal dan tata laksana awal yang tepat untuk mencegah morbiditas dan mortalitas lebih lanjut. Disajikan kasus seorang wanita umur 18 tahun datang dengan keluhan sesak progresif. Diagnosis lebih lanjut menunjukkan adanya APE dan CKD. Terapi awal di IGD tidak menunjukkan perbaikan. Pasien kemudian dirujuk ke rumah sakit yang lebih tinggi untuk menerima terapi dialisis.

INTRODUCTION

Recently, the incidence of non-communicable diseases is increasing. The diseases can be acute or chronic. One of them is chronic kidney disease (CKD). Chronic kidney disease is a chronic disease that attracts global interest. The reason is due to either increased incidence or complications of the disease. Some factors that may contribute to the increased incidence of CKD are diabetes and hypertension.¹

Chronic kidney disease is defined as renal damage or glomerular filtration rate (GFR) <60 mL/min/1.73 m² for ≥ 3 month.^{2,3} The meaning of the damage is pathologic abnormality or

presence of damage markers, include urine test abnormality or imaging test. Then, CKD is classified into 5 categories from stage I-V based on the estimated GFR (eGFR).²

The global prevalence of CKD is about 11-13% with the majority of the cases is stage III.⁴ The incidence and prevalence in the US is estimated to increase from year to year. There is a rising prevalence among year 1988-1994 and 2003-2006 that is 18,8 % to 24,5%.⁵ Meanwhile, in Indonesia, the incidence of CKD that fall to terminal stage in 2002 to 2006 is 2077, 2039, 2594, 3556, and 4344 respectively.⁶

The complications of CKD encompass multiple

organs. The complications of CKD include anemia, hyperlipidemia, nutritional problem, osteodystrophy, and increased cardiovascular risk.⁷ One complication that has to be aware is associated with respiratory compromise. The most respiratory problem is acute pulmonary edema. This problem should be recognized early as well as treated fast. In addition, It would be effective if only it is life-threatening.

This report will be provided a case report about APE and CKD and also there will be a discussion about the radiology finding related to the complication.

CASE PRESENTATION

An 18-year-old female came to Aji Muhammad Parikesit (AM Parikesit) General Hospital with the chief complaint of dyspnea. The dyspnea has been felt since 2 weeks. The dyspnea was

intermittent, getting worse in mild activities. Then, the dyspnea became progressive so that the patient came to the emergency room. The patient did not complain a cough, wheezes, or febrile. Previous histories of asthma, allergy, or remarkable disease were denied, patient was completely healthy before. On physical exam, the patient was conscious, tachypneic, pale, and mild diaphoretic. Blood pressure was 150/90 mmHg (after taking rest about 30 minutes on the Emergency Room's bed); Heart Rate: 120 x/min; Respiration Rate : 28 x/min; T: 36,8oC; Saturation O₂ : 90% (improved to 98% on Non Rebreating Mask 10 lpm). The conjunctiva was anemic and anicteric. The thyroid was normal on inspection and palpation. There is no evidence elevated jugular venous pressure. The pulmonary exam showed no wheezing but there is a coarse rhonchi from middle to lower field bilateral.

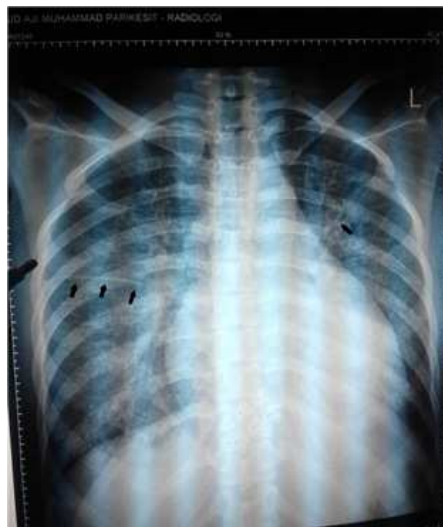

Figure 1. The patient's chest X-ray showed Kerley A line (black arrows), perihilar cephalization, and mild cardiomegaly. The line can be seen clearer in right lung than left lung.

Vocal fremitus was normal. The cardiac exam was normal. Abdomen exam was unremarkable. Extremities exam showed 2nd-degree pitting edema on both of her feet and there was 1st-degree pitting edema on both of her hands. Otherwise was normal. Then, the patient underwent ECG, chest X-ray (CXR), and laboratories. The laboratories showed normochromic-normocytic anemia (Hb 6,1 mg/dl; MCV : 85,2 fL; MCH :

31,4 pg), low hematocrit (Hct : 16 vol%), severe azotemia (Ureum: 247 mg/dl; Creatinine 11,9 mg/dl), normal electrolytes, proteinuria (dipstick +3) on urinalysis with normal erythrocyte and leukocyte. The eGFR calculation using Cockcroft-Gault formula was 6,05 (bodyweight= 50 kg, considered as stage V CKD). The ECG showed sinus tachycardia, no tall-T found. The CXR showed mild cardiomegaly with CTR 65%,

cephalic vascular pattern bilateral, and Kerley A lines on the right and left lungs. Then, the diagnosis was acute pulmonary edema; chronic kidney disease stage V (azotemia, renal anemia, hypertension stage 1); suspect nephrotic syndrome. Then, the patient received ISDN 10 mg times two, double dose intravenous Furosemide but there were no improvement and zero urine

output visible on urine bag. The dyspnea became worse and the mental status was altered. After consulted the specialist and discussed with the family, patient then referred to the tertiary hospital in order to get possible hemodialysis. Before sent to the tertiary hospital, the patient vitals and saturation were stable enough.

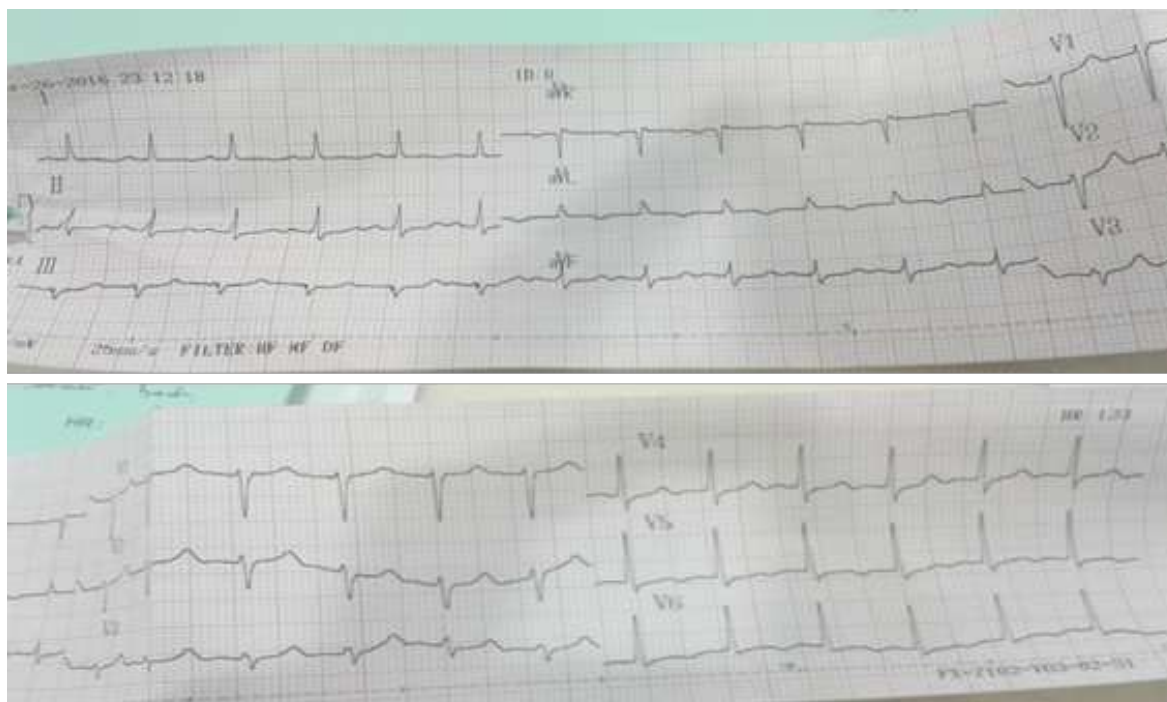


Figure 2. The ECG was obtained immediately from the patient. Sinus tachycardia is present. But, there showed no any sign of LVH, LAH, or hyperkalemia.

DISCUSSION

This case is interesting since the patient is still very young (18 years old) to have severe renal disease. The sign and symptoms are possibly insidious as the patient did not realize so much or maybe the patient were not aware of her complaints. The paramount is the patient came with the respiratory compromise. The complication probably derives from the renal-induced fluid overload which is possible acute pulmonary edema. Our initial treatment with sublingual nitrate and loop diuretic did not give a good response as our hope. Instead, the patient got worse so that we decided to refer her for better treatment. On this patient, the underlying disease is not determined yet. We

have tried to exclude by asking her histories. She denied consuming addictive drinks like energy beverages; alcohol beverages; non-prescribe drugs; or previous severe pharyngitis disease.

Acute pulmonary edema (APE) is a condition where there is the rapid accumulation of fluid within pulmonary interstitium.⁸ Acute pulmonary edema can also be termed as flash pulmonary edema. Acute pulmonary edema usually develops quickly which represents the word 'acute'. The acute condition can range from minutes to hours. That condition is usually life-threatening as it can cause severe hypoxia. Acute pulmonary edema can be heart-related (cardiogenic) or non-heart related (non-cardiogenic).^{8,9}

The diagnosis of APE should be addressed

both clinically and further examination by physical examination, electrocardiography or CXR.¹⁰ Early recognition and prompt treatment should be considered because they can be life-saving. Patients usually come to the emergency room or clinic with respiratory distress that worsens in minutes or hours. On physical exam, the patient can be hypoxic, tachypneic, and rales on auscultation. Like patient in this case, she felt shortness of breath or dyspnea that runs progressively. In the ER, she was diaphoretic and had low oxygen saturation. On the pulmonary auscultation, there was coarse rhonchi or rales both on the lung field. The preexisting condition or current laboratories or radiography should be addressed to help the diagnosis. Some diseases like CKD can be associated with EPA.⁸

One of diagnostic modality to help diagnosis is chest X-ray. A chest X-ray is commonly used to help assessing pulmonary congestion.¹¹ Especially, when there is not available other procedures like ultrasound or CT.¹¹ CXR can also help to distinguish cardiogenic and

non-cardiogenic pulmonary edema.¹⁰ One of radiographic finding in APE is Kerley line. Kerley line also known as the Septal line is prominent line seen when interlobular septae in the lungs filled with the fluid.¹² The name of Kerley derives from the discoverer, a radiologist named Sir Peter J. Kerley.¹³ There are 3 Kerley lines, such as Kerley A, Kerley B, and Kerley C.¹³ Kerley lines can be a sign multiple pathologies. One of them is pulmonary edema. Kerley A is a line that radiates from the hila to the central part of the lung or the upper lobe.¹⁴ Kerley A line rarely reaches the pleura. The length varies from 2-6 cm. The line represents thickening of the interlobular septa. Normally, the interlobular septa are invisible in the CXR, but certain condition like pulmonary edema can make it be prominent. It is probably the most prominent line seen in the radiographic CXR. The presence of the line can indicate an acute or severe degree of edema.¹³ In this case, the Kerley A line can be seen clearly in the right lung.

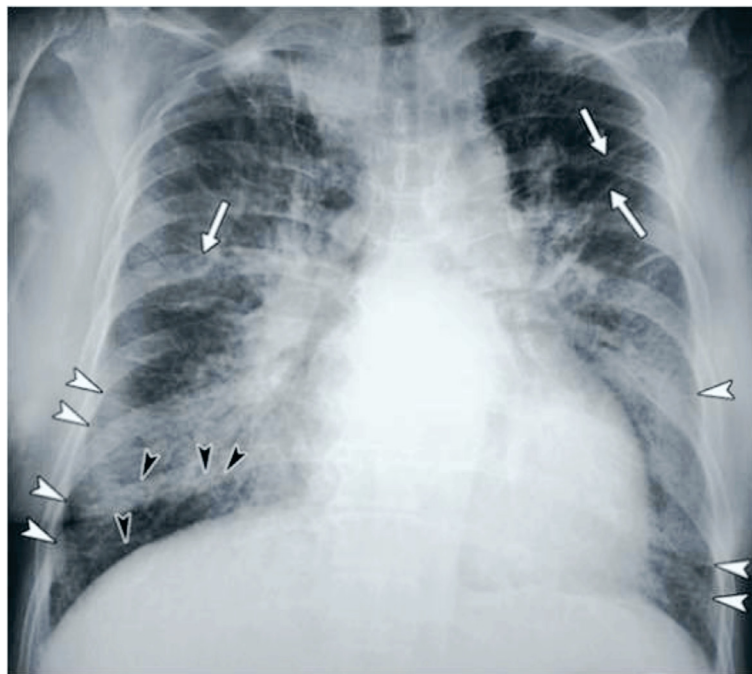


Figure 3. Example of the presence of the Kerley A (white arrows), Kerley B (white arrowheads), and Kerley C (black arrowheads) lines from a 64-old-year woman with left ventricular failure.¹³

The Kerley B line is a shorter line, approximately 1-2 cm located in the periphery of the lungs.^{13,14} The line is a transverse line that is perpendicular to the pleural space extending into the inner part of the lung. The Kerley B line is usually seen in the bases of the lung and indicates the thickening of the subpleural interlobular septa.¹⁴ The Kerley C line is reticular opacities line situated in the bases of the lung. The lines are short and probably they are the least visible line among others. In this case, the Kerley B and Kerley C line are not clearly seen. It is probably related to the cause in this patient, the APE originates from the non-cardiogenic cause. Although there is a reference says that there will be no visible Kerley A without the presence of Kerley B or Kerley C, but the Kerley B often relates to the cardiogenic cause of APE.^{8,10,15} As the radiographic finding shows only slightly cardiomegaly, there is no Kerley B line, no peribronchial cuffing, and the ECG shows no sign of LVH or LAH, we think that the EPA in this patient is non-cardiogenic.

Non-cardiogenic APE can result from volume overload, low oncotic pressure, or endothelial injuries like from toxin or acute respiratory distress syndrome (ARDS).¹⁴ In this case, the edema can possibly come from the volume overload induced by CKD. Chronic kidney disease can cause multiple complications. One of them is volume overload associated with the diminished function of the renal. The volume overload causes fluid accumulation in the pulmonary interstitium as results from increased hydraulic pressure.⁸ Another mechanism is reduced oncotic pressure in the pulmonary vessels causes the fluids within the vessels leaked out to the interstitium.¹⁴ The reduced oncotic pressure can be caused by the damage of the renal and there is protein (primarily albumin) leakage into urine. That condition is called as proteinuria and there will be hypoalbuminemia as the secondary event. Sometimes, it is difficult to differentiate non-cardiogenic APE from cardiogenic APE since the symptoms were similar and overlapped.^{8,9,10} But there are some ways to help the diagnosis like in Table 1.

Table 1. The hints to help differentiating cardiogenic APE from non-cardiogenic APE.¹⁰

<ul style="list-style-type: none"> • Historical Background and clinical findings • Chest X-ray features <ul style="list-style-type: none"> Heart size Width of vascular pedicle Distribution of edema Presence of pleural effusion Peribronchial cuffing Kerley B lines Air Bronchograms • Laboratory results <ul style="list-style-type: none"> Electrocardiography Brain natriuretic peptide Echocardiography • Pulmonary artery wedge pressure

The diagnosis of CKD in present case is based on the presence of anemia, azotemia, and hypertension. Anemia in this patient is normocytic and normochromic anemia which is considered as renal anemia since there is no acute bleeding presence. The Hb value in this patient is 6,1 mg/dL. The pathophysiology is associated with absolute or relative deficiency of renal erythropoietin synthesis.¹⁶ Hypertension is cyclic between hypertension itself and CKD.¹⁷ Hypertension can cause CKD as there is damage in the nephron with all its consequences. Chronic kidney disease can also cause hypertension via some possible mechanisms like activation RAAs, sympathetic activation, impaired sodium excretion, and reduced nitric oxide.¹⁶ Chronic kidney disease can cause declining renal function as the marker of renal function arises. Creatinine is commonly used to know how far the reduced renal function goes.¹⁸ In this patient, the creatinine level is very high which is 11,9 mg/dl (normal reference: 0,5-1,5 mg/dl). Then, the creatinine level is measured to know the estimated Glomerular Filtration Rate (GFR). Glomerular Filtration Rate is defined as the volume plasma filtered by the glomeruli per unit per time and is usually measured by

estimating the rate of clearance of a substance from the plasma.¹⁸ One tool to calculate the eGFR uses Cockcroft-Gault formula. In this patient, the calculation is 6,05 which is considered as stage V of CKD or end-stage renal disease (ESRD).^{16,18}

Initial treatment of APE-associated with CKD is about the breathing, as Airway-Breathing-Circulation rule. It shall improve the oxygen saturation and make the hemodynamic of the patient remains stable. The saturation shall be kept above 90%.¹⁹ The treatment of APE include preload reduction, afterload reduction, and inotropic support as needed.^{19,20} The medicines use to reduce the preload are nitrate, diuretics, and morphine sulfate. Nitrate can be given sublingually or via intravenous. Diuretics, especially loop diuretic is probably classical medicine used in the case. It has been used for many years. Furosemide is the most well-known medicine. The lack is it is slow onset compared to sublingual nitrate.^{19,20} Morphine sulfate is rarely used in the field since its availability and poor its beneficial supporting evidence. In the patient with CKD, there shall mull to use ultrafiltration to remove the excessive fluid¹⁹. The patient received nitrate (isosorbide dinitrate / ISDN) 10 mg each twelve hours a day via sublingual. The medicine acted as the vasodilator to reduce preload. But there was no change. Then, classic medicine in the case of acute pulmonary edema, furosemide, was given to the patient intravenously. Total dose of 40 mg is given but there is no improvement. The patient was still tachypneic. The oxygen saturation was holding at 94% with NRM on the patient. As there were no additional drug, no advanced device, and the patient condition were worsening, so we decided to refer the patient. The objective of the referral is to improve the breathing by removing the fluid accumulation via dialysis. To follow the protocol, we transferred the patient in a critical but stable condition.

CONCLUSION

Acute pulmonary edema is a condition in which there is the rapid accumulation of fluid in the lungs. It can be a consequence of a condition like CKD. The renal damage can

cause fluid overload. Acute pulmonary edema is a serious condition so that it needs a good early recognition and therapy. The diagnostic procedures encompass taking history and doing the physical exam. Other procedures like the chest x-ray, ECG, or echocardiography are possible to be obtained. In a chest x-ray, the finding includes the Kerley line which is the sign of septa thickening as result from the fluid accumulation. The management of APE shall consider the rule of ABC as another disease. The specific treatment is to reduce preload, afterload, and to give vasopressor as needed. Special consideration like patients with CKD, the ultrafiltration or dialysis can be mull to remove the fluid.

REFERENCES

1. Singh, Ajay K., Yousef MKF, Bharati VM, Kuyilan KS, Sai RKR, Vidya NA, et al. Epidemiology and risk factors of chronic kidney disease in India-results from The SEEK (Screening and Early Evaluation of Kidney Disease) study. *BMC Nephrology* 2013;14:114.
2. Anderson J, Liam GG. Definition of chronic kidney disease and measurement of kidney function in original research paper: A review of the literature. *Nephrol Dial Transplant*. 2011;26:2793-8.
3. NKF KDOQI Guidelines <www2.kidney.org/professionals/kdoqi/guidelines_ckd/p4_class_g1.htm>, accessed Oct 23, 2016.
4. Hill NR, Samuel FT, Jason LO, Jennifer AH, Christopher AO, Daniel SL, FD Richard H. Global prevalence of chronic kidney disease-A Systematic Review and Meta-Analysis. *PLoS ONE*. 2016;11(7).
5. Kidney Disease Statistics for the United States <www.niddk.nih.gov/health-information/health-statistics/Pages/kidney-disease-united-sta> Accessed Oct 23, 2016.
6. Prodjosudjadi W, Suhardjono A. End stage renal disease in Indonesia: Treatment development. *Ethn Dis*. 2009;19.
7. Thomas R, Abbas K, John RS. Chronic kidney disease and its complications. *Prim Care*. 2008;35(2):329.

8. Headley CM, Barry MW. Flash pulmonary edema in patients with chronic kidney disease and end stage renal disease. *Nephrol Nurs J.* 2007;34(1):15-28.
9. Pierson DJ. Respiratory consideration in the patient with renal failure. *Respir. Care.* 2006;51(4):413-22.
10. Murray JF. Pulmonary edema: pathophysiology and diagnosis. *Int J Tuberc Lung Dis.* 2011;15(2):155-60.
11. Cardinale L, Adriano MP, Federica M, Giovanni V. Effectiveness of chest radiography, lung ultrasounds, and thoracic computed tomography in the diagnosis of congestive heart failure. *World J Radiol.* 2014;6(6):230-7.
12. Reed JC. Chest radiology, plain film patterns and differential diagnoses. Mosby Inc. 2003.
13. Sekar T, Kenneth GS, Robert AV. A Beeline through Sir Peter James Kerley's life. *AJR.* 2011;196.
14. Khan AN, Hamdan AJ, Sarah AG, Alaa G. Reading chest radiograph in the critically ill (part II): radiography of lung pathologies common in the ICU patient. *Ann Thoracic Med.* 2009;4(3):149-57.
15. Gaggin HK, James LJ. MGH cardiology board review. Springer Science. 2013.
16. Henry Ford Health Systems. Chronic kidney disease (CKD): clinical practice recommendations for primary care physicians and healthcare providers. 2011.
17. Tedla EM, Brar A, Browne R, Brown C. Hypertension in chronic kidney disease: navigating the evidence. *Int J Hypertens.* 2011.
18. Scottish Intercollegiate Guidelines Network. Diagnosis and management of chronic kidney disease: A national clinical guideline. 2008.
19. Sovari AA. Cardiogenic pulmonary edema <emedicine.medscape.com/article/157452-overview> accessed November 1st 2016
20. Wolfson AB, Gregory WH, Louis JL, Carlo LR, Jeffrey JS, Ghazala QS. Harwood-Nuss' clinical practice of emergency medicine sixth edition. Lippincott Williams & Wilkins. 2012.472.