



Jurnal Kedokteran dan Kesehatan Indonesia

Indonesian Journal of Medicine and Health

Journal homepage : www.journal.uui.ac.id/index.php/jkki

Blood, Bone and Brain Nocardiosis Infection in an HIV-Infected Man

Muhammad Yazli Yuhana*¹

¹Faculty of Medicine, Universiti Teknologi MARA, Malaysia

Case Report

ABSTRACT

ARTICLE INFO

Keyword:

Nocardiosis
HIV
opportunistic bacterial
infection

***Corresponding author:**

aleeyuhana@hotmail.com

DOI : 10.20885/JKKI.Vol7.Iss5.art6

Disseminated nocardiosis is a rare and complicated opportunistic bacterial infection with propensity of delay in establishing the correct diagnosis and high frequency for misdiagnosis and due to the non-specific clinical presentation and the inherent difficulty in cultivating the organism. The infection is caused by gram-positive aerobic actinomycetes in the genus *Nocardia*. A definitive diagnosis requires the isolation and identification by Gram stain and modified acid-fast stain from a clinical specimen. Treatment heavily relies on species and susceptibility testing. There is a real paucity of prospective studies in nocardiosis infection, resulted in severely limited understanding of its diagnosis and treatment among the medical community. We report a clinical case of a 42-year old HIV-infected Burmese man with culture proven *Nocardia* infection.

Nocardiosis adalah infeksi bakteri oportunistik langka dan rumit dengan kecenderungan keterlambatan penegakan diagnosis yang tepat dan frekuensi misdiagnosis yang tinggi yang disebabkan oleh presentasi klinis yang non-spesifik dan kesulitan dalam budidaya organisme. Infeksi ini disebabkan oleh gram positif actinomycetes aerobik dalam genus Nocardia. Diagnosis pasti membutuhkan isolasi dan identifikasi spesimen klinik dengan cara metode pewarnaan Gram dan Acid-fast yang dimodifikasi. Pengobatan sangat bergantung pada spesies dan uji kerentanan. Ada kekurangan yang nyata dari studi prospektif pada infeksi nocardiosis yang mengakibatkan pemahaman sangat terbatas terhadap diagnosis dan pengobatan di antara komunitas medis. Kami melaporkan kasus klinis seorang pria Burma berusia 42 tahun yang terinfeksi HIV dengan hasil kultur terbukti infeksi Nocardia.

Case History

A 42-year-old man from Myanmar with no known medical illness presented with fever, drenching night sweats, headache and vomiting of four months duration together with two weeks of gradual onset left lateral chest pain. The pain was dull in nature, did not radiate to

other area nor worsen with any activity. He had lost approximately four kilograms. There was no cough, shortness of breath, skin rash, visual complaints or diarrhea. He was born in Yangon, Myanmar and has immigrated to Malaysia seven years ago. He is not married and had histories of unprotected sexual intercourses with multiple

female partners. He does not use tobacco, alcohol or illicit drugs. He works as a cashier in a local restaurant in Kuala Lumpur. He was febrile on admission with temperature of 40oC and haemodynamically stable with oxygen saturation while breathing ambient air of 98%. He was alert and fully orientated. There was presence of oral thrush. There were no abnormal skin lesions noted. Tenderness was noted on palpation over the ribs area lateral to the left nipple without abnormal skin changes overlying the area. Lungs were clear to auscultation. There was no palpable lymphadenopathy, hepatomegaly or splenomegaly. Central nervous system (CNS) examinations were normal with no evidence of nuchal rigidity. Fundoscopy examination was

unremarkable.

Laboratory and Imaging

ELISA antibody test for HIV-1 was reactive with CD4 cell counts of 152 cells/mm3. Refer Table 1 for full cerebrospinal fluid (CSF) assessment on baseline and two weeks after treatment. Computed tomography of the thorax showed destructive lytic lesion over the lateral aspect of the left fourth rib with soft tissue mass surrounding the bony lesion measuring 4.7x4.9x3.7 cm. The lung parenchyma was normal. Magnetic resonance imaging of the brain showed two small lesions over the right thalamus and right corona radiata (Figure1).

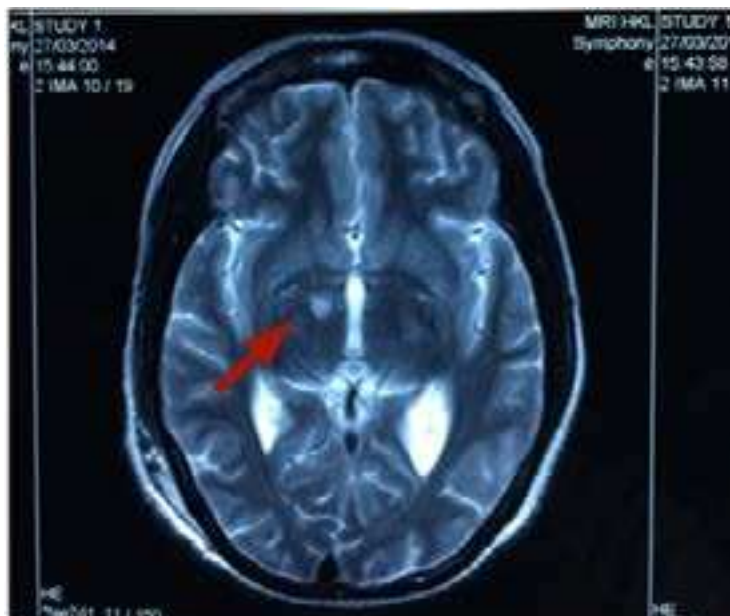


Figure 1 Hyperintense lesion over the right thalamus (red arrow)

Table 1 Cerebrospinal fluid results at baseline and two weeks after treatment

Variables	CSF Results at Baseline	CSF Results Two Weeks After Treatment
Opening Pressure (cm H20)	> 50	5
Appearance	Clear	Clear
Protein (g/L)	4.89	1.10
CSF Glucose (mmol/L)	0.30	4.0
SERUM Glucose (mmol/L)	4.6	6.3
Cells (per ml)	80 (Polymorphs)	35 (Lymphocytes)

Microbiology Culture and Sensitivity

Gram stain of the blood culture showed numerous gram-positive rods with beaded and branched appearance on modified acid-fast bacilli stain (Figure 2). The culture colony was chalky white in appearance. Species identification later confirmed of *Nocardia asteroides*. Microbial sensitivity using the E-test showed resistance to Co-trimoxazole (MIC 8 ug/ml), Ciprofloxacin (>32 ug/ml) and Vancomycin and sensitive to Amikicin, Imipenem and intermediate to Co-amoxiclav. Despite in-vitro resistance to co-trimoxazole, a course of

eight-week intensive treatment incorporating the antibiotic plus Meropenem and Amikacin was initiated. He achieved rapid and satisfactory clinical and radiological responses with repeat CT scans of the head and thorax at week four and eight of treatments. Subsequent maintenance oral therapy regime of oral Co-Amoxiclav and Co-Trimoxazole was prescribed for four months. Highly active anti-retroviral treatment (HAART) consisting of Tenofovir, Emtricitabine and Efavirenz was started at week four of intensive treatment. Patient was discharged well. He made a decision to be followed up in Yangon, Myanmar.

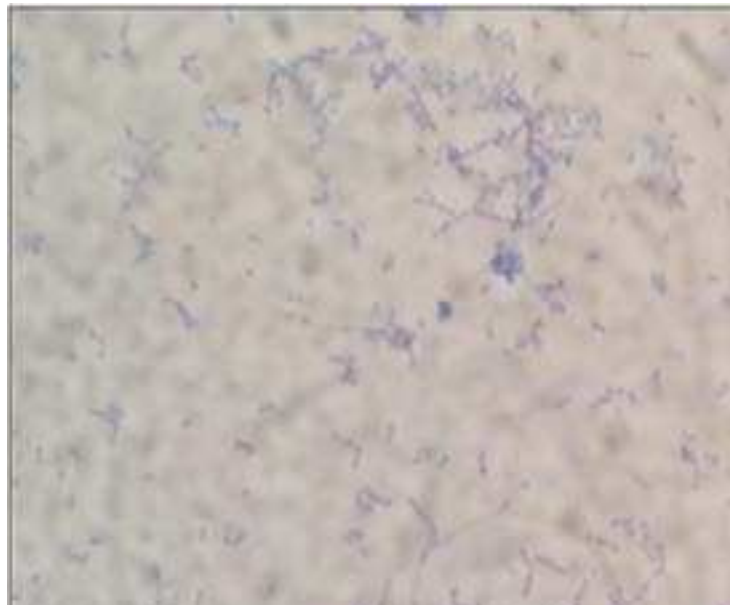


Figure 2 Patient's gram stain from the blood culture showing filamentous and beaded coccobacilli visualised on the modified acid-fast stain.

Discussion

Nocardiosis is an unusual opportunistic infection in HIV-infected patients¹. Despite extensive dissemination, it's very rare to recover it on blood cultures². *Nocardia asteroides* is the most commonly isolated species among 12 other species in *Nocardia* genus. Whilst concurrent pulmonary and CNS are the commonest forms of infection, bacteremia and osteomyelitis are rare occurrences². The Clinical and Laboratory Standards Institute (CLSI) recommends the microdilution method for susceptibility testing³.

Drug trial on treatment is non-existence. Based on cumulative retrospective experiences, most authorities recommend Co-trimoxazole as part of first-line therapy⁴ in combination with two other antibiotics in severe cases⁵.

REFERENCES

1. Beaman BL, Beaman L. *Nocardia* species: host-parasite relationships. Clin Microbiol Rev 1994; 7:213
2. Kontoyiannis DP, Ruoff K, Hooper DC. *Nocardia* bacteremia. Report of 4 cases and re-

view of the literature. *Medicine (Baltimore)* 1998; 77:255.

3. National Committee for Clinical Laboratory Standards. Susceptibility testing of mycobacteria, nocardiae, and other aerobic actinomycetes. Approved standard. NCCLS document M24-A, National Committee for Clinical Laboratory Standards, Wayne, PA 2003.
4. Wilson JP, Turner HR, Kirchner KA, Chapman SW. Nocardial infections in renal transplant recipients. *Medicine (Baltimore)* 1989; 68:38.
5. Brown-Elliott BA, Brown JM, Conville PS, Wallace RJ Jr. Clinical and laboratory features of the *Nocardia* spp. based on current molecular taxonomy. *Clin Microbiol Rev* 2006; 19:259.